



# VCU

Virginia Commonwealth University  
VCU Scholars Compass

---

Surgery Publications

Dept. of Surgery

---

1985

## Pathophysiology of Male Hypogonadism Associated with Endogenous Hyperestrogenism — Evidence for Dual Defects in the Gonadal Axis

Johannes D. Veldhuis  
*University of Virginia*

James R. Sower  
*National Institutes of Health*

Alan D. Rogol  
*University of Virginia*

*See next page for additional authors*

Follow this and additional works at: [http://scholarscompass.vcu.edu/surgery\\_pubs](http://scholarscompass.vcu.edu/surgery_pubs)

 Part of the [Surgery Commons](#)

From The New England Journal of Medicine, Veldhuis, J. D., Sowers, J. R., Rogol, A. D. et al., Pathophysiology of Male Hypogonadism Associated with Endogenous Hyperestrogenism — Evidence for Dual Defects in the Gonadal Axis, Vol. 312, Page 1371, Copyright © 1985 Massachusetts Medical Society. Reprinted with permission.

---

Downloaded from

[http://scholarscompass.vcu.edu/surgery\\_pubs/14](http://scholarscompass.vcu.edu/surgery_pubs/14)

This Article is brought to you for free and open access by the Dept. of Surgery at VCU Scholars Compass. It has been accepted for inclusion in Surgery Publications by an authorized administrator of VCU Scholars Compass. For more information, please contact [libcompass@vcu.edu](mailto:libcompass@vcu.edu).

---

**Authors**

Johannes D. Veldhuis, James R. Sower, Alan D. Rogol, Frederick A. Klein, Norman Miller, and Maria L. Dufau

## PATHOPHYSIOLOGY OF MALE HYPOGONADISM ASSOCIATED WITH ENDOGENOUS HYPERESTROGENISM

### Evidence for Dual Defects in the Gonadal Axis

JOHANNES D. VELDHUIS, M.D.,

JAMES R. SOWERS, M.D.,

ALAN D. ROGOI, M.D., PH.D.,

FREDERICK A. KLEIN, M.D., NORMAN MILLER, M.D.,

AND MARIA L. DUFAU, M.D., PH.D.

**F**EMINIZING tumors of the adrenal cortex are associated with symptoms that presumably reflect the combined effects of estrogen excess and androgen deficiency — gynecomastia, diminished libido, attenuated potency, and testicular and prostatic atrophy.<sup>1-5</sup> Although such tumors are extremely rare, they provide a unique opportunity to appraise the nature of endogenous estrogen action on the gonadal axis in men. In principle, the pathophysiologic effects of estrogen hypersecretion could be expressed at the level of either the Leydig cell or the hypothalamic-pituitary axis (or both), with consequent suppression of androgen production. In the present studies, we investigated the endocrine consequences of reversible endogenous estrogen excess in a patient with a surgically resectable feminizing adrenal cortical tumor.

### CASE REPORT

A 65-year-old black man was referred for evaluation of progressive bilateral gynecomastia, diminished libido, and impotence. There was no history of exposure to exogenous estrogen or androgen antagonists. Physical examination revealed symmetric gynecomastia (4 by 4 cm), a feminized body contour, and diminished testicular size (3.2 and 3.0 cm, long axes). The serum concentration of estradiol was 120 pg per milliliter (normal, 10 to 60; multiply by 3.68 to convert to picomoles per liter). The serum concentration of immunoreactive luteinizing hormone (LH) was 5.5 mIU per milliliter (normal, 2 to 20), and that of follicle-stimulating hormone was 1.6 mIU per milliliter (normal, 2 to 20). The total serum testosterone concentration was 27 ng per deciliter (normal, 260 to 1120; multiply by 0.0347 to convert to nanomoles per liter). Serum prolactin, thyroxine, resin triiodothyronine uptake, thyrotropin, and cortisol concentrations were normal. A computerized axial tomographic scan of the abdomen revealed a right adrenal mass, 5 by 4 cm.

After detailed preoperative endocrine testing (discussed below), the patient underwent right adrenalectomy, and an adrenal cortical adenoma, 5 by 7 cm, was removed without complications. Postoperatively, further endocrine evaluation was undertaken after two weeks, three months, and six months.

### ENDOCRINE EVALUATION

Serum concentrations of total and free testosterone, estradiol, estrone, delta-4-androstenedione, dehydroepiandrosterone sulfate, 17-hydroxyprogesterone, immunoreactive LH, immunoreactive follicle-stimulating hormone, and bioactive LH were assayed as previously

From the Department of Internal Medicine, University of Virginia School of Medicine, Charlottesville; the Veterans' Administration Medical Center, Richmond, Va.; the Departments of Pharmacology and Pediatrics, University of Virginia School of Medicine, Charlottesville; the Department of Surgery, Medical College of Virginia, Richmond; DePaul Hospital, Norfolk, Va.; and the Molecular Endocrinology Section, Endocrinology and Reproduction Research Branch, National Institutes of Child Health and Human Development, Bethesda, Md. Address reprint requests to Dr. Veldhuis at the University of Virginia School of Medicine, Box 202, Charlottesville, VA 22908.

described.<sup>6-8</sup> On three occasions, the patient underwent frequent venous sampling, in which blood was withdrawn at 20-minute intervals for 24 hours to assess pulsatile LH release, which was quantitated by a computer program described elsewhere.<sup>8</sup> In addition, blood was withdrawn at 20-minute intervals for 2 to 10 hours for the subsequent measurement of bioactive LH before and after surgery.

To test the responsiveness of Leydig cells, human chorionic gonadotropin was injected at a dose of 1500 IU intramuscularly at 8 a.m. Blood was withdrawn for the subsequent assay of serum estradiol, testosterone, and 17 $\alpha$ -hydroxyprogesterone at 8 a.m., 8:30 a.m., 9 a.m., 10 a.m., and 12 noon, and on the following day at 2 a.m., 5 a.m., 8 a.m., and 10 a.m. The human chorionic gonadotropin test was performed on two occasions separated by three weeks during the postoperative period (six months after surgery), under basal conditions and after administration of the antiestrogen tamoxifen, 20 mg twice daily orally for three days.

Data were analyzed with the paired t-test or analysis of variance, or when appropriate with the Mann-Whitney test.<sup>9</sup>

### RESULTS

Histopathological examination of the resected adrenal gland revealed a soft, tan, centrally located tumor, 4.8 cm in diameter, of homogeneous appearance. Microscopy of the tumor disclosed a diffuse proliferation of eosinophilic cells with lipophilic and somewhat granular cytoplasm and round to oval nuclei with occasionally prominent nucleoli. Mitoses were uncommon (two in 20 high-power fields). There was no evidence of capsular or vascular invasion, but in view of the occasional pleomorphism and loss of cellular cohesion, a moderately well-differentiated carcinoma was diagnosed. A crude membrane preparation of tumor cells previously frozen in liquid nitrogen revealed 8.61 fmol of bound human chorionic gonadotropin per milligram of protein.

Figure 1 shows the changes in serum concentrations of total and free testosterone, estradiol, estrone, and 17 $\alpha$ -hydroxyprogesterone in relation to surgical removal of the tumor. Before the operation, serum levels of estrogens and 17 $\alpha$ -hydroxyprogesterone were increased, whereas levels of total and free testosterone were markedly reduced. Within two weeks after the operation, serum estradiol, estrone, and 17 $\alpha$ -hydroxyprogesterone concentrations fell, and serum free and total testosterone concentrations rose into the normal range. Serum androstenedione concentrations also increased, from 33 ng per deciliter (normal range, 50 to 180) before the operation to 46 to 62 ng per deciliter afterward (multiply by 0.0314 to convert to nanomoles per liter).

The 24-hour mean concentration ( $\pm$ S.E.M.) of immunoreactive LH increased significantly, from a low-normal value of  $3.8 \pm 0.1$  mIU per milliliter preoperatively to  $7.4 \pm 0.2$  mIU per milliliter postoperatively ( $P < 0.01$ ; Table 1). There was a corresponding two-fold to threefold increase in integrated LH concentrations.

The pulsatile mode of LH release also changed significantly in relation to correction of the hyperestrogenism. As shown in Figure 2, mean immunoreactive LH concentrations and pulse amplitudes were markedly suppressed before surgery and rose significantly within two weeks afterward ( $P < 0.01$ ). LH pulse frequency was 0.25 pulse per hour preoperatively and

0.33 to 0.83 pulse per hour at two weeks to six months postoperatively (P not significant). Note that in view of the markedly reduced LH pulse amplitudes observed before surgery, the computer algorithm is more likely to underestimate absolute LH pulse frequency at this time.<sup>10</sup>

Changes in serum immunoactive LH concentrations were accompanied by even more prominent changes in circulating concentrations of biologically active LH. As shown in Figure 3, mean and integrated (area) bioactive LH concentrations were significantly suppressed before the operation (P<0.01 as compared with the level in normal men) but increased sevenfold to eightfold within two weeks afterward (P = 0.007).

The preoperative plasma bioactive:immunoactive LH ratio was abnormally reduced at 1.99±0.17 (mean ±S.E.M.), with a median value of 1.90 (P<0.01 as compared with value in normal men<sup>11</sup> with a mean

**Table 1. Immunoactive Luteinizing Hormone (LH) Pulse Characteristics in Blood Sampled Every 20 Minutes for 24 Hours in a Patient with a Surgically Removable Estrogen-Secreting Tumor.\***

TIME OF SAMPLING	LH CONCENTRATION		PULSE FREQUENCY	PULSE AMPLITUDE	
	MEAN	AREA		%	mIU/ml
	mIU/ml	mIU/ml · min †	pulses/hr	%	mIU/ml
Before operation	3.8±0.1	222	0.25	51±16	1.2±0.2
After operation					
At 2 wk	13.1±0.3 ‡	779	0.33	61±6	7.0±0.5 ‡
At 3 mo	7.4±0.2 ‡	441	0.33	89±29	4.1±0.5 ‡
At 6 mo	11.8±0.7 ‡	702	0.83	116±25	9.2±2.2 ‡
Normal values in men (n = 36)	6.90±0.71	411±38	0.42±0.03	92±6.1	5.2±0.40

\*Plus-minus values are means ±S.E.M.

†For each hour of sampling.

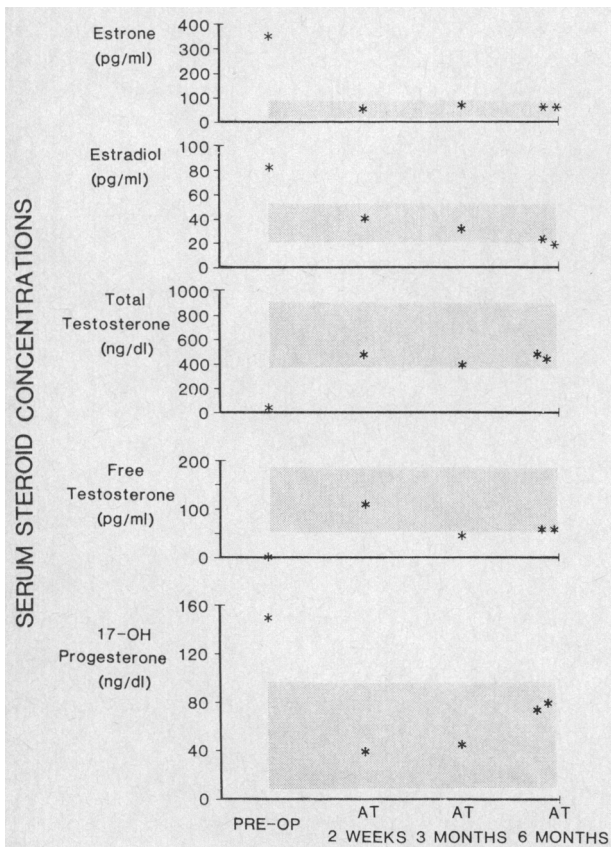
‡P<0.01 as compared with corresponding preoperative value.

bioactive:immunoactive ratio of 3.95). Within two weeks of surgical removal of the feminizing tumor, the bioactive:immunoactive ratio rose to 5.12±0.49, with a median value of 5.0 (P<0.01 as compared with the value before surgery). The ratio then continued to increase, to 11.0±0.77 (median, 11.1) at six months — higher than the mean ratio in postmenopausal women<sup>11</sup> (5.4).

In view of the low-normal postoperative serum free testosterone concentrations and concomitantly increased blood concentrations of biologically active LH, a partial Leydig-cell defect in steroidogenesis or Leydig-cell atrophy (or both) was suspected. Leydig-cell atrophy was suggested when human chorionic gonadotropin was administered, since both serum testosterone and 17α-hydroxyprogesterone concentrations rose subnormally (Table 2). When stimulation with human chorionic gonadotropin was repeated after administration of the antiestrogen tamoxifen, this pattern did not change significantly, although serum concentrations of testosterone, estradiol, and 17α-hydroxyprogesterone all declined. These decreases were associated with a significant decline in mean plasma concentrations of bioactive LH (Fig. 4), suggesting that tamoxifen acted as a partial estrogen agonist in this patient. Since the pituitary gland responded to gonadotropin-releasing hormone (100 μg intravenously) with a marked release of both immunoactive and bioactive LH, we infer that tamoxifen did not directly suppress the responses of the pituitary gland but acted predominantly at the hypothalamic level.

**DISCUSSION**

Feminizing adrenal tumors are typically associated with a constellation of clinical features that are presumably attributable to combined androgen deficiency and relative or absolute estrogen excess.<sup>1-5</sup> The exact cause of androgen deficiency in this setting of hyperestrogenism is not known. However, the pathophysiologic effects of estrogen hypersecretion could be expressed at several levels of the gonadal axis.



**Figure 1. Steroid Hormone Concentrations before and after Operation in a Patient with a Surgically Removable Feminizing Adrenal Tumor.**

The shaded areas indicate normal ranges, and 17-OH denotes 17α-hydroxyprogesterone. To convert estrogen concentrations to picomoles per liter, multiply by 3.70. Other conversion factors are given in the legend of Table 2.

Estrogen-Secreting Adrenal Tumor

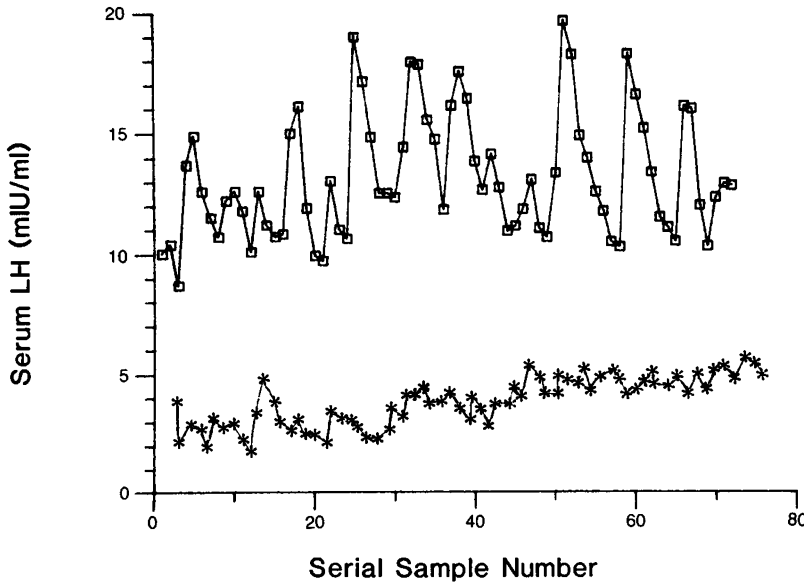


Figure 2. Pulsatile Release of Immunoactive Luteinizing Hormone (LH) before Surgery (\*) and Two Weeks after Surgery (□).

Serum LH was measured by immunoassay in blood samples drawn at 20-minute intervals for 24 consecutive hours. Note the increased concentrations and amplitudes of LH pulses observed two weeks after removal of the estrogen-secreting adrenal tumor.

For example, the infusion of small quantities of estrogen in normal men effectively inhibits the physiologically pulsatile mode of immunoreactive gonadotropin secretion,<sup>8</sup> whereas antiestrogens typically stimulate the release of immunoreactive LH.<sup>14</sup> Although corresponding changes in concentrations of bioactive LH have not been reported under these circumstances, the present case of surgically remediable hyperestrogenism permitted us to test the influence of a sustained endogenous estrogen excess on the secretion of bioactive LH. In particular, the predominant production of estrone in this patient, with a less marked increase in estradiol, resulted in less than total suppression of LH concentrations and therefore permitted us to test the nature of estrogen's suppressive actions on the male gonadal axis.

Before operation the increased serum concentrations of estradiol and estrone were associated with a significant but reversible suppression of circulating levels of bioactive LH. Moreover, the degree of suppression of bioactive LH was greater than that for immunoactive LH, with a consequent decrease in the bioactive:immunoactive ratio to approximately 50 per cent of that observed in normal men. This low ratio presumably resulted from a combination of factors, such as increased serum estrogen concentrations and reduced serum androgen concentrations. This pattern resembles that observed in women with normal menstrual cycles.<sup>11,15</sup> However, within two weeks of surgical removal of the feminizing adrenal tumor, plasma bioactive LH levels increased threefold, with a lesser increase in immunoactive LH concentrations, which resulted in a twofold to fivefold amplification of the bioactive:immunoactive LH ratio. Thus, we infer that endogenous hyperestrogenism is associated with marked suppression of mean circulating plasma concentrations of biologically active LH. This secondary hypogonadotropism may contribute to the severe androgen deficiency that develops under these circumstances.

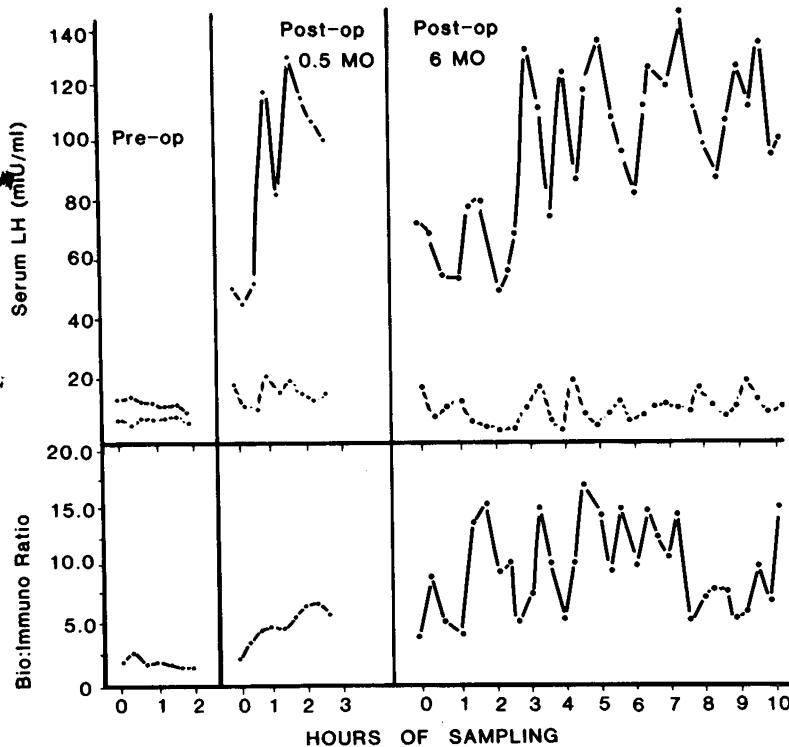


Figure 3. Changes in Plasma Concentrations of Biologically Active Luteinizing Hormone (LH) (Upper Curves), Immunoactive LH (Middle Curves), and the Corresponding Bioactive:Immunoactive LH Ratios (Bottom Curves) in Blood Sampled Every 20 Minutes before Surgery (Left Panel), Two Weeks after Surgery (Middle Panel), and Six Months after Surgery (Right Panel).

Note the sharp rise in serum concentrations of bioactive LH and the corresponding increase in the bioactive:immunoactive LH ratio in plasma that occurred after surgery.

**Table 2. Results of the Human Chorionic Gonadotropin Stimulation Test.\***

HORMONE	BEFORE TAMOXIFEN		AFTER TAMOXIFEN	
	T = 0	T = 24 HR	T = 0	T = 24 HR
Testosterone (ng/dl) †	691	<u>833</u>	527	622
17-OH progesterone (ng/dl) ‡	121	<u>133</u>	78	138
T/17-OH P §	17.5	<u>16.0</u>	14.7	22.2
Estradiol (pg/ml) ¶	38.7	<u>90.6</u>	26	45

\*The subnormal responses are underscored.

†Testosterone concentrations increased by 1.21-fold and 1.18-fold in response to treatment with human chorionic gonadotropin (hCG) (1500 IU intramuscularly), before and after tamoxifen pretreatment, respectively (normal increases,  $2.1 \pm 0.2$ -fold and  $1.2 \pm 0.2$ -fold, respectively<sup>12</sup>). Multiply by 0.0347 to convert to nanomoles per liter.

‡Concentrations of 17 $\alpha$ -hydroxyprogesterone (17-OH progesterone) increased by 1.1-fold and 1.8-fold in response to hCG, before and after tamoxifen, respectively (normal increases,  $2.5 \pm 0.2$ -fold and  $1.3 \pm 0.3$ -fold, respectively). Multiply by 0.0303 to convert to nanomoles per liter.

§The ratio of testosterone to 17 $\alpha$ -hydroxyprogesterone (T/17-OH P) increased by 0.91-fold and 1.5-fold after hCG, before and after tamoxifen, respectively (normal increases,  $1.7 \pm 0.3$ -fold and  $1.1 \pm 0.1$ -fold, respectively).

¶Serum estradiol concentrations increased by 2.34-fold in response to hCG before tamoxifen (normal,  $4.4 \pm 0.6$ -fold<sup>13</sup>). Multiply by 3.68 to convert to picomoles per liter.

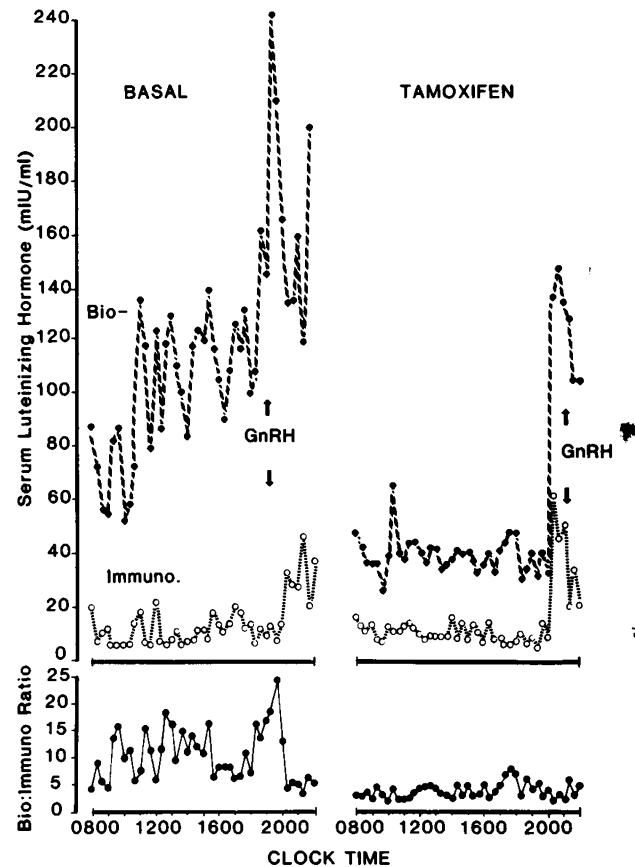
The decreased serum LH concentrations observed before surgery were accompanied by a significant decrease in the amplitude of spontaneous LH pulsations. This is in accord with the ability of exogenously infused estrogen to dampen the amplitude of immunoreactive LH pulsations.<sup>8,16</sup> Thus, our results suggest that one important locus of the suppressive action of pathologic estrogen hypersecretion is the amplitude component of pulsatile LH release.

The reduced LH secretion before surgery was associated with decreased serum testosterone and delta-4-androstenedione concentrations but relatively increased serum 17 $\alpha$ -hydroxyprogesterone concentrations. This distinctive steroidal pattern represented a 128-fold higher ratio of 17 $\alpha$ -hydroxyprogesterone to testosterone preoperatively as compared with postoperatively. A similar steroidal profile has been observed in animals with acquired Leydig-cell defects at the level of 17 $\alpha$ -hydroxylase/C<sub>17-20</sub> desmolase. Such defects typically occur after exposure to high doses of human chorionic gonadotropin<sup>17</sup> or estradiol.<sup>18</sup> Since human chorionic gonadotropin was undetectable and plasma concentrations of bioactive LH were reduced, it is possible that the endogenous estrogen excess itself contributed to a reversible steroidogenic lesion in this patient.

There was no evidence of a steroidogenic defect in the testes after surgery, nor could such a defect be unmasked by stimulation with human chorionic gonadotropin. Moreover, the steroidal response to chorionic gonadotropin was not significantly influenced by prior administration of the antiestrogen tamoxifen, which would be expected to attenuate the inhibitory effects of estrogen.<sup>18,19</sup> Rather, an extreme postoperative sensitivity of the patient's hypothalamic-pituitary axis to estrogen was suggested by the partial estrogen-agonist effect exerted by tamoxifen, which

significantly suppressed the spontaneous release of bioactive and immunoreactive LH. Although tamoxifen is an effective estrogen antagonist and augments the release of immunoreactive LH in normal men,<sup>20</sup> similar estrogen-like responses to antiestrogens have been described in prepubertal children and menopausal women.<sup>16,21</sup> Both these conditions are characterized by a relative or absolute estrogen deficiency, akin to the steroidal milieu of this patient after tumor removal. Since the pituitary response to exogenous gonadotropin-releasing hormone was preserved, we infer that the inhibitory effect of tamoxifen was expressed predominantly at the hypothalamic level in this patient.

A continued decrease in Leydig-cell reserve after removal of the tumor was indicated by the high concentrations of bioactive LH that were required to maintain low-normal plasma free testosterone concentrations and by the limited response of the testes



**Figure 4. Influence of the Antiestrogen Tamoxifen on Circulating Concentrations of Bioactive and Immunoreactive Luteinizing Hormone (LH) after Surgery.**

The patient underwent blood sampling at 20-minute intervals for 14 hours, with subsequent radioimmunoassay (Immuno.) or bioassay (Bio-) of LH (upper curves) to characterize pulsatile hormone release, both in the basal state (left panel) and after administration of tamoxifen for three days (right panel). Gonadotropin-releasing hormone (GnRH, 100  $\mu$ g intravenously) was administered at the designated times to test pituitary responsiveness. In the bottom curve, the serial bioactive:immunoreactive ratios for LH are plotted.

to administration of human chorionic gonadotropin. Such a decrease in Leydig-cell reserve may reflect a decrease in Leydig-cell mass, which has been suggested histopathologically in some patients with feminizing tumors.<sup>22</sup> Although the exact endocrine basis for presumptive Leydig-cell failure in this setting is not known, it could be attributable to cachexia, toxic effects of hyperestrogenism, or possibly the sustained and exaggerated increase in gonadotropin secretion observed postoperatively. That the preoperative suppression of LH secretion induced Leydig-cell failure seems unlikely, since other studies have demonstrated recovery of testicular function even after longstanding LH deficiency.<sup>23</sup>

The basis for the small but measurable quantity of specific binding of human chorionic gonadotropin in this patient's adrenal tumor is not known. However, we speculate that it may have reflected tumor-associated derepression of the genome coding for chorionic gonadotropin receptors, the presence of gonadal cell rests in the adrenal gland, or the influence of locally produced estrogenic steroids on receptor expression.

In summary, severe but reversible male hypogonadism associated with endogenous hyperestrogenism can be attributable to profound suppression of circulating concentrations of biologically active LH, with an associated steroidal pattern that mimics that of estrogen-induced steroidogenic lesions in the Leydig cells of laboratory animals. Thus, we suggest that a sustained estrogen excess could induce hypogonadism in men by imposing dual lesions on the gonadal axis — by suppressing the secretion of biologically active LH and by adversely affecting Leydig-cell function.

We are indebted to Chris McNett for her skillful preparation of the manuscript, to Paula P. Veldhuis for the artwork, to the National Hormone and Pituitary Program for the provision of purified human LH, to Elizabeth Taylor and Rebecca Weaver for technical support, to Sandra Jackson and the expert nursing staff at the Clinical Research Center at the University of Virginia, and to Richard J. Santen for generously providing his original computer program.

## REFERENCES

1. Mathias E. Über geschwulste der Nebennierenrinde mit morphogenetischen Wirkungen. *Arch Pathol Anat* 1922; 236:446-69.
2. Armstrong CN, Simpson J. Adrenal feminism due to carcinoma of adrenal cortex: a case report and review of the literature. *Br Med J* 1948; 1:782-4.
3. Case Records of the Massachusetts General Hospital (Case 41121). *N Engl J Med* 1955; 252:496-501.
4. Stewart WK, Fleming LW, Wotiz HH. The feminizing syndrome in male subjects with adrenocortical neoplasms. *Am J Med* 1964; 37:455-72.
5. Gabrilove JL, Sharma DC, Wotiz HH, Dorfman RI. Feminizing adrenocortical tumors in the male: a review of 52 cases. *Medicine* 1965; 44: 37-79.
6. Samojlik E, Veldhuis JD, Wells SA, Santen RJ. Preservation of androgen secretion during estrogen suppression with aminoglutethimide in the treatment of metastatic breast carcinoma. *J Clin Invest* 1980; 65:602-12.
7. Veldhuis JD, Rogol AD, Johnson ML, Dufau M. Endogenous opiates modulate the pulsatile secretion of biologically active luteinizing hormone in man. *J Clin Invest* 1983; 72:2031-40.
8. Veldhuis JD, Rogol AD, Samojlik E, Ertel NH. Role of endogenous opiates in the expression of negative feedback actions of androgen and estrogen on pulsatile properties of luteinizing hormone secretions in man. *J Clin Invest* 1984; 74:47-55.
9. Ryan AT, Joiner BL, Ryan BF, eds. Descriptive statistics. In: *Minitab: student handbook*. Boston: Duxbury Press, 1976:26-266.
10. Veldhuis JD, Evans WS, Rogol AD, et al. Intensified rates of venous sampling unmask the presence of spontaneous high-frequency pulsations of luteinizing hormone in man. *J Clin Endocrinol Metab* 1984; 59:96-102.
11. Dufau ML, Veldhuis JD, Fraioli F, Johnson ML, Beitins IZ. Mode of secretion of bioactive luteinizing hormone in man. *J Clin Endocrinol Metab* 1983; 57:993-1000.
12. Smals AGH, Pieters GFFM, Drayer JIM, Boers GHJ, Benraad TJ, Kloppenborg PWC. Tamoxifen suppresses gonadotropin-induced 17 $\alpha$ -hydroxyprogesterone accumulation in normal men. *J Clin Endocrinol Metab* 1980; 51:1026-9.
13. Smals AGH, Pieters GFFM, Boers GHJ, et al. Differential effect of single high dose and divided small dose administration of human chorionic gonadotropin on Leydig cell steroidogenic desensitization. *J Clin Endocrinol Metab* 1984; 58:327-31.
14. Santen RJ, Ruby EB. Enhanced frequency and magnitude of episodic luteinizing hormone-releasing hormone discharge as a hypothalamic mechanism for increased luteinizing hormone secretion. *J Clin Endocrinol Metab* 1979; 48:315-9.
15. Veldhuis JD, Beitins IZ, Johnson ML, Serabian MA, Dufau ML. Biologically active luteinizing hormone is secreted in episodic pulsations that vary in relation to stage of the menstrual cycle. *J Clin Endocrinol Metab* 1984; 58:1050-8.
16. Santen RJ. Independent control of luteinizing hormone secretion by testosterone and estradiol in males. In: Fotherby K, Pal SB, eds. *Hormones in normal and abnormal tissues*. New York: Walter de Gruyter, 1981:459-89.
17. Nozu K, Matsuura S, Catt KJ, Durau ML. Modulation of Leydig cell androgen biosynthesis and cytochrome P-450 levels during androgen treatment and human chorionic gonadotropin-induced desensitization. *J Biol Chem* 1981; 256:10012-7.
18. Nozu K, Dufau ML, Catt KJ. Estradiol receptor-mediated regulation of steroidogenesis in gonadotropin-desensitized Leydig cells. *J Biol Chem* 1981; 256:1915-22.
19. Cigorraga SB, Sorrel S, Bator J, Catt KJ, Dufau ML. Estrogen dependence of a gonadotropin-induced steroidogenic lesion in rat testicular Leydig cells. *J Clin Invest* 1980; 65:699-705.
20. D'Agata R, Vicari E, Aliffi A, Gulizia S, Palumbo G. Direct evidence in men for a role of endogenous oestrogens on gonadotropin release. *Acta Endocrinol* 1981; 97:145-9.
21. Czygan P-J, Schulz KD. Studies on the anti-oestrogenic and oestrogen-like action of clomiphene citrate in women. *Gynecol Invest* 1972; 3:126-34.
22. Sohval AR, Gabrilove JL. Testicular histopathology in feminizing tumors of the adrenal cortex. *J Urol* 1965; 93:711-6.
23. Santen RJ, Paulsen CA. Hypogonadotropic eunuchoidism. II. Gonadal responsiveness to exogenous gonadotropins. *J Clin Endocrinol Metab* 1973; 36:55-63.