

the physician of the risk of airway obstruction in the prone position and of feeding difficulties in early infancy. Knowledge of cervical spine anomalies in chondrodystrophy alerts the neurologist to central nervous system signs or symptoms that may result from basilar brain compression.

A second benefit of syndrome identification is that a better prognosis regarding such important factors as longevity, morbidity, and ultimate adult height and mentality may be made. The dysmorphic infant with Saethre-Chotzen syndrome is not at substantial risk for mental retardation. Recognition of the earlier signs and dominant nature of the familial form of amyotrophic lateral sclerosis enables better counseling regarding longevity and morbidity.

Knowledge of the mode of inheritance provides risk figures for recurrence so that family planning can be practiced. It is not sufficient to state that the patient with a dominant condition has a 50% risk that each offspring will inherit the disorder; as demonstrated in the families with Pierre Robin anomalad and Saethre-Chotzen syndrome, some persons have

minimal manifestations, thus reducing the significance of the existence of the condition. In the case of sex-linked diseases, as in the family with chondrodystrophy, identification of female carriers can establish a 50% risk that male offspring will inherit the disorder. Further studies in the family with ring 9 chromosome abnormality should establish whether the proband, her mother, or other family members are at risk for bearing anomalous offspring.

Often patients seen in our clinic have been evaluated elsewhere for one or more components (for example, short stature, dysmorphic features, mental retardation, congenital malformations) of their disorder, but a precise diagnosis has not been made. Identifying the syndrome provides a diagnosis and permits a proper focusing on the disease process. While evaluation is often time-consuming, the reward is a family gratified by the establishment of a diagnosis that will allow a better understanding of the condition.

PETER MAMUNES, M.D.

*Professor of Pediatrics and of Human Genetics*

## A Report of Familial Ring (9) Chromosome

ROBIN J. CALDWELL, *Graduate Assistant, Department of Human Genetics*

JUDITH A. BROWN, Ph.D., *Director of Cytogenetics, Department of Human Genetics*

REUBEN B. YOUNG, M.D., *Executive Associate Dean, Director of Medical Staff Services, Professor of Pediatrics and Human Genetics*

Ring chromosomes originate in the simultaneous occurrence of two breaks at opposite ends of the

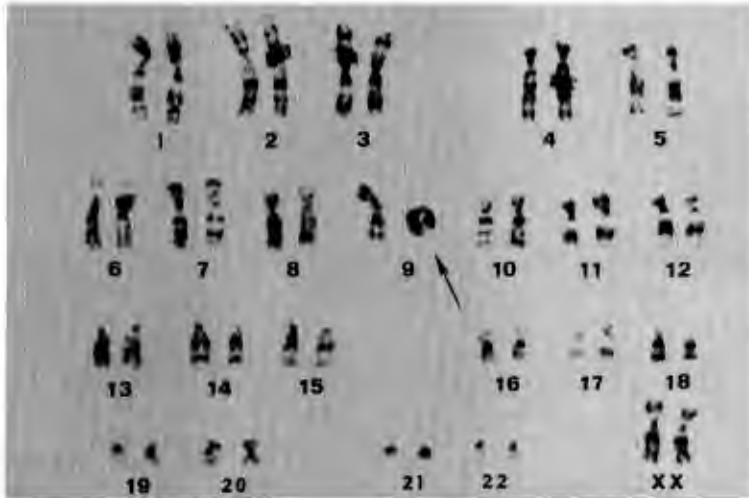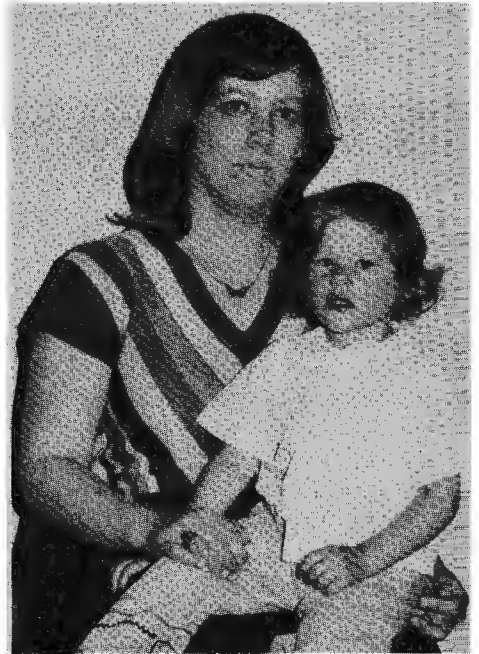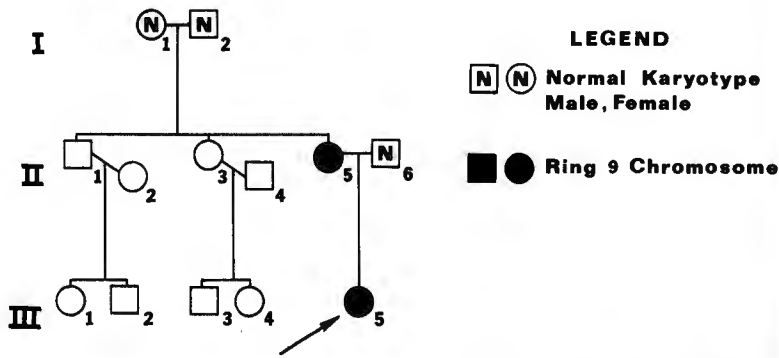
---

This is paper #37 from the Department of Human Genetics of the Medical College of Virginia and was supported in part by a Developmental Disabilities Grant from the Department of Mental Health and Mental Retardation of the Commonwealth of Virginia.

Correspondence and reprint requests to Robin J. Caldwell, Box 33, Medical College of Virginia, Richmond, Virginia 23298.

chromosome and the subsequent reuniting of the free ends to form a ring. They may be compatible with normal life, as only a fractional loss of genetic material has occurred, or they may lead to spontaneous abortion or to an offspring with severe physical and mental handicap attributable to significant genetic alterations.

The dearth of published case reports underscores



Figure—(Top left) Pedigree of the proband. (Bottom left) Proband's karyotype, showing the ring chromosome (9) (arrow). (Top right) Photograph of proband and mother. (Bottom right) Partial karyotype of proband's mother, showing the familial ring (9) (Chromosome magnification,  $\times 4000$ ).

the rarity of familial ring chromosomes. De novo ring chromosomes have been described in all chromosome groups in man,<sup>1</sup> but familial transmission of rings has been limited to chromosome 17,<sup>2</sup> chromosome 18,<sup>3</sup> chromosome 21, Palmer et al<sup>4</sup> and by E. Engel, MD (oral communication, May 1977), and a G-group chromosome not identified by banding analysis.<sup>5</sup>

Since the formation of a ring chromosome results in the loss of genes, it is not surprising that the phenotype of the individual possessing the ring can resemble the phenotype resulting from isolated short or long arm deletions, a combination of both, or duplications of the short or long arm due to recombination during meiosis.

### Case Reports

*Case 1 [Figure (top left, III,5) and (top right)]:* P.S. was the product of a 28-week gestation of a 24-year-old para 1, gravida 1, abortion O mother who developed severe tox-

emia accompanied by a sudden decrease in estriol level. Because of fetal distress, a Caesarian section was performed, and a 1,360 gm female was delivered on May 1, 1974. The baby sat alone at eight months, walked at 18 months, and had a vocabulary of three to four words at 18 months. In September 1975, she was referred by a pediatrician to the Medical College of Virginia for evaluation of her failure to thrive. Her length was 28 cm, weight 6,914 gm, and head circumference 39 cm (all below the third percentile); she showed slight bilateral epicanthal folds and normal ears. Other tests revealed a bone age of 12 months, normal skull films, 10/10 arches on dermatoglyphic analysis, normal intravenous pyelogram, normal sweat chloride, and a normal Denver Development Test.

The patient was reexamined in the Genetics Counseling Clinic on March 10, 1976. At that time her developmental age on the Denver Development Test was 14 months (8 months under chronological age), her vocabulary still contained only four words, and she still was not toilet-trained. Examination revealed an alert, active female child with microcephaly, proportionate small size, large but not simple or low-set ears, pointed teeth, prominent nose, wide down-

turned mouth, slight epicanthal folds, and no congenital heart defects. Her skull bones were fused.

The patient returned to the Genetics Counseling Clinic at MCV on April 15, 1977, when she weighed 9,525 gm, with a height of 85 cm. Her vocabulary had increased to about 12 words and one three-word sentence. Thyroid studies showed  $T_3$ ,  $T_4$ , and serum-free thyroxin to be within normal limits.

*Case 2 [Figure (top left, II,5) and (top right)]:* C.S. is a 27-year-old female and the mother of Case 1. Her medical history includes an appendectomy at age 12 years, a kidney infection at 16 years, and scarlet fever at 17 years. Following the birth of her first child, she elected to have a tubal ligation. On examination in April 1977, she appeared to be of average intelligence, had been graduated from high school, and was working as a processor at an electrical equipment plant. She was 149.87 cm tall and weighed 58.9 kg. Dermatoglyphics were normal.

#### CYTOGENETIC STUDIES

*Case 1:* Peripheral blood lymphocytes were cultured in vitro using a slight modification of the method used by Moorhead et al.<sup>6</sup> Metaphase chromosomes were stained with the trypsin-Giemsa chromosome banding technique of Seabright.<sup>7</sup> Twenty randomly selected metaphases were counted, and a modal number of 46 chromosomes was established. Five cells were photographed and karyotyped and a large ring chromosome identified as chromosome 9 was present in all cells. Chromosome-banding analyses established the breakpoints at region 2, band 4 in the short arm (p24) and region 3, band 4 (q34) in the long arm, indicating that the two breaks were near the terminus of the short and long arms, 46,XX,r(9)(p24;q34).<sup>8</sup> A representative karyotype is shown (Figure, bottom left).

*Case 2:* At her own request, cytogenetic studies were done on the mother of the proband (II,5), the maternal grandparents (I, 1 and 2), and the proband's father (II,6). Normal karyotypes were documented for the maternal grandparents and the proband's father; however, a ring chromosome (9) was found in all cells scored from duplicate peripheral blood cultures from the proband's mother. Chromosome banding analysis revealed her karyotype to be 46,XX,r(9)(p24;q34). A partial karyotype is shown (Figure, bottom right).

#### Discussion

Two aspects of these cases are of particular interest to the clinical geneticist and cytogeneticist. The first is the de novo origin of a ring chromosome in a mother with few, if any, phenotypic abnormalities; and second, the transmission of what appears, cytogenetically, to be the same ring chromosome—structurally unaltered—to her daughter whose major physical defects are short stature and microcephaly associated with mental retardation. One could argue that the ring chromosome is responsible for the phenotype of the affected daughter, or that the ring (9) in

the daughter and the associated phenotype are unrelated because the mother possesses the same ring.

Ring chromosomes present the clinical geneticist with a challenging counseling problem because many aspects of their behavior during meiosis remain obscure. The way in which the ring chromosome participates in genetic recombination during meiosis, the occurrence or not of sister chromatid exchanges within the ring, and the subsequent genetic constitution of the ring will all determine whether a balanced or unbalanced gamete results. Although chromosome banding analysis allows the definitive identification of the involved chromosome and the accurate determination of the points of breakage, genic determinations await the refinement of the human gene map.

It is possible that there is a tissue distribution difference of the ring (9) in the mother and daughter. Although only peripheral blood has been examined to date and no evidence of chromosome mosaicism documented, tissue mosaicism cannot be ruled out.

We are aware of two other patients possessing a de novo ring (9) with break points identical to those in our family, (p24;q34), reported by Fraisse et al,<sup>9</sup> and by Y. Nakagome, MD et al (written communication, March 1976). There are many similarities between our patient and Nakagome's patient: proportionate short stature, prominent nose, microcephaly, mental and motor retardation, and poor speech development. The dermatoglyphic findings in our patient are of interest in that the finger pattern showed 10/10 arches, similar to the case report of Fraisse et al,<sup>9</sup> but in contrast to Nakagome's patient in whom there was a high palmar triradius only.

It is not possible to make definitive phenotype-karyotype correlations based on three clinical cases, but the following observation can be considered. In our family, the proband's phenotype could result from genic alterations associated with the ring chromosome and the normal phenotype of the proband's mother from a yet-to-be identified tissue mosaicism, or the contrasting phenotypes could be the result of the hemizygous expression of paternal recessive alleles. It is also possible that only minor genetic changes occurred at the time of de novo ring formation which the mother inherited. Finally, the potential influence of ascertainment biases in a family of this type must always be considered. If, for whatever reason, the ring chromosome is consistent with phenotypes ranging from normal to severely affected, one would be much more likely to observe severely affected sporadic cases and mildly affected parents of

familial cases than to find severely affected parents with normal children.

#### REFERENCES

1. KISTENMACHER ML, PUNNETT HH: Comparative behavior of ring chromosomes. *Am J Hum Genet* 22:304-318, 1970.
2. BURDEN M, LUPASCU E, MARGINEANU L: A familial case of 17R ring shaped chromosome of group E with transmission from father to son. *Revista Medico-Chirurgicală a Societății de Medici și Naturaliști din Iași* 77:353-357, 1973.
3. CHRISTENSEN KR, FRIEDRICH U, JACOBSEN P, ET AL: Ring chromosome 18 in mother and daughter. *J Ment Defic Res* 14:49-67, 1970.
4. PALMER CG, HODES ME, REED T, ET AL: Four new cases of ring 21 and 22 including familial transmission of ring 21. *J Med Genet* 14:54-60, 1977.
5. ZDANSKY R, BUHLER EM, VEST M, ET AL: Familiäres Mosaik mit G-ring. *Humangenetik* 7:275-286, 1969.
6. MOORHEAD PS, NOWELL PC, MELLMAN WJ, ET AL: Chromosome preparations of leukocytes cultured from human peripheral blood. *Expl Cell Res* 20:613-616, 1960.
7. SEABRIGHT M: A rapid banding technique for human chromosomes. *Lancet* 2:971-972, 1971.
8. BERGSMA D (exec ed): *Birth Defects: Original Article Series. Number 7: Paris Conference (1971): Standardization in Human Cytogenetics*, vol 8. New York, The National Foundation-March of Dimes, 1972.
9. FRAISSE J, LAURAS B, OOGHE MJ, ET AL: A propos d'un cas de chromosome 9 en anneau. Identification par dénaturation ménagée. *Ann Génét* 17:175-180, 1974.

## Dominantly Inherited Amyotrophic Lateral Sclerosis (Motor Neuron Disease)

LOUISE E. WILKINS, *Graduate Assistant, Department of Human Genetics*

ROBIN M. WINTER, M.B., M.R.C.P., *Postdoctoral Fellow, Department of Human Genetics*

EDWIN C. MYER, M.D., *Assistant Professor, Department of Pediatric Neurology*

WALTER E. NANCE, M.D., Ph.D., *Professor, Department of Human Genetics, Pediatrics and Medicine*

The term amyotrophic lateral sclerosis (ALS) was first introduced by Charcot to describe cases with mixed upper and lower motor neuron signs without

sensory impairment.<sup>1</sup> Later, the syndromes of progressive bulbar palsy (PBP) and progressive muscular atrophy (PMA) were recognized to be variations of the same pathological process, and ALS was used as an inclusive term to refer to these syndromes as well. Although some authors reserve the term ALS for the specific syndrome of mixed upper and lower motor neuron lesions and use the term "motor neuron disease" to refer to the constellation of syndromes, most

---

This is paper #46 from the Department of Human Genetics of the Medical College of Virginia and was supported in part by Grant #C-187 from the National Foundation-March of Dimes.

Correspondence and reprint requests to Louise E. Wilkins, Box 33, Medical College of Virginia, Richmond, Virginia 23298.