

A New Familial Chondrodystrophy Simulating Parastremmatic Dwarfism

WENDY L. GOLDEN, *Graduate Assistant, Department of Human Genetics*
PETER MAMUNES, M.D., *Professor of Pediatrics and of Human Genetics*
MICHAEL B. KODROFF, M.D., *Assistant Professor of Radiology*

Recent developments in tissue culture and enzyme analysis have made it possible to classify more precisely some of the skeletal dysplasias and to understand their pathophysiology; thus almost all seven clinical types of mucopolysaccharidoses are due to separate single enzyme deficiencies—one type, the Sanfilippo syndrome, has three subtypes, each with a different enzyme deficiency.¹ The majority of the skeletal dysplasias have no definable biochemical abnormality and are classified on the basis of clinical and radiological findings and the mode of inheritance. The purpose of this report is to present a family with an apparently new type of chondrodystrophy.

Case Report

Proband: An 18-year-old male with a diagnosis of Morquio disease was brought to the Medical College of Virginia Genetic Counseling Clinic by his mother and sister. He was the product of a normal, uncomplicated pregnancy, labor, and delivery, and at birth was considered normal. At age 3 to 4 months his mother states that he appeared to be behind in his development, although he was said to have had a three-word vocabulary at 5 months and at 10 months could put three words together in a sentence. He was evaluated at 2½ years and found to have mild kyphosis of the dorsolumbar region, moderate genu valgus, and slight restriction of internal and external rotation, and extension, of both hips; the sternum was noted to be particularly prominent. Radiographic examination showed slight diffuse changes of chondrodystrophy throughout, with the changes in the spine appearing more marked (Figure, *b, f*). He was unsuccessfully fitted with braces in an effort to make him ambulatory.

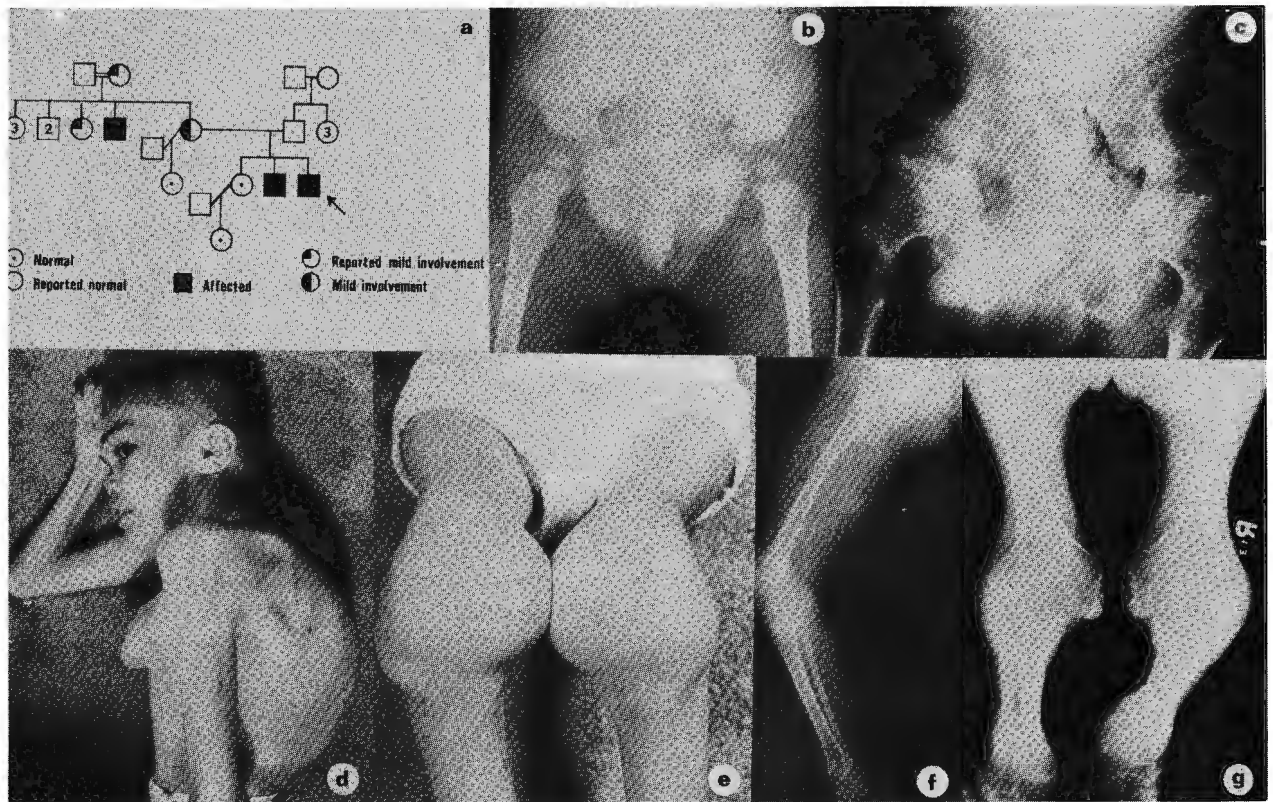
The skeletal changes progressed and when first seen at the MCV Clinic in 1976, the patient was markedly dwarfed (length 36½ inches), with coarse facies showing hypertelorism, a flat, wide nasal bridge, anteverted nostrils, a lack of cartilage in the nose and ears, heavy eyebrows, strabismus, and searching nystagmus. There was no corneal clouding. There were marked contractures of the limbs with limited movement in all directions of the knees and hips. The wrists were thickened but otherwise normal. The fingers were hyperextensible and the metacarpal joints appeared enlarged. Extension of the left elbow was nearly normal, while the right elbow had a 20 degree limitation of extension. All of the joints appeared knobby and enlarged, accentuated by the thinness of the extremities (Figure, *e*). There was severe kyphosis with mild thoracolumbar scoliosis and the sternum protruded anteriorly to a very marked degree (Figure, *d*). Also noted were signs of trunk and upper-extremity ataxia. While in the hospital he showed marked difficulty in breathing, with wheezing and congestion. There was no hepatosplenomegaly nor an abnormality of the palate.

There appeared to be moderate psychomotor retardation with disproportionate speech impairment, but mentation was difficult to assess due to the difficulty in speech and the lack of formal education.

The skeletal survey revealed marked kyphoscoliosis of the entire spine with a universal platyspondylia without anterior beaking of the vertebral body. The end plates were markedly irregular with lacelike ossifications. No evidence of rhizomelia could be demonstrated. There were marked changes about the knees with flaring of the metaphyses and marked irregularities of the ossification centers, both metaphyseal and epiphyseal, with the same lacelike ossification seen in the spine (Figure, *g*). Films of the pelvis revealed shortening of the ilium bilaterally, with the same irregular lacelike ossification bordering the iliac bones and around the joint spaces (Figure, *c*). Marked deformities were present in the feet. All of the actively growing centers showed the same type of changes as the knees. There was no significant bowing of the long bones. The skull showed a marked thickening of the calvarium, both over the convexities of the

This work was supported in part by Grant #9306-5124 from The National Foundation-March of Dimes.

Correspondence and reprint requests to Wendy Golden, Box 33, Medical College of Virginia, Richmond, Virginia 23298.



Figure—(a) Pedigree of family. (b,c) Pelvic x-rays of proband showing dramatic changes from 2½ to 18 years, with development of a lacelike ossification pattern. (d,e) Clinical appearance of proband at 18 years. (f,g) X-rays of knees at 2½ and 18 years. Note the development of marked flaring of epiphyses and metaphyses and lacelike ossification.

skull and at the base. A midline tomogram revealed the presence of basilar impression. These findings were felt to be inconsistent with a diagnosis of Morquio disease or any other spondylometaphyseal dysplasia.

Blood studies on the proband showed no unusual findings except for mild borderline anemia and an increase in platelets. An SMA 6 was within normal limits. SMA 12 was normal except for an increase in alkaline phosphatase. Urinalysis was within normal limits. An electrocardiogram showed a generalized grade I dysrhythmia, but the study was reported to be a technically difficult recording due to movement. Hearing sensitivity was within normal limits, with a bilateral 20-decibel hearing loss. A pulmonary lab report noted the presence of severe hypoxemia and moderate metabolic acidosis which was uncompensated.

An enzyme analysis of skin fibroblasts, (courtesy Dr. Thaddeus Kelley), showed normal levels of fucosidase, mannosidase, β -galactosidase, hexosaminidase, arylsulfatase, and α -iduronidase. On two runs of radioactive sulfate accumulation the cultures from the proband were similar to the controls.

Other Family Members: An investigation of the family history revealed two other relatives, a brother and a maternal uncle, who appear to have had the same disease as the proband (Figure, a). Further, it appears that the proband's

mother is mildly affected, and a maternal aunt and maternal grandmother may show minor signs of the disease.

The proband's brother was born in 1954 after a normal, uncomplicated pregnancy, labor, and delivery. He sat alone at 6 months, but walking was delayed until 18 months and even then he had trouble with his balance. A diagnosis of rickets was made at about 1 to 2 years of age and he was admitted to a children's hospital in 1958 for evaluation of his deformities. Physical examination revealed severe kyphosis in the low dorsal and upper-lumbar spine and marked genu valgus with enlargement of the knee joints. Motion through the hip joints was slightly restricted in external and internal rotation and in extension. The radiologist's report stated that there was "generalized disease of cartilaginous development," and that the changes seen were consistent with a diagnosis of Morquio disease. The patient was seen again in 1961 at which time he was ambulatory; however, the deformities about the knees had increased as had the kyphosis. He was attending school and was reported to be doing well. A physical examination following admission to a hospital for respiratory stridor in 1970 noted him to be a grossly skeletally deformed dwarf (height 40 in; weight 60 lb), with coarse facies, ocular hypertelorism, flaring of the alae nasae, saddle nose, pectus carinatum, and marked kyphoscoliosis. There was darting nystagmus but no corneal clouding. He was treated unsuccessfully with

aminophylline and died three days after admission, the cause of death being listed as terminal cardiorespiratory failure with interstitial pneumonia of viral etiology.

The proband's mother is a 51-year-old woman with coarse features and difficulty in walking. Her height is 62 in. Radiographs in 1976 showed mild degenerative changes in the distal phalanges of the hand and in the body of T-12 as well as partial collapse of the latter. Accentuated lordosis of the lumbosacral spine was noted with anterior lipping and mild degenerative changes. There was deformity of the feet with pes cavus bilaterally. The long bones showed early degenerative changes about the hips. The iliac bones were shortened and there was flattening of the acetabular roof. These changes were similar to, but much less severe than, those found in her son.

The proband's mother reported that she had had a brother, born in 1929, who was affected similarly to her two sons. He appears to have followed the same clinical course and died in 1950, reportedly from the same type of illness as his deceased nephew.

Also noted in the family history is a maternal aunt who walks with difficulty, although she is reported to be of normal height; the maternal grandmother has the same type of walking difficulty. The proband's two sisters, who have two different fathers, are of normal height and appearance and present a striking contrast to their mother.

The family history is very suggestive of X-linked inheritance, with the males being affected more severely than the females.

Discussion

On the basis of radiographic, biochemical, and ophthalmologic findings, Morquio disease and the other mucopolysaccharidoses were eliminated from the diagnosis.¹ Of the spondyloepiphyseal dysplasias (SED),² SED congenita, and SED tarda and SDT tarda brachyolmia type were considered. SED congenita is an autosomal dominant in which the deformities are present at birth and it is further differentiated from this case by its characteristic presence of rhizomelia and retinal detachment. SED tarda is a relatively mild form of X-linked recessive dwarfism in which the age of onset is between 5 to 10 years of age.

SDT brachyolmia is also a mild form of dwarfism in which the skeletal deformities are not consistent with the radiographic findings in this case. None of the mucopolysaccharidoses nor the SEDs show the striking lacelike ossification described in our patient.

Parastremmatic dwarfism^{3,4} was considered because of the distinctive lacelike ossification of the bones; however, in a written communication, in February, 1977, with Dr. Langer, who first described parastremmatic dwarfism, it was noted that our patient did not have the classic twisting or bowing of the long bones. The essentially normal configuration of the proximal femora and the type of changes seen in the vertebral bodies differentiate this case from parastremmatic dwarfism which is considered to be an autosomal dominant disease.

We feel that this patient represents an X-linked form of dwarfism, not previously described, which is characterized by coarse facies, severe skeletal deformities involving nearly all bones, and a distinctive lacelike ossification of the iliac bones, the end plates in the spine, and the epiphyses and metaphyses of the knees and elbows. In such cases neurologic and cardiopulmonary complications lead to demise in late adolescence or early adulthood.

REFERENCES

1. LEGUM CP, SCHORR S, BERMAN ER: The genetic mucopolysaccharidoses and mucopolipidoses: Review and comment. *Adv Pediatr* 22:305-347, 1976.
2. BAILEY JA: *Disproportionate Short Stature*. Philadelphia, WB Saunders Company, 1973, pp 438-524.
3. LANGER LO JR, PETERSON D, SPRANGER J: An unusual bone dysplasia: Parastremmatic dwarfism. *Am J Roentgenol Radium Ther Nucl Med* 110:550-560, 1970.
4. HORAN F, BEIGHTON P: Parastremmatic dwarfism. *J Bone Joint Surg* 58:343-346, 1976.