

Intrapulmonary Lymph Node Presenting as a 'Coin' Lesion: A Case Report

SIBU P. SAHA, M.D.
PORTER MAYO, M.D.

Intrapulmonary lymph node seldom presents as a solitary pulmonary nodule. This rare clinical entity is reported in the following case:

Case Report

A 40-year-old woman was evaluated because of the radiological finding of a noncalcified, non-cavitary, solitary, pulmonary nodule. She was asymptomatic at the time of examination. The patient's past history included hiatal hernia, duodenal ulcer, and recurrent supraventricular tachycardia. She has habitually smoked one pack of cigarettes daily for 15 years. The physical examination was unremarkable except for mild obesity.

A round density in the right infrahilar area was found in chest roentgenogram, which was not present in previous films. Tomographic examination showed a smooth mass without cavitation and calcification (Figure).

Bronchoscopic examination was normal and the patient underwent exploratory right thoracotomy. A firm, smooth mass was located in the anteromedial segment of the right lower lobe. A vertical incision was made directly over the lesion to a depth of approximately 2 cm through the lung tissue. The exposed nodule was completely excised and reported as benign intrapulmonary lymph node. The post-operative course was uneventful.

Discussion

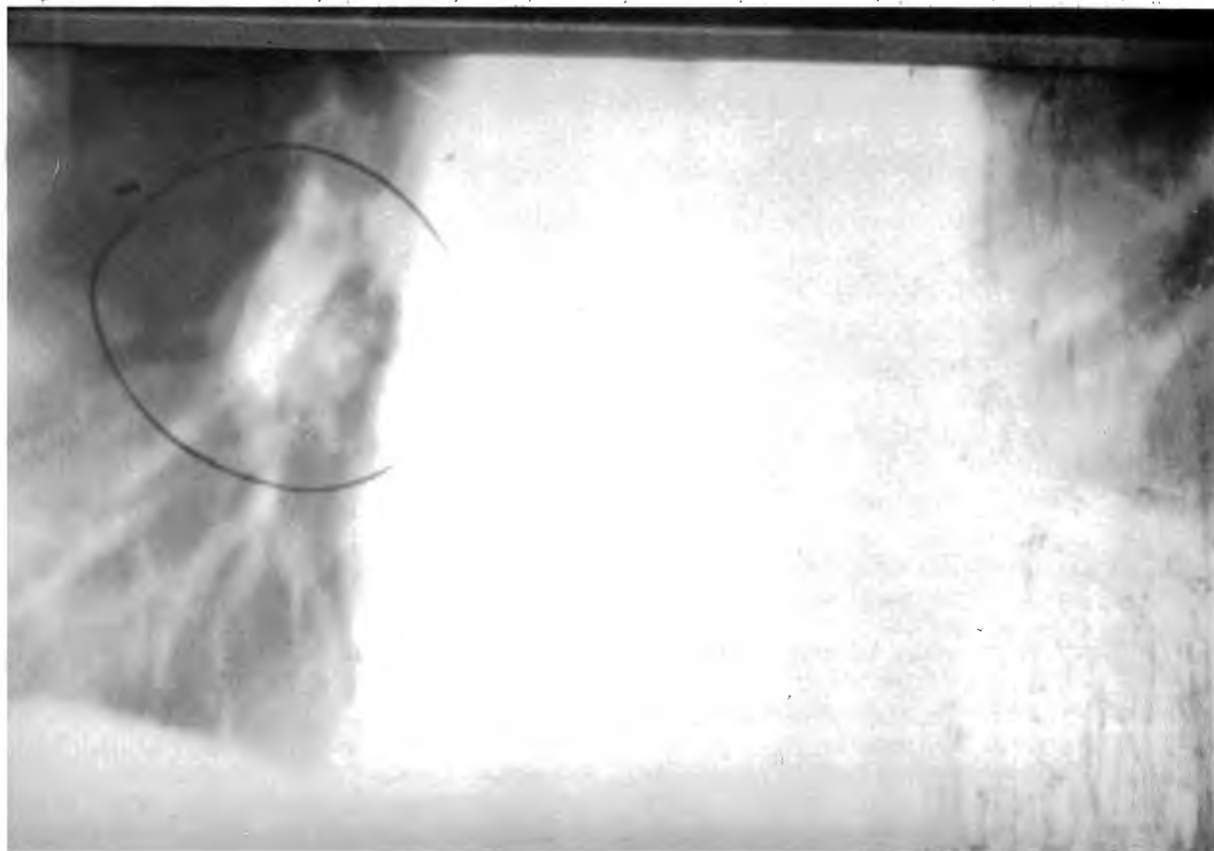
An intrapulmonary lymph node large enough to present as a "coin" lesion on chest x-ray is rare. Steele¹ reported only four such cases in 887 resected solitary pulmonary nodules. Lymph nodes are normally found around the main bronchi and its lobar branches, usually extending only as far as the third or fourth divisions. Only aggregations of lymphoid tissue are found beyond this point. According to Trapnell,² Miller believed that the intrapulmonary lymph nodes developed in abnormal lung from lymphoid tissue. The lymphoid tissue in lungs would increase with age, probably in response to inhaled carbon particles or infections. Trapnell in his study of 92 postmortem lungs found six cases of intrapulmonary lymph node and concluded that "such nodes are not nearly so uncommon as is suggested by the literature." Greenberg³ reported a case of subpleural lymph node in 1961. This was a hyperplastic lymph node caused by anthracotic particles. A similar case has been reported by Rosenthal and his associates.⁴

Exploratory thoracotomy followed by resection continues to be the most commonly used method in the diagnosis and treatment of a solitary pulmonary nodule.

Summary

A case of intrapulmonary lymph node presenting as a solitary pulmonary nodule is presented with a brief discussion.

Correspondence and reprint requests to Dr. Siby P. Saha, 2121 Nicholasville Road, Lexington, KY 40503.



Figure—Tomogram of a noncavitary, noncalcified intrapulmonary mass.

Acknowledgment: We thank Connie Powell for her assistance in the preparation of this manuscript.

REFERENCES

1. STEELE JD: The solitary pulmonary nodule. *J Thorac Cardiovasc Surg* 46:21-39, 1963.
2. TRAPNELL DH: Recognition and incidence of intrapulmonary lymph nodes. *Thorax* 19:44-50, 1964.
3. GREENBERG HB: Benign subpleural lymph node appearing as a pulmonary "coin" lesion. *Radiology* 77:97-99, 1961.
4. ROSENTHAL DS, WEG JG: Intrapulmonary lymph node presenting as a solitary pulmonary nodule. *Dis Chest* 51:336-337, 1967.