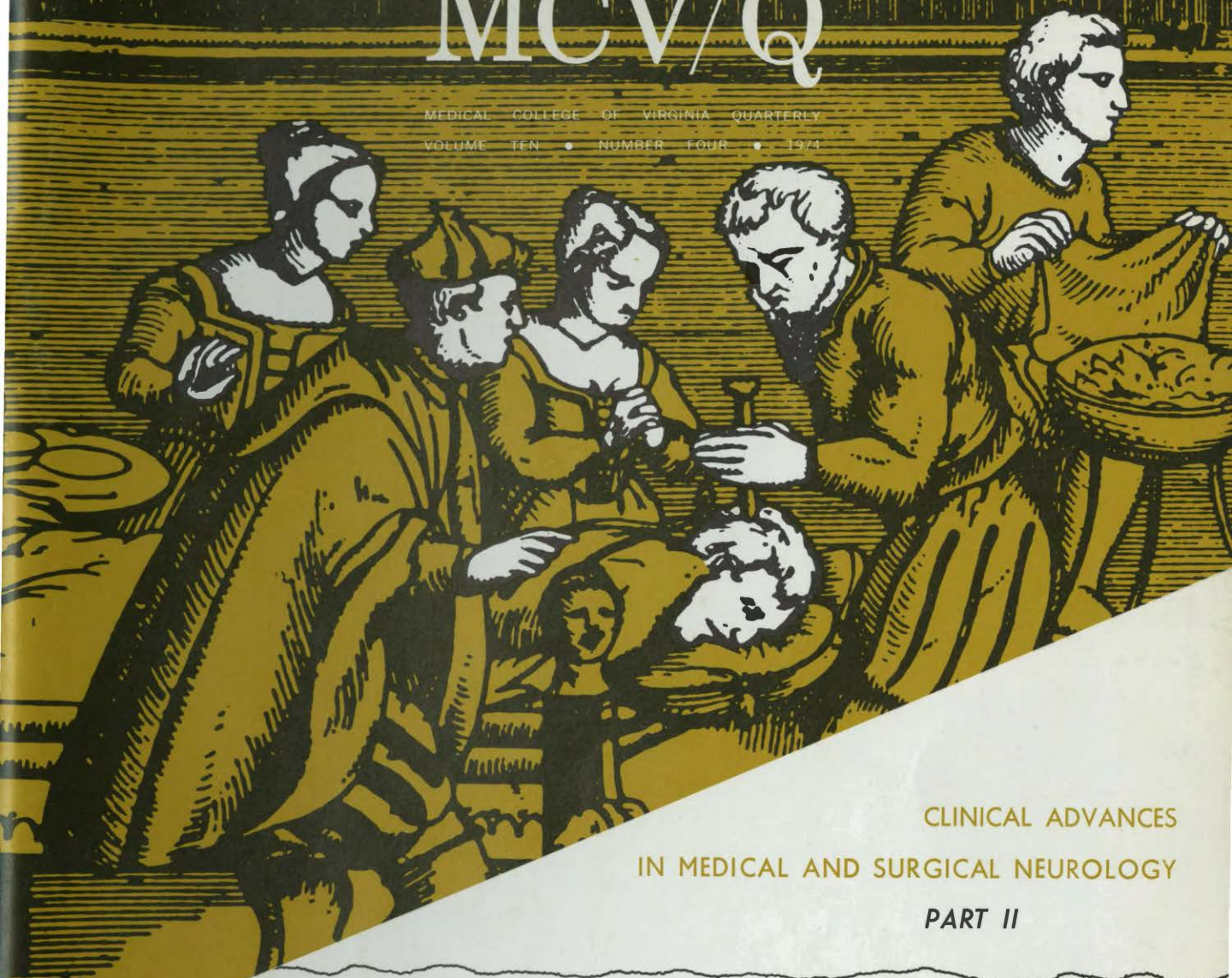
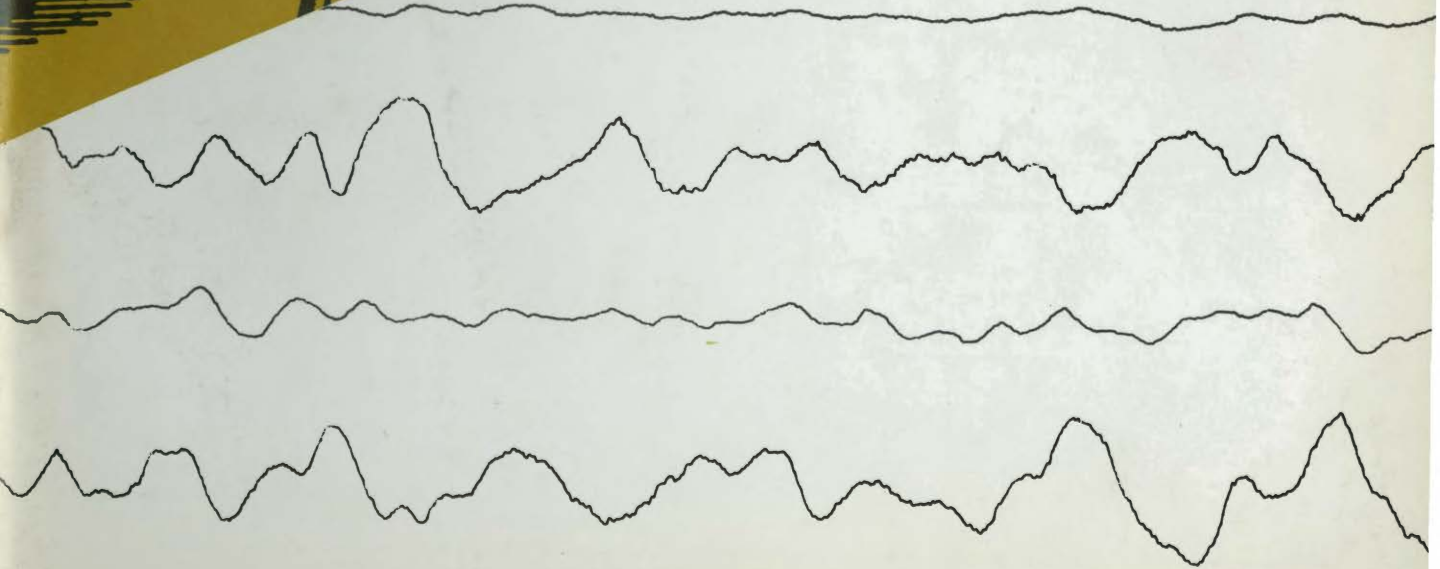


MCV/Q

MEDICAL COLLEGE OF VIRGINIA QUARTERLY
VOLUME TEN • NUMBER FOUR • 1974



CLINICAL ADVANCES
IN MEDICAL AND SURGICAL NEUROLOGY
PART II



When cardiac complaints occur in the absence of organic findings, underlying anxiety may be one factor



The influence of anxiety on heart function

Excessive anxiety is one of a combination of factors that may trigger a series of maladaptive functional reactions which can generate further anxiety. Often involved in this vicious circle are some cardiac arrhythmias, paroxysmal supraventricular tachycardia and premature systoles. When these symptoms resemble those associated with actual organic disease, the overanxious patient needs reassurance that they have no

Before prescribing, please consult complete product information, a summary of which follows:

Indications: Relief of anxiety and tension occurring alone or accompanying various disease states.

Contraindications: Patients with known hypersensitivity to the drug.

Warnings: Caution patients about possible combined effects with alcohol and other CNS depressants. As with all CNS-acting drugs, caution patients against hazardous occupations requiring complete mental alertness (*e.g.*, operating machinery, driving). Though physical and psychological dependence have rarely been reported on recommended doses, use caution in administering to addiction-prone individuals or those who might increase dosage; withdrawal symptoms (including convulsions), following discontinuation of the drug and similar to those seen with barbiturates, have been reported. Use of any drug in pregnancy, lactation, or in women of childbearing age requires that its potential benefits be weighed against its possible hazards.

Precautions: In the elderly and debilitated, and in children over six, limit to smallest effective dosage (initially 10 mg or less per day) to preclude ataxia or oversedation, increasing gradually as needed and tolerated. Not recommended in children under six. Though generally not recommended, if combination therapy with other psychotropics seems indicated, carefully consider individual pharmacologic effects, particularly in use of potentiating drugs such as MAO inhibitors and phenothiazines. Observe usual precautions

organic basis and that reduction of excessive anxiety and emotional overreaction would be medically beneficial.

The benefits of antianxiety therapy

Antianxiety medication, when used to complement counseling and reassurance, should be both effective and comparatively free from undesirable side effects. More than 13 years of extensive clinical experience has demonstrated that Librium (chlordiazepoxide HCl) fulfills these requirements with a high degree of consistency. Because of its wide margin of safety, Librium may generally be administered for extended periods, at the physician's discretion, without diminution of effect or need for increase in dosage. If cardiovascular drugs are necessary, Librium is used concomitantly whenever anxiety is a clinically significant factor. Librium should be discontinued when anxiety has been reduced to appropriate levels.

For relief of
excessive anxiety
adjunctive

Librium® 10mg
(chlordiazepoxide HCl)
1 or 2 capsules t.i.d./q.i.d.



Roche Laboratories
Division of Hoffmann-La Roche Inc.
Nutley, N.J. 07110

in presence of impaired renal or hepatic function. Paradoxical reactions (e.g., excitement, stimulation and acute rage) have been reported in psychiatric patients and hyperactive aggressive children. Employ usual precautions in treatment of anxiety states with evidence of impending depression; suicidal tendencies may be present and protective measures necessary. Variable effects on blood coagulation have been reported very rarely in patients receiving the drug and oral anticoagulants; causal relationship has not been established clinically.

Adverse Reactions: Drowsiness, ataxia and confusion may occur, especially in the elderly and debilitated. These are reversible in most instances by proper dosage adjustment, but are also occasionally observed at the lower dosage ranges. In a few instances syncope has been reported. Also encountered are isolated instances of skin eruptions, edema, minor menstrual irregularities, nausea and constipation, extrapyramidal symptoms, increased and decreased libido—all infrequent and generally controlled with dosage reduction; changes in EEG patterns (low-voltage fast activity) may appear during and after treatment; blood dyscrasias (including agranulocytosis), jaundice and hepatic dysfunction have been reported occasionally, making periodic blood counts and liver function tests advisable during protracted therapy.

Supplied: Librium® Capsules containing 5 mg, 10 mg or 25 mg chlordiazepoxide HCl. Libritabs® Tablets containing 5 mg, 10 mg or 25 mg chlordiazepoxide.

MCV/Q

MEDICAL COLLEGE OF VIRGINIA QUARTERLY

*A Scientific Publication of the School of Medicine
Health Sciences Division of Virginia Commonwealth University*

1974 • Volume Ten • Number Four

MEDICAL COLLEGE OF VIRGINIA QUARTERLY Published quarterly (Spring, Summer, Fall, Winter), by the Medical College of Virginia, Division of Health Sciences, Virginia Commonwealth University. The QUARTERLY publishes results of original research in basic and clinical sciences. Contributions from outside the Medical College of Virginia faculty are invited. Manuscripts, submitted in duplicate, should be prepared according to recommendations in the Style Manual for Biological Journals, Washington, D.C., American Institute of Biological Sciences, Second Edition, 1964.

Correspondence: MEDICAL COLLEGE OF VIRGINIA QUARTERLY, Medical College of Virginia, Richmond, Virginia 23298. Phone 804/770-4027.

Subscription rates for U.S.A., Canada, and Mexico: 1 year, \$6.00; 2 years, \$10.00; 3 years, \$14.00. All other countries: 1 year, \$8.00; 2 years, \$12.00; 3 years, \$15.00. Libraries and institutions: (U.S.A.) 1 year, \$12.00; 2 years, \$20.00; 3 years, \$28.00; (*foreign*) 1 year, \$13.00; 2 years, \$21.00; 3 years, \$29.00. Interns, residents, and students: 1 year, \$3.00. Single issue: \$2.00.

Third class postage paid at Richmond, Virginia.

Editorial Advisory Board

John T. Farrar
Ernst G. Huf
Hunter H. McGuire
M. Pinson Neal, Jr.
Kinloch Nelson
Frederick J. Spencer

Editorial Consultants

Larry F. Cavazos *Boston*
Richard G. Lester *Durham*
Sami I. Said *Dallas*
Malcolm E. Turner, Jr. *Birmingham*

Editor

Fairfield Goodale, Jr.
Managing Editor
Catherine C. Elverston
Editorial Assistant
Alice C. Reier
Cover Design
Raymond A. Geary

CONTENTS

Clinical Advances in Medical and Surgical Neurology—Part II

Sponsored by the Department of Continuing Education and the Division of Neurosurgery, Medical College of Virginia, Health Sciences Division of Virginia Commonwealth University.

DONALD P. BECKER, M.D., *Guest Editor*

Introduction	166
DONALD P. BECKER, M.D.	

Clinical Advances in the Management of Patients with Severe Head Injury	167
THOMAS W. LANGFITT, M.D.	

Continuous Intracranial Pressure Monitoring in Patients with Brain Injury: Technique and Application	174
JOHN K. VRIES, M.D.	

Neuro-Ophthalmology in Severe Head Injury	178
JOHN W. HARBISON, M.D.	

Advances in Neuroradiology	183
FREDERICK S. VINES, M.D.	

Advances in the Management of Pituitary Tumors	192
CHARLES B. WILSON, M.D.	

Advances in the Treatment of Patients with Benign Brain Tumors	196
HAROLD F. YOUNG, M.D.	

Advances in the Management of Patients with Malignant Brain Tumors	200
CHARLES B. WILSON, M.D.	

Clinical Advances in the Management of Patients with Severe Head Injury*

THOMAS W. LANGFITT, M.D.

-
- Practical Anticonvulsant Pharmacokinetics** 205
R. B. DAVID, M.D.
L. K. GARRETTSON, M.D.
-

- Advances in the Medical and Surgical Management of Intractable Partial Complex Seizures** 208
HOOSHANG HOOSHMAND, M.D.
-

- Radical Reconstruction of Complex Cranio-Orbito-Facial-Abnormalities** 220
JOHN A. JANE, M.D., PH.D.
MILTON T. EDGERTON, M.D.
-

- Progress and Problems in the Rehabilitation of Patients with Central Nervous System Injuries** 224
L. D. AMICK, M.D.
-

COVER: "Scene of a trepanation performed by André de la Croce." Engraving used as part of design for Part I and II is from Horrax, Gilbert, *Neurosurgery: An Historical Sketch*, First Edition, 1952. Courtesy Charles C. Thomas, Publisher, Springfield, Illinois.

© 1974 by the Medical College of Virginia, Health Sciences Division of Virginia Commonwealth University
Printed by the William Byrd Press, Richmond, Virginia

MCV/Q

MEDICAL COLLEGE OF VIRGINIA QUARTERLY

A Scientific Publication of the School of Medicine
Health Sciences Division of Virginia Commonwealth University

1974 • Volume Ten • Number Four

MEDICAL COLLEGE OF VIRGINIA QUARTERLY

Published quarterly
Spring, Summer, Fall, Winter, by the
Medical College of Virginia, Division of
Health Sciences, Virginia Commonwealth
University. The QUARTERLY publishes
results of original research in basic and
clinical sciences. Contributions from ex-
tra-mural investigators are invited. Manuscripts, abstracts, and
reprints are available. Manuscripts should be submitted to the
Editorial Board, Medical College of Virginia, Box 980, Richmond,
Virginia 23298. Phone 361-7700.

Subscription rates for U.S.A. and
Foreign: Single issue, \$4.00; 4 issues
per year, \$16.00. All other rates
available on request. Single issue, \$4.00;
4 issues per year, \$16.00. All other rates
available on request.

Correspondence: MEDICAL COLLEGE OF VIRGINIA QUARTERLY,
Box 980, Medical College of Virginia,
Richmond, Virginia 23298. Phone 361-7700.

Subscription rates for U.S.A. and
Foreign: Single issue, \$4.00; 4 issues
per year, \$16.00. All other rates
available on request. Single issue, \$4.00;
4 issues per year, \$16.00. All other rates
available on request.

Single issue, \$4.00.

Single issue, \$4.00.

Single issue, \$4.00.

Single issue, \$4.00.

Single issue, \$4.00.

Single issue, \$4.00.

Single issue, \$4.00.

Single issue, \$4.00.

Single issue, \$4.00.

Single issue, \$4.00.

INTRODUCTION

This issue represents the second part of the 27th Annual Stoneburner Lecture Series delivered at the Medical College of Virginia in February 1974. The first part emphasized basic and clinical aspects of cerebral vascular disease and basic mechanisms in brain injury and was published in the preceding issue of the *MCV/Q*.

Here, we are dealing with clinical applications of recent advances in our understanding of brain mechanisms and brain disease processes. The Stoneburner Lecturer was Dr. Thomas W. Langfitt, the Charles H. Frazier Professor and Chairman of the Division of Neurosurgery at the University of Pennsylvania.

DONALD P. BECKER, M.D.

*Professor and Chairman
Division of Neurosurgery
Medical College of Virginia
Virginia Commonwealth University*

Clinical Advances in the Management of Patients with Severe Head Injury*

THOMAS W. LANGFITT, M.D.

*Charles H. Frazier Professor and Chairman, Division of Neurosurgery,
University of Pennsylvania, Philadelphia*

Some of the physiological properties of the cerebral circulation, intracranial pressure and brain metabolism, as well as some of the pathophysiological alterations that we see with various types of brain injuries have been discussed in this series. We are going to see how we can apply some of this information clinically. I will begin with a patient.

A patient, comatose following a severe head injury, is brought into the emergency room. Our method of managing these patients has evolved over a number of years. Although I shall present the procedure to you sequentially, in fact, much is done virtually simultaneously. As always, the first thing that one must attend to is the airway. The majority of comatose head-injured patients, upon admission to the emergency ward, have a hyperventilation syndrome. It is of primary necessity, in this situation, to obtain an arterial blood sample for measurement of PaO_2 , PaCO_2 , and pH. Frequently, the patient is hypocapnic, with a PaCO_2 of perhaps 30, and is hypoxic as well. In a large series from several clinical units, the average PaO_2 of several hundred patients at the time of admission was about 65–70 mm Hg—somewhat hypoxic but generally not severely so.

How can the patient be hyperventilating, be hypocapnic, and hypoxic at the same time? Nearly all of these patients have some degree of pulmonary arteriovenous shunting but are able to eliminate the CO_2 with their relatively inadequate respirations, because CO_2 diffuses across the alveolar membrane at

twenty times the rate of oxygen. At the same time, they are not able to get enough O_2 into the blood. Hypoxia and hypocapnia are a very common pulmonary syndrome in these patients.

If the patient looks as though he is severely brain injured and is not going to recover soon, we go straight to intubation after drawing the arterial blood gas. The patient's airway is cleaned and he is then ventilated with an Ambu® bag. By now, someone is taking the blood pressure and the heart rate. If the patient has a mass lesion, then, in a majority of cases, he has a so-called Cushing response consisting of arterial hypertension. He may or may not have bradycardia; in fact, in our experience, in the acute brain injured patient, tachycardia is more common than bradycardia, except in those patients with acute extradural hematomas. A decision must be made now as to how to manage the patient over the next hour. We give dexamethasone (10 mg IV), although I am not at all convinced that the patients are benefitted by it. If the patient is in extremis, we give 1.5 mg/kg of hypertonic mannitol by IV push, in the hope of buying time for angiography. We like to have angiography for all of these patients as soon as possible. It must be remembered, however, that if done within an hour or two of the injury, one may miss the hematoma that is in the process of developing. If the neurosurgeon in charge feels that there is not time for an angiogram, the surgeon may perform exploratory burr holes. We avoid this operation if possible, since we feel that angiography gives so much information. (The technique mentioned in Dr. Vries' presentation of inserting a ventricular cannula, injecting some air, and then treating the patient immediately, depending

* This is an edited transcription of a lecture presented by Dr. Langfitt at the 27th Annual Stoneburner Lecture Series, February 8, 1974, at the Medical College of Virginia, Richmond.

upon what that air study shows is impressive; if the patient has a shift, take him directly to the operating room.) If the patient does not have a mass lesion, a Scott cannula is placed through a twist drill hole into the anterior horn of the right lateral ventricle, in order to measure intracranial pressure continuously. If the patient goes to the operating room and has a mass lesion removed, the Scott cannula is put into the anterior horn of the lateral ventricle at the time of surgery.

The patient is then returned to the neurosurgical intensive care unit, where we go through a number of procedures which will constitute the bulk of my discussion. Figure 1 is simply an artist's sketch of the Scott cannula in the anterior horn of the right lateral ventricle at the level of the coronal suture. Again, Figure 2 is an artist's sketch of the patient in the intensive care unit with the head dressing and the Scott cannula. The transducer is wrapped in a sterile towel because there is a risk of infection from an inside-outside connection of CSF, and this requires meticulous technique. In 350 cases, we have had an infection rate of about 2%, which compares favorably with Lundberg's 1.6% infection rate in something

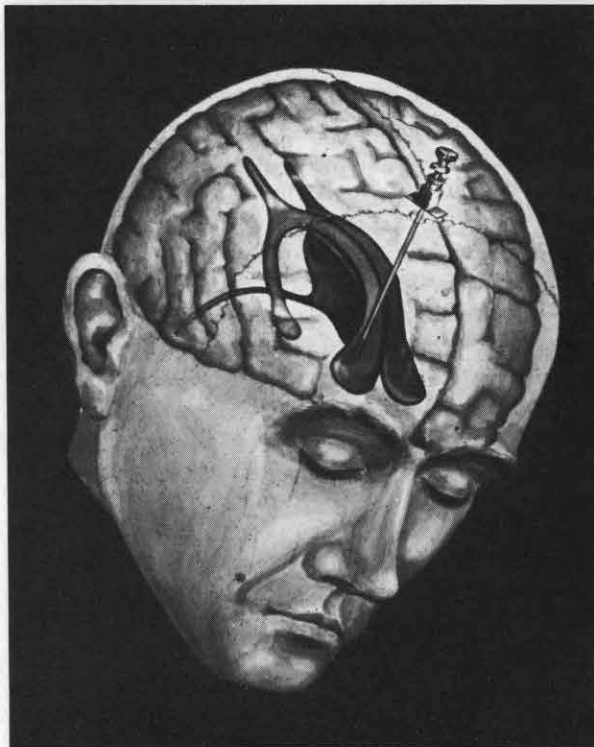


Fig. 1

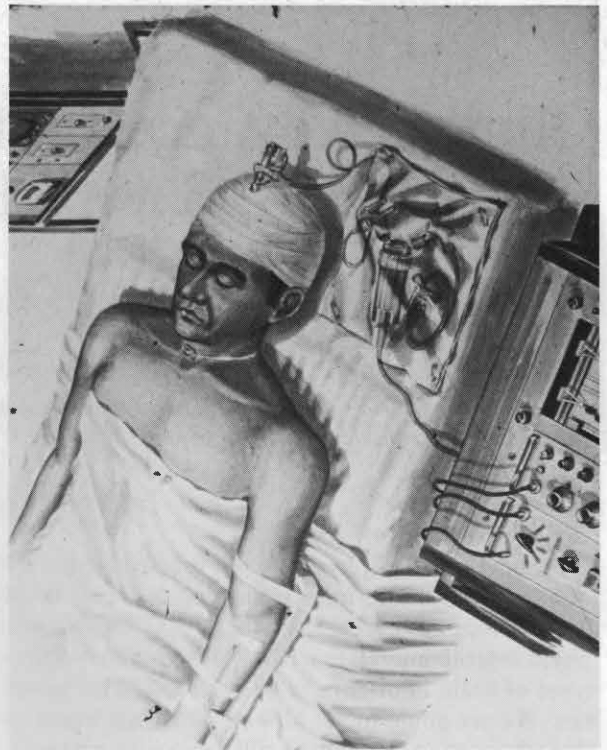

Fig. 2

over 1,000 patients with continuous recording of intracranial pressure. We would like to get rid of the intraventricular cannula, because we consider 2% to be still too high, but we do not feel, at this time, that there is an adequate solid state transducer for measuring intracranial pressure.

Figure 2 also shows a two channel strip chart recorder. One channel records the intracranial pressure and the other, systemic arterial pressure from a catheter in either the radial or the brachial artery.

At this point, we prepare to do regional cerebral blood flow and metabolism studies. We use the ^{133}Xe clearance technique, in order to measure regional cerebral blood flow (RCBF). Xenon is injected through a catheter placed under fluoroscopic control into the internal carotid artery and the xenon is then injected as a bolus. The xenon enters the brain, diffuses into the brain tissue, and is then cleared from the tissue over a period of about 15 minutes. The rate of clearance from each region under study determines the blood flow; therefore, the faster the rate of clearance, the faster the flow. There are a number of ways of examining and analyzing these clearance

curves. We feel, for our purposes, that eight probes for measuring RCBF over each hemisphere are perfectly adequate. There are, however, extremely sophisticated systems in which it is possible to measure the RCBF from as many as 250 regions.

In addition, a second catheter is placed percutaneously into the jugular vein and passed well up into the intracranial space, into the sigmoid sinus, in order to obtain a cerebral venous blood sample. Periodically during the course of the clinical investigation, simultaneous samples of blood are taken from the artery (from the internal carotid artery, in this case) and from the jugular bulb, from which it is possible to calculate the cerebral metabolic rate of oxygen (CMR_{O_2}). Studies on the cerebral metabolic rate of glucose, lactate, and pyruvate have been done as well. In fact, if one's techniques are sophisticated enough, accurate enough, in theory at least, it is possible to measure anything that the brain utilizes by measuring the content in both the arterial blood and the cerebral venous blood. Here we shall discuss only CMR_{O_2} , oxygen utilization. First, we determine the O_2 content in both the arterial and venous samples; CMR_{O_2} is equal to the arteriovenous difference of oxygen content times the mean cerebral blood flow divided by 100.

Table 1 shows a selection of the normal values, such as CBF, approximately 50 ml/100 gm/min, systemic arterial pressure, about 85. We defined, as have others, normal intracranial pressure as less than 200 mm CSF or less than 15 mm Hg. The cerebral perfusion pressure, assuming an ICP of 10, is 75 mm Hg, the normal arterial-venous oxygen difference ($AVDO_2$) is 7—a figure to remember. The CMR_{O_2} is 3.5 ml/100 gm/min and the normal values for arterial blood gases and pH are familiar to you.

For the sake of example, a single patient will now be described in detail.

A 50-year-old man had been found on the street and was brought into the emergency ward comatose; he had bruises about the head, indicating that he had been bludgeoned, and there were clinical signs pointing to a left hemispheric mass with evidence of transtentorial herniation. He was given dexamethasone and mannitol and was intubated and ventilated with the Ambu® bag. The resident who was caring for him felt that he was in extremis, that there was not enough time to do an angiogram, despite the administration of mannitol; therefore, the patient was taken to the operating room for burr holes. There was no evidence of an extracerebral

TABLE 1

Normal values of variables tested

Variable	Normal Value
cerebral blood flow (CBF)	50 ml/100 gm/min
systemic arterial pressure (SAP)	85 mm Hg
intracranial pressure (ICP)	15 mm Hg (200 mm CSF)
cerebral perfusion pressure (CPP)	75 mm Hg
cerebral vascular resistance (CVR)	1.70
arteriovenous blood oxygen content ($AVDO_2$)	7.0 vol %
cerebral metabolic rate ($CMRC_2$)	3.5 ml/100 gm/min
arterial carbon dioxide partial pressure ($PaCO_2$)	40 mm Hg
arterial oxygen partial pressure (PaO_2)	100 mm Hg
arterial blood acidity (pH)	7.35

(Reproduced by permission of the American Association of Neurological Surgeons, and the authors, from D. A. Bruce, et al, "Physiological Changes in Brain During Coma," *J Neurosurg* 38:133, 1973.)

hematoma; the resident needed the brain one time and got no blood, and the Scott cannula was put in along with a solid state transducer to measure intracranial pressure. The patient was then taken to the angiography suite, where we also do the RCBF and metabolism studies. On angiogram, the patient had a huge, temporal and deep mass in the hemisphere. The Scott cannula was, in this case, placed through a burr hole in the lateral ventricle. While the angiogram was being developed, we carried out our first RCBF and metabolism study.

Figure 3 demonstrates one of the ways in which we display the data. You will note that this patient, during the control period, had a mean CBF of 10 ml/100 gm/min, one-fifth normal and far below that ordinarily required to maintain brain function. The patient's mean systemic arterial pressure was 135 mm Hg, and the mean intracranial pressure extremely high at 107 mm Hg, giving the patient then a cerebral perfusion pressure (CPP) of 28. Note that at this time, the PaO_2 is quite adequate at 104 and the $PaCO_2$ is slightly low. The value for CMR_{O_2} —0.71—is one-fifth normal. One can state as a general rule, with the occasional rare exception, that any patient with CMR_{O_2} less than 1.0 probably will not survive.

The angiogram showed the huge mass which had been missed in the operating room with the single pass of the needle. The needle was then inserted into the region of the mass and we obtained 70 cc of blood. A second postevacuation study was per-

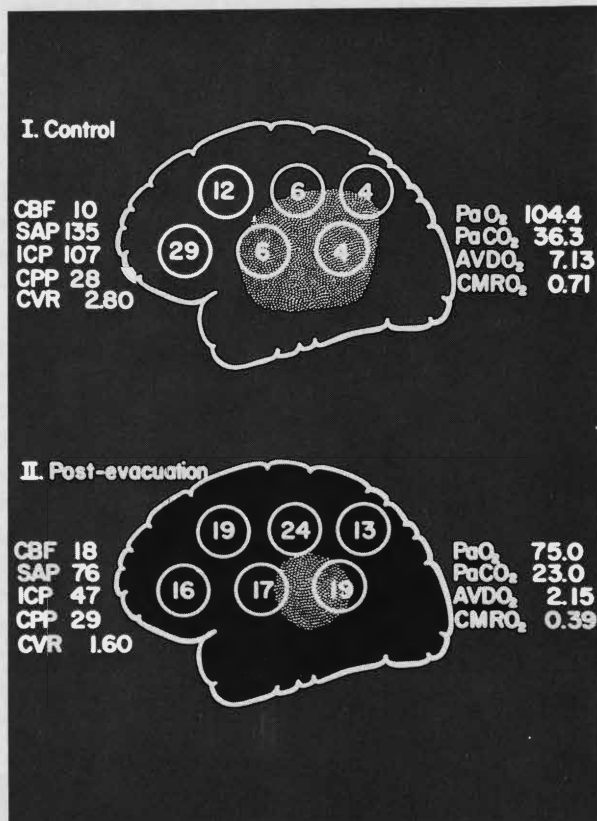


Fig. 3

formed, disclosing the reduced mass with the estimated increase in CBF from 10 to 18 ml/100 gm/min. In the region of the mass, where blood flow was virtually obliterated, we had a fourfold increase from 6 to 24 ml/100 gm/min. The intracranial pressure dropped from 107 to 47 mm Hg following evacuation of the mass. If we were measuring only the ICP, we might feel we had really accomplished something. The systemic arterial pressure, however, was being held up by a Cushing response, secondary to the intracranial hypertension. Although we markedly reduced the intracranial pressure, the blood pressure fell equally, and the perfusion pressure went only from 28 to 29; despite that, we did increase CBF by 8 ml/100 gm/min.

Now, however, another problem arose. The patient, comatose but showing slight evidence of arousal, went from flaccidity to some decerebrate posturing; he also began to hyperventilate, driving his PaCO₂ from 36 down to 23, but, at the same time, he developed acute pulmonary edema. Even though he was hyperventilating and producing hypocapnia,

because of the edema, we now saw his PaO₂ dropping also, from 104 to 75.

Despite the improvement in the CBF and some evidence of clinical improvement, the patient's CMRO₂ actually fell from 0.71 to 0.39, which is barely one-tenth of normal. We tried to raise his blood pressure, hoping to improve his perfusion pressure and further improve his CBF, then at 18. Figure 4 shows the response following angiotensin. We brought his SAP up to 129 from 76, but the CBF increased only from 18 to 23, because, with the arterial hypertension and the edema fluid, the intracranial pressure has gone from 47 to 74 mm Hg. In order to comprehend the pathophysiology of these patients, one must measure nearly all of these variables. Despite his marked hypocapnia and hyperventilation, his PaO₂ is still only 67 because of his pulmonary edema. We decided to give mannitol, and the patient, in terms of CBF, responded dramatically; CBF went from 23 to 38, perfectly adequate for a normally metabolizing brain, and ICP dropped from 74 to 48.

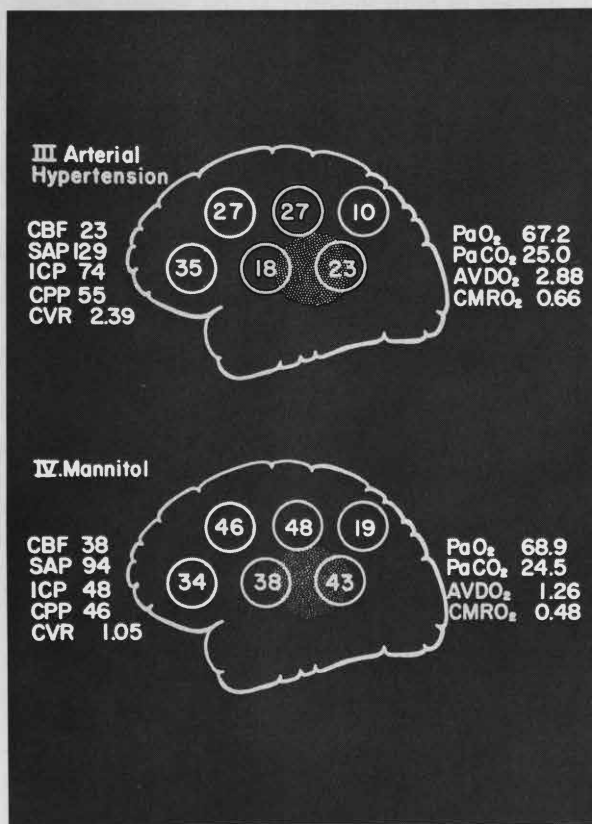


Fig. 4

Marked improvement in CBF occurred, despite the fact that the patient's perfusion pressure dropped from 55 to 46. A change in flow, of course, will occur with a change in perfusion pressure or a change in resistance or with a change in both, and, in this case, it is quite clear that the mannitol has reduced the edema, thereby opening up the microcirculation and permitting a marked improvement in CBF, despite there being no significant change in the patient's CPP. The Pa_{O_2} and Pa_{CO_2} were the same; the CMR_{O_2} was fluctuating somewhat.

We continued to battle his intracranial pressure, which, however, continued to rise, and finally, as is the rule in these cases, the intracranial pressure equaled the blood pressure. At this point, the phenomenon of nonfilling of the cerebral circulation upon angiography or injection of ^{133}X became evident. In this situation, if one injects radio-opaque media into the carotid artery, it will rise up into the internal carotid (sometimes to the level of the siphon) and then stop. A film taken 30 seconds or a minute later will show the opaque dye still sitting in the carotid artery, none having entered the intracranial space, due to the fact that ICP equals SAP and, therefore, CPP is zero. When this occurred in our patient, we decided he obviously had all of the clinical criteria of brain death. We decided, however, to manipulate the blood pressure with a vasopressor agent, Levophed®, to see whether we could possibly reestablish a perfusion pressure. These primary changes in systemic arterial pressure, produced by altering the rate of drip of a vasopressor agent, produced precisely equal changes in the ICP. There was no way to reestablish perfusion pressure by manipulating the arterial pressure. In this patient who had a severe and, as it turned out, irreversible brain injury, we were, by various types of manipulations, able to raise his CBF to something approaching a normal range, but too late, and the patient died shortly after this study.

Now, just a few comments on intracranial pressure. Until the publication of Lundberg's landmark monograph from the University of Lund in Sweden in 1960, we generally thought of ICP as being a steady phenomenon; intracranial pressure had been measured only through the lumbar subarachnoid space in the vast majority of patients. In 1963, we demonstrated in experimental animals (using a slowly expanding extradural balloon in the monkey), that when the intracranial pressure rises by virtue of expansion of a mass, a dissociation occurs invariably, between the supratentorial pressure and the pressure

of the lumbar subarachnoid space. Finally, with the slow expansion of the balloon, when the intracranial pressure reached the level of the blood pressure in the monkey, lumbar subarachnoid pressure was normal. We demonstrated that this also occurs in man. The higher the intracranial pressure, the greater the brain swelling, the less likely it is that the lumbar subarachnoid pressure will reflect that increased intracranial pressure. Many times in man, lumbar subarachnoid pressure is normal when the intracranial pressure is from 50–100 mm Hg. It follows, therefore, that one cannot use lumbar subarachnoid pressure to determine the actual pressure within the intracranial space. All pressure measurements today are done directly from the intracranial space by one method or another.

Lundberg then demonstrated that in many patients, intracranial pressure is not a steady phenomenon; in fact, there are tremendous fluctuations in pressure. He described what he called "A waves or plateau waves, B waves, and C waves." For the most part, these waves appear to be rather innocuous, there being, usually, no indication of neurological deterioration. With the extremely dangerous plateau wave, the intracranial pressure is reasonably steady, at first, but then fluctuates, and finally, inexorably rises—a terminal pressure wave.

Figure 5 summarizes work that we did some 10 or 11 years ago. It is a very simple figure but quite important. This is the volume pressure graph within the

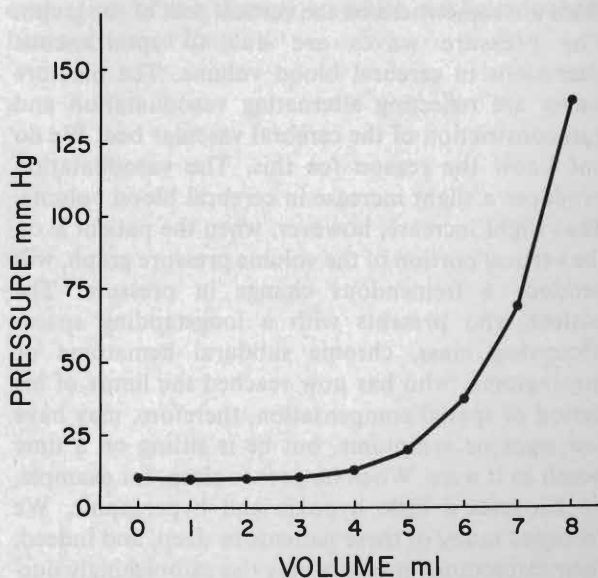


Fig. 5

intracranial space, actually taken from a series of monkeys. We put in an extradural balloon, and then slowly inflate it at a rate of 1 ml/min, while we measure the intracranial pressure. Up to a volume of about 5 ml in the balloon, there is no significant change in intracranial pressure. Why is this? Because the intracranial space contains displaceable fluid, mainly in the form of CSF but also, to some extent, in the form of intravascular blood. Since we are dealing with a cavity that is nondistensible, which is filled to capacity with a noncompressible fluid and solid material, it follows that if indeed we had a completely closed system, that is, if we had a sphere made of bone filled to capacity with water, and we attempted to inject additional water into that cavity, we could probably inject no more than 0.1 ml, in the case of the monkey; we would get a tremendous rise in intracranial pressure, simply because we cannot stretch the shell. We cannot compress the fluid. That is not the case in life. We can actually put 5 ml of fluid into this monkey's skull (total capacity of 100 ml), because of spatial compensation. It means that up to a value of about 5 ml, for every 1 ml that we are putting into the balloon, we are expressing 1 ml of CSF or blood. Then we pass from this period of spatial compensation, the horizontal portion of the volume pressure graph, onto the vertical portion. Note here that between a balloon volume of 7 and 8 ml, the intracranial pressure rises 75 mm Hg. Thus, in the case of those patients with pressure waves, those who have any kind of mass lesion or brain edema, the bulk of them are somewhere on the vertical part of the graph. The pressure waves are due to spontaneous alterations in cerebral blood volume. The pressure waves are reflecting alternating vasodilatation and vasoconstriction of the cerebral vascular bed. We do not know the reason for this. The vasodilatation produces a slight increase in cerebral blood volume. That slight increase, however, when the patient is on the vertical portion of the volume pressure graph, will produce a tremendous change in pressure. The patient who presents with a longstanding space-occupying mass, chronic subdural hematoma or meningioma, who has now reached the limits of his period of spatial compensation, therefore, may have few signs or symptoms, but he is sitting on a time bomb as it were. When he goes to sleep, for example, he becomes a little hypoxic and hypercapnic. We recorded many of these patients in sleep, and indeed, their intracranial pressure may rise astonishingly during sleep, simply because of a little bit of vasodilata-

tion from the hypercapnia. It follows as well, that if one is treating a patient who is on the vertical portion of the curve, it is necessary to remove only a small portion of any one of the volumes within the intracranial space in order to drop the pressure. We have many patients who have had pressure of 80–90 mm Hg. The removal of no more than 2 ml from the ventricle will drop the pressure down to 20–30 mm Hg, because they are falling on an extremely sharp vertical portion of the curve.

What constitutes a critical level of intracranial pressure for brain function? I have no idea, because it varies so much from patient to patient. The more the brain itself is damaged, that is, the more the edema, the more contusion, then the less tolerant that patient is of intracranial hypertension. We have many patients, for example, who would not tolerate an ICP above 25–30 mm Hg; they would obtund, develop a hemiparesis. When we then lowered the pressure to 10–15 mm Hg, they would improve. Patients who do not have brain damage but, nevertheless, have intracranial hypertension, will often tolerate extremely high levels of intracranial pressure. We have seen a young woman with severe hydrocephalus from a cerebellar hemangioblastoma. She was neurologically normal, except for minimal ataxia and some papilledema—her brain was normal. We recorded her intracranial pressure continuously through the Scott cannula and then slowly drained the ventricles over a period of two or three days, as we always do before doing posterior fossa surgery in these people. We also recorded and checked the systemic arterial pressure from the catheter in the radial artery. For very long periods of time, the patient had a CPP as low as 6 mm Hg, the mean intracranial pressure, 85, and the mean arterial pressure, 91; this particular time, she was in the intensive care unit, sitting up reading a magazine, completely asymptomatic. This is an indication of the phenomenal degree of autoregulation that can be seen clinically.

If a hypertonic solution such as mannitol has been given to a patient without causing reduction in his intracranial hypertension, we might conclude that mannitol has been of no benefit, and not give it to that patient again. We might say that the patient is refractory to mannitol.

Often this is not the case, and the patient improves despite no major ICP fall. How can this be? We postulate that mannitol has reduced edema. Reduction of the water content in the brain alone, obviously, should result in decrease in intracranial

pressure, but if one has compression of the microcirculation of the capillary bed in the venules by the edema, and one reduces the edema, what is going to happen to the cross-sectional area of the vascular bed? It will enlarge as the compression is relieved. Our guess is that as we remove the edema from the brain with the mannitol, the edema is being replaced by intravascular blood secondary to expansion of the cerebral vascular bed. The net intracranial volume remains the same, and intracranial pressure does not decrease. What these data clearly show is that one cannot use intracranial pressure alone to determine whether or not mannitol has had a beneficial effect on the patient; one must, unfortunately, measure CBF.

The first indication for the use of mannitol therapy, in our opinion, is for reducing brain bulk during craniotomy, and second, for reducing ICP to permit time for emergency cerebral angiography. The third indication for its use is control of ICP during *continuous recording of ICP*. I believe that the intermittent, or perhaps even the continuous, use of mannitol in these patients without continuous recording of intracranial pressure is very dangerous, because if the patient has a hemorrhage, a hematoma that is expanding, reduction of the intracranial pressure causes further expansion of the hematoma; then, as the osmotic gradient is reversed, fluid comes back into a space reduced by the enlargement of the hematoma. This kind of situation can kill the patient quickly.

I will conclude by saying that I think the continuous measurement of intracranial pressure in the proper management of patients not only with severe head injuries, but with severe brain insults as well,

has passed now from being a research tool to a virtual necessity. I cannot say the same thing, yet, about measurements of RCBF and cerebral metabolism, as we are now caught in an ethical bind. We have four or five RCBF runs, or consecutive studies, done on patients over several hours. Rarely have we been able to repeat these studies, because we did not feel justified in repuncturing the carotid artery, unless it was necessary to do an angiogram on the patient. My contention is that we would learn much more from one patient with severe brain injury who has ten CBF studies over a period of several days than we would learn from ten patients who have one study each. In order to prove that these techniques, which are expensive and time consuming, are really going to help us in the management of these patients, we now need to have a reliable noninvasive technique for doing RCBF. These techniques are now available, particularly in the form of either inhalation or intravenous injection of ^{133}Xe , but the mathematics are extremely complex and must be done with a laboratory computer, but I think they are promising. In our neurosurgical intensive care unit, we are just beginning to compare the carotid injection of xenon with the inhalation of xenon, to see how well the results correspond in our patients with severe brain injuries. If we obtain a reliable noninvasive technique and can repeat the RCBF studies every hour, day and night for as long as we wish, with no harm whatsoever to the patient, we will then be able to provide the intensive treatment for these patients and the evaluation of the therapy to which we have looked forward for so long.

Continuous Intracranial Pressure Monitoring in Patients with Brain Injury: Technique and Application*

JOHN K. VRIES, M.D.

*Assistant Professor of Neurosurgery, Medical College of Virginia,
Health Sciences Division of Virginia Commonwealth University, Richmond*

In 1971, a twist drill technique for measuring intracranial pressure (ICP) in patients with severe brain injuries was introduced at the Medical College of Virginia (1). Shortly thereafter continuous ICP monitoring utilizing the ventricular catheter technique of Lundberg was begun (2). It rapidly became evident that knowledge of the ICP in this group of patients speeded definitive diagnosis, provided an early warning of developing mass lesions before clinical signs appeared, and provided an objective assessment of therapy directed against brain edema; however, continuous monitoring by the Lundberg technique was cumbersome to perform and carried a significant risk of meningitis. In 1972, a new method of monitoring ICP was developed at our institution (3). The new method was based on the establishment of a fluid connection with the cerebral subarachnoid space by means of a special hollow screw. The technique proved much simpler and safer than the Lundberg technique. The development of this technique combined with the completion of a seven-bed neurosurgical intensive care unit extended ICP monitoring to all patients at our institution with significant head injuries. The morbidity and mortality for severe head injury have steadily declined as the scope of patient monitoring has increased over the last three years. We now consider ICP monitoring an essential part of head injury management.

Methods. Head injury patients are divided into 3 categories upon arrival at the emergency room based on their level of consciousness. Patients who are comatose upon arrival or patients with whom no verbal communication can be established are designated as severe (grade 3). Patients who are lethargic, but with whom verbal communication can be established, are classified as moderate (grade 2). Patients who are fully awake are classified as mild (grade 1). The presence of any focal neurologic signs increases the severity by one grade.

Grade 3 patients have an immediate twist drill ICP measurement. A twist drill hole three-sixteenths of an inch in diameter is made at the level of the coronal suture under local anesthesia. A ventricular tap is then performed with an 18 gauge blunt ventricular needle. ICP is measured by connecting the needle to a water manometer. After obtaining the ICP, 5-10 cc of air are exchanged into the ventricles and a brow-up ventriculogram is obtained to assess shift of the midline structures. Further management of these patients is based on the results of this examination. If the ICP is greater than 10 mm Hg and the midline structures are shifted, the patient is given 1 gm/kg of mannitol and is taken to the operating room for an exploratory craniotomy. If the ICP is greater than 10 mm Hg and the midline structures are not shifted, the patient is taken to the angiographic suite for angiography. If the ICP is below 10 mm Hg and the midline structures are not shifted, the patient is taken to the intensive care unit and an elective angiogram is obtained. Continuous ICP monitoring

* Presented by Dr. Vries at the 27th Annual Stoneburner Lecture Series, February 8, 1974, at the Medical College of Virginia, Richmond.

is performed on all grade 3 patients after they arrive at the intensive care unit.

Grade 2 patients are taken to the angiographic suite for immediate angiography. If a surgical mass lesion is discovered, the patient receives 1 gm/kg of mannitol and is taken to the operating room for a craniotomy. If no surgical mass lesion is found, the patient is taken to the intensive care unit. Continuous ICP monitoring is performed in all grade 2 patients after they arrive at the intensive care unit.

Grade 1 patients are admitted for close observation. If any clinical deterioration is noted, they are managed like grade 2 patients.

Continuous ICP monitoring is performed by means of a special hollow screw which permits fluid contact to be made with the cerebral arachnoid space. The screw is shown in Figure 1. The screw is inserted by threading it into the skull through a one-fourth-inch twist drill hole, after the dura has been removed with a small angled curette under direct vision. This is illustrated in Figure 2. ICP is monitored by connecting the lumen of the screw to a transducer by means of saline-filled tubing. The screw is shown in place in the x-ray of a postoperative patient in Figure 3. A typical ICP record, along with the blood pressure, central venous pressure, and EKG, is shown in Figure 4. The ICP is displayed at each bedside on a wall mounted oscilloscope, and it is written out at a central station on a strip chart for a permanent record.

A maximum effort is made in grade 3 patients, after they arrive at the intensive care unit, to keep the important systemic physiologic parameters within normal ranges. All patients in this grade are placed on a regimen of thorazine, 25 mg IM every 6 hours, to help accomplish this. All patients in this category have endotracheal tubes or tracheostomies. They are placed on volume respirators and nursed in the level position on heat exchange mattresses. On this regimen, blood pressure can usually be adjusted by raising or lowering the head of the bed, blood gases and pH can be regulated by adjusting the respirator, and the temperature is easily regulated with the heat exchange mattress.

Patients who have progressive brain edema, manifested by a steadily rising ICP after correction of any systemic abnormalities, in whom surgical mass lesion has been ruled out angiographically, are treated with ventriculostomy drainage and hyperventilation to a P_{CO_2} of 25 mm/Hg. If this fails to control the ICP, the patient is cooled to 30°C. If ICP still cannot be controlled, a mannitol infusion at a rate of




Fig. 1

0.1–0.3 gm/kg/hr is begun provided the serum osmolarity does not exceed 320 mOsm/L (4).

Results. In 1973, twist drill ICP measurement and ventriculogram were used in 96 grade 3 head trauma patients to establish a working diagnosis. On only one occasion was there failure to tap the ventricle. There were no recognizable complications related to the procedure. The average time required to perform the procedure was 10–15 minutes including the taking of x-rays. Fifty-eight of the 96 patients had elevated ICP and a shift of the ventricular system. All 58 patients had a surgical mass lesion confirmed at operation. Eleven patients had normal ICP and a midline ventricular system. None of these patients developed a surgical mass lesion. Twenty-seven

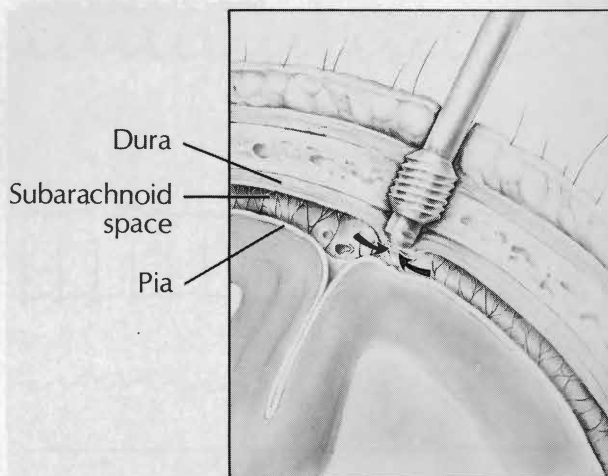


Fig. 2

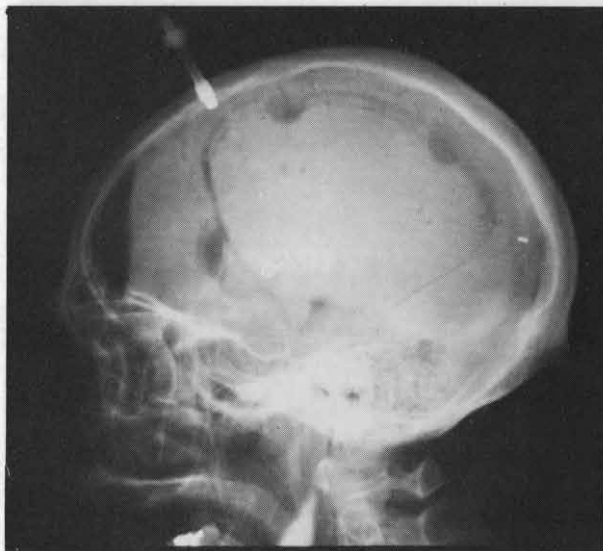

Fig. 3

patients had elevated ICP and a midline ventricular system. Twenty-six of the 27 did not have surgical mass lesions by angiography. One patient in this group had an acute subdural hematoma on one side and a brain contusion with edema on the other side, giving him elevated ICP but a midline ventricular system.

Since November 1972, ICP monitoring using the hollow screw technique has been performed 161 times. It has been performed 102 times for head trauma. In the vast majority of cases, a satisfactory

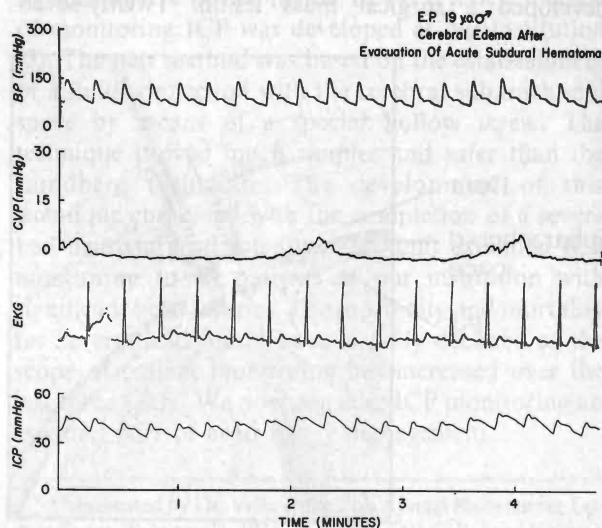


Fig. 4

recording of the ICP has been obtained, manifested by a good wave form on the oscilloscope trace. The average patient was monitored for seven days. The complications to date consist of four patients with superficial scalp infections, requiring local debridement, one CSF leak, requiring revision of a scalp incision, and one subdural hematoma, which occurred in a patient who developed a bleeding disorder after insertion of the monitor.

The ICP monitor provided warning of developing mass lesions in all cases where such lesions developed. Even though grade 3 patients were heavily sedated, which tended to obscure the clinical picture, no case of unsuspected mass lesion occurred. The use of high doses of morphine and thorazine made the management of the group 3 patients much easier. Problems of temperature control, severe hyperventilation on a neurogenic basis, and erratic blood pressure swings, for the most part, were eliminated. With improved control of systemic physiologic parameters, the need to resort to special regimens for the control of progressively increasing intracranial pressure was obviated. In 1972, 18 of these regimens were employed. In 1973, only one regimen was employed, even though more grade 3 patients were seen in 1973 than in 1972.

Discussion. Twist drill ICP measurement and ventriculogram appear to significantly speed the definitive diagnosis and treatment of severe head injury patients in the emergency room. The procedure had a high accuracy for differentiating between surgical and nonsurgical mass lesion. It can be accomplished in 10–15 minutes, which is much faster than an angiogram under the best of circumstances. It is easy to perform in the patient with multiple trauma, because it does not require that the patient be moved or transported to an angiographic suite. Moreover, in some grade 3 patients, it is safer because it does not require the degree of patient restraint and positioning that an angiogram requires which may produce jugular compression, or airway obstruction.

Continuous ICP monitoring using the hollow screw technique has proven itself simple, safe, and reliable. The obvious advantage of continuous ICP monitoring is to provide early warning of developing mass lesions before clinical signs appear and to assess the effectiveness of therapy directed at brain edema. Its most important use, however, may be that it permits the use of depressant medications in these patients. Many of these patients have a marked

tendency toward hyperthermia, severe hyperventilation, and erratic blood pressure swings. These tendencies can be most difficult to control with conventional treatment regimens. By sedating these patients, however, it is easy to override these tendencies with a respirator, a simple heat exchange mattress, and patient positioning. In many of these patients, all of the intracranial compensatory mechanisms for the maintenance of brain metabolism have been maximally taxed. These patients cannot tolerate the additional stress of disordered systemic physiology. At the present time, we try to hold our severe head injury patients within the following physiologic limits: cerebral perfusion pressure (blood pressure-intracranial pressure) 75 mm Hg \pm 10 mm Hg; P_{O_2} 85 mm Hg \pm 15 mm Hg; P_{CO_2} 30 mm Hg \pm 5 mm Hg; pH 7.4 \pm 0.1; temperature 37° C \pm 1° C; sodium 140 \pm 5; hematocrit 35 \pm 5. Our preliminary data seem to indicate that if this is accomplished and if it is combined with rapid diagnosis and treatment of surgical mass lesions, most cases of progressive

brain swelling can be prevented. At the present time, a prospective study of this regimen in head injury patients is underway at the Medical College of Virginia.

REFERENCES

1. VRIES JK, YOUNG HF, SAKALAS R, BECKER DP: Recent advances in the management of head injury patients. *Va Med Monthly* 100:1117, 1973.
2. LUNDBERG N: Continuous recording and control of ventricular fluid pressure in neurosurgical practice. *Acta Psychiat Scand (Suppl 149)* 36:1, 1960.
3. VRIES JK, BECKER DP, YOUNG HF: A subarachnoid screw for monitoring intracranial pressure. (Technical note) *J Neurosurg* 39:416, 1973.
4. BECKER DP, VRIES JK: The alleviation of increased intracranial pressure by the chronic administration of osmotic diuretics. *First International Symposium on Intracranial Pressure*, Hannover, Germany, Springer Verlag (Berlin), July, 1972.

Neuro-Ophthalmology in Severe Head Injury*

JOHN W. HARBISON, M.D.

*Associate Professor, Department of Neurology, Medical College of Virginia,
Health Sciences Division of Virginia Commonwealth University, Richmond*

If asked what the significance of neuro-ophthalmology is in the evaluation of severe head injury, many medical and surgical practitioners of neurology would promptly reply that it consists of monitoring pupillary reactivity in anticipation of the uncal herniation syndrome. A discussion of two broad premises of a factual nature, however, should easily convince these same practitioners that the neuro-ophthalmic evaluation of patients with severe head injuries offers far more than the Hutchinson pupil.

Anatomically, the substrate of the eye-brain mechanism is prodigious. It includes every cerebral lobe, the basal ganglia, all divisions of the brainstem, the cerebellum, half of the cranial nerves, and one-third of the spinal cord. The eye-brain mechanism can be involved or interrupted at virtually any level of the neuraxis. The resultant signs and symptoms provide a kaleidoscope of pupillary abnormalities, ocular motor disturbances of a peripheral and central nature, and visual disturbances ranging from impairment or loss of acuity and field to complex perceptual and associative visual disturbances.

The second factual premise is the extent of the head injury problem. Six percent of all disabling injuries involve the head. Automobile accidents, but one aspect of trauma, have a 66% incidence of head injuries. Within the American population at large, it is calculated that one person in two hundred will require medical care for head injury each year. Given

the anatomic extent of the eye-brain mechanism and the magnitude of the head injury problem, the incidence and variety of the neuro-ophthalmic signs and symptoms of head injuries become mind boggling. What can the neuro-ophthalmic aspect of head injuries provide in terms of patient evaluation and care?

In the initial evaluation of any head injury victim, a thorough neuro-ophthalmic examination will provide important clues to localization of sites of trauma, whether they are primary or secondary, direct or remote effects. Analysis of this information will facilitate diagnosis and prompt, proper therapy can be instituted. Despite these efforts, however, a number of neuro-ophthalmic sequelae of head injury will remain for the patient to recognize as he recovers from more serious aspects of the head injury. Many of the neuro-ophthalmic symptoms and signs demonstrated go beyond simple signposts in directing diagnostic considerations, investigations, and therapeutic endeavor. They serve a significant role in prognostication of the patient's course and residual neurologic and neuro-ophthalmic handicap. The neuro-ophthalmic evaluation must not be limited to the initial patient evaluation which may be not only remarkably hectic but may also be restricted by aspects of the trauma that either prevent adequate evaluation or are of such a nature that they are life-threatening and preclude neuro-ophthalmic evaluation. The neuro-ophthalmic examination should be repeated at clinically appropriate points during the hospital course and should be utilized as a monitor for following the patient's long-term progress.

The value of the neuro-ophthalmic aspects of trauma are not restricted to the primary care of the

* Presented by Dr. Harbison at the 27th Annual Stoneburner Lecture Series, February 8, 1974, at the Medical College of Virginia, Richmond.

patient. Suitable documentation of the neuro-ophthalmic examination can be utilized during the primary patient care and follow-up as a tool in achieving a better understanding of the basic mechanisms of brain injury. During recent years at the Medical College of Virginia, close cooperation between neurosurgery and neuro-ophthalmology has provided the opportunity to implement this concept. We are presently compiling data, helpful not only in primary patient care but also in understanding the basic mechanism of brain injury.

The broad extent of the neuro-ophthalmic aspects of brain injury has been emphasized but space prohibits comprehensive discussion of its full range. An attempt, therefore, will be made to illustrate selected aspects of the neuro-ophthalmic consequence of brain injury which may be both of interest and benefit.

An appropriate beginning to the discussion of neuro-ophthalmic consequences of trauma is the consideration of the concept of preexisting brain disease as a precursor to trauma. Eyster clearly explained that minor head trauma in the presence of basal intracranial tumors may well produce unexpected neuro-ophthalmic signs of an oculomotor nature. Other neuro-ophthalmic signs can be produced by trauma and appropriately situated tumors. It is also clear that previously undiagnosed intracranial pathology may increase a patient's vulnerability to traumatic incidents. In a similar vein preexisting signs of a neuro-ophthalmic nature, either recognized or unknown, though unrelated and clearly independent of the traumatic incident, may cause significant diagnostic consternation.

In introducing the topic, neuro-ophthalmology of severe head injury, it was noted that perhaps the most commonly sought neuro-ophthalmic sign of trauma was a pupillary abnormality. The abnormality most feared is the Hutchinson pupil—the dilation of the pupil ipsilateral to a mass lesion, producing transtentorial uncus herniation with third nerve impingement. It is generally an evolving sign, although it may be present by the time of the patient's initial medical attention. Because of its sinister import, it must be differentiated from a similar pupillary abnormality—traumatic mydriasis.

Patients with severe head injuries also frequently receive direct blows to the eye. With direct blows to the globe, contusion of the iris may occur which results in a dilated and fixed pupil, usually unilaterally. If seen early, the initial response to the contusion

will be miosis; dilation and iridoplegia follow within minutes, however, and may last minutes, hours, days, or may be permanent. Often other signs of periorbital trauma will point to the correct diagnosis of traumatic mydriasis. In selected cases, however, it may be impossible to differentiate a Hutchinson pupil from traumatic mydriasis. In these situations investigations to rule out the transtentorial herniation syndrome are imperative.

Oculomotor nerve palsies in head trauma are common; they are also significant parameters for localization and valuable monitors of the evolution of the trauma patient's course. Their diagnosis is most difficult in the comatose patient. In this situation, the third nerve paralysis is most easily recognizable, basically, because of the prominent features of ptosis, mydriasis, and generally prominent deviation of the eye downward and outward. Sixth nerve palsies are less readily documented and fourth nerve palsies are almost never recognizable in the presence of coma. The oculomotor evaluation in comatose patients, however, is facilitated with the use of doll's head phenomenon and caloric responses. Differentiation of primary and secondary palsies is of great practical significance to the physician responsible for the care of the trauma patient. Oculomotor palsies, as primary traumatic injuries, are almost always present immediately. Secondary palsies, reflecting an evolving intracranial mass, generally occur many minutes to hours or days later. If the trauma patient is delayed in receiving medical attention, or if the initial examination is incomplete, this differentiation may not be possible.

Clearly, early and accurate evaluation and documentation of ocular motility, as well as its continued monitoring during the patient's recovery, is important. The ophthalmologist, who must commonly deal with the motility disturbance at a time distant from the injury, may be extremely dependent upon this documentation for his analysis and decision regarding surgery of the paretic muscle. It is currently recommended that surgery on paretic muscles be performed at any point after the fourth month, *if* maximal improvement has occurred. Statistics on the incidence of oculomotor involvement in trauma are less reliable than is desirable, due largely to misdiagnosis. Involvement of the third and sixth cranial nerves is probably nearly equally common. Fourth nerve injury is distinctly less common.

Third cranial nerve palsies are the result of significant frontal injuries generally associated with

concussion and skull fracture; they may be isolated sequelae of trauma. The site of third nerve injury is probably at its point of dural penetration at the posterior aspect of the cavernous sinus. The mechanism of injury is probably by virtue of shearing and stretching forces exerted upon the nerve with movement of the brainstem and skull base. Traumatic third nerve palsy is almost always unilateral, bilateral involvement being so rare as to suggest an additional pathologic process. Aberrant reinnervation is common in traumatic third nerve palsy and generally becomes evident at two-to-three months after injury. Lid and pupil signs are easily recognized.

Although fourth nerve palsy is less common than third and sixth nerve injury, it is by no means rare. It is easily missed. Fourth nerve involvement is often bilateral. Usually, it is the result of a vertex or frontal blow in which the dorsal midbrain and anterior medullary velum are contused on the tentorium. Motorcycle accidents are the common inciting event and permanent dysfunction is not uncommon.

Sixth nerve palsies commonly occur with frontal blows; they may be bilateral and, if the mode of onset is unknown or not documented, it may be impossible to differentiate direct injury of the sixth nerve from the secondary effects of increased intracranial pressure. Injuries producing sixth nerve paralysis may be based upon the presence of petrous ridge fractures. In this circumstance, associated paralysis of the seventh and eighth cranial nerve is common.

Injuries producing fractures of the superior orbital fissure frequently result in combined involvements of the third, fourth, and sixth cranial nerve. Such injuries have associated optic nerve injury and visual loss 50% of the time. Trigeminal and facial nerve injury occur an additional 25% of the time.

Frontal and superior orbital fractures may be associated with ptosis and elevator palsy due to paresis of the superior rectus. Although this is the superior division of the third nerve, it indicates involvement at a different site—within the orbit. Associated involvement of the superior oblique as well as the optic nerve may occur.

Also to be distinguished from true third nerve injury is the elevator palsy caused by the incarceration of the inferior rectus in "trapdoor" fractures of the orbital floor. This, as part of the orbital blow-out fracture syndrome, is usually associated with

enophthalmos and sensory loss in the distribution of the inferior orbital nerve.

Supra- and internuclear ophthalmoplegia, from brainstem contusion on the free edge of the tentorium or from other less clear mechanisms, may be confused with partial third nerve injury. Their characteristic appearance and a knowledge that they may occur will usually avoid confusion.

The presence of a congenital Duane's retraction syndrome may cause confusion by its resemblance to a traumatic sixth nerve injury. Past history and the characteristic refraction of the globe with associated narrowing of the palpebral fissure on adduction will usually assist in the distinction. In a comatose patient, differentiation may not be possible.

The presence of obvious evidence of local orbital injury will generally suffice to distinguish oculomotor palsies of myogenic origin based upon local hemorrhage, contusion, and laceration of muscle. Obviously they may coexist with nerve injuries and their separation may be impossible.

Finally, one must recognize that skew deviation and wandering, dysconjugate eye movements are common in the coma of concussion. They are felt to represent disruption of oculomotor integration by the same mechanism responsible for the alteration of consciousness—physiologic alteration of the reticular formation. With return of consciousness, oculomotor function also returns to normal.

That blindness—visual loss—is a common result of head injury, is reflected in a quotation attributed to Hippocrates: "Dimness of vision occurs in injuries to the brow and in those placed slightly above." Visual loss can occur at any point in the visual pathways. It is most commonly encountered, if we exclude the eye itself, at the beginning and end of the intracranial pathways—the optic nerve and the occipital cortex. The differentiation of optic nerve and cortical blindness is seldom a problem. The exact definition of the mechanism of visual loss in both may be difficult yet extremely important.

The mechanism of optic nerve injury is varied. Generally, the blow is severe but may be extremely mild. The site of injury is most frequently the optic foramen, with involvement of contiguous orbital and intracranial optic nerve. Despite this localization, x-rays are seldom helpful. If visual loss is immediate and severe, the mechanism is likely to have been tearing, nerve hemorrhage, or contusion necrosis. If the onset has been delayed minutes-to-hours, hemorrhage into the vaginal sheaths, secondary

edema or vascular compromise may be responsible. It is important to separate these two presentations since delayed visual loss may indicate a situation reversible by decompressive surgery. Immediate visual loss is virtually never remediable by surgical decompression. Unfortunately, the time of onset of visual impairment is frequently clouded by unconsciousness. Spontaneous recovery, if it is to occur, usually will do so in a few days. Significant residual is the rule.

Another mechanism of optic nerve and chiasm involvement in trauma is the compression of the nerve and chiasm against the sphenoid bone by the posterior orbital convolutions. The gyri recti may actually shift into the anterior chiasmal angle. Resulting visual loss with central scotomas or bitemporal field defects may not be recognized by virtue of altered consciousness. This syndrome is frequently associated with diabetes insipidus.

Cortical blindness results basically from two mechanisms—direct injury to the occipital cortex and infarction secondary to vascular compromise by the transtentorial herniation syndrome. Cortical blindness is a frequent result of a direct blow to the occiput. The resulting blindness is seldom permanent and usually resolves in minutes, hours, or days. Although recovery is often complete, residual visual field defects may occur. When they do, they are homonymous and frequently consist of congruous paracentral scotomas.

While compression of the third nerve is well recognized in transtentorial herniation of the medial temporal lobe with asymmetric supratentorial traumatic mass effects, compression or “pinching” of the posterior cerebral arteries with infarction of calcarine cortex is not. The resultant homonymous hemianopsia or cortical blindness is infrequently recognized because, again, there is usually coma. If the homonymous defect is recognized, it is of lateralizing value as it almost always occurs on the side of the mass effect. Most commonly, they are first recognized if and when the patient recovers.

The funduscopic examination in patients with severe head injuries may reveal pathology of diagnostic value. Several factors enhance the examiner's opportunity to obtain a satisfactory and relatively complete evaluation of the patient's fundus. Pupillary dilation may make the difference between an adequate exam and complete failure to visualize the fundus. Obviously, the decision to dilate the pupil of a head-injured patient must not be taken lightly and will depend upon a variety of factors. With the

utilization of modern methods of evaluation and intracranial monitoring, an appropriate dilated examination is more feasible. It remains imperative to note on the patient's bed and chart what has been done and when. Another invaluable factor is adequate illumination—a bright light.

Papilledema, previously felt to be relatively uncommon in closed head injury, may occur far more frequently than suspected in a mild form lasting several days. Occasionally, hidden globe perforation may occur, resulting in hypotony—low intraocular tension. This may produce disc edema. The syndrome will be unilateral.

The appearance of preretinal hemorrhages in the fundus of a head-injured adult usually reflects a severe head injury with significant subarachnoid blood. The presence of a hemorrhagic retinopathy with prominent preretinal hemorrhages in an infant suggests several possible causes, the most prominent of which is the presence of subdural hematomas. It has been estimated that one-half of infants with subdural hematomas have intraocular hemorrhages. Their significance is that they are relatively unrelated to the severity of the infant's presenting symptoms. The child may appear only mildly ill yet harbor subdurals. The association of subdurals with the battered baby syndrome gives the fundus picture of preretinal hemorrhages added significance. The severity of the preretinal hemorrhages is highly variable; severe hemorrhage is common, however, and on occasion may fill the vitreous. Their presence is generally bilateral. The prognosis is also variable. In extreme cases, fibrosis may occur with traction and retinal detachment. They most frequently clear without significant residual.

Comotio retinae or retinal contusion results from severe direct blows to the globe itself. Abrupt rises in intraocular pressure occur, with distortion and shearing forces affecting intraocular structures. The resulting contusion necrosis with cloudy gray swelling, usually affecting the maculae and posterior pole, generally culminates in severe permanent visual impairment.

Many patients with severe head injuries suffer additional trauma to other parts of the body. Specific types of injuries result in characteristic retinal pictures.

In compression or crushing chest injuries, the resulting increased intravascular pressure is transmitted to the eye producing a specific fundus picture—Purtscher's retinopathy or traumatic retinal

angiopathy. This consists of multiple superficial cotton-wool spots, of one disc diameter or less in size, generally located in the posterior pole between arterioles and veins. Associated retinal and preretinal hemorrhages are the rule. Initial visual impairment is variable but usually significant. The fundus picture may be delayed two-to-three days. The course is usually one of progressive return to normal over weeks to several months.

The occurrence of retinal fat emboli in fractures of long bones is frequently overlooked since the patients are either comatose or have no visual symptoms. The retinal picture consists of several small cotton-wool exudates, usually but not invariably,

fringed by hemorrhage as well as additional retinal hemorrhages which usually occur in the posterior pole but seldom affect vision. The presence of the better known aspects of fat embolization should facilitate their recognition.

In closing, a single classic and nearly diagnostic external neuro-ophthalmic sign in head injury might be mentioned. This is the so-called "panda sign" of bilateral orbital ecchymosis restricted by the palpebral fascia to the orbital margin resulting in its nearly circular configuration. Its characteristic purplish color and commonly delayed appearance of two-to-three days are strong evidence of an anterior cranial fossa fracture.

Advances in Neuroradiology*

FREDERICK S. VINES, M.D.

*Associate Professor of Radiology and Neurology;
Chief, Section of Neuroradiology, Medical College of Virginia,
Health Sciences Division of Virginia Commonwealth University, Richmond*

CHARLES BONSTELLE, M.D.

*Assistant Professor of Radiology, Medical College of Virginia,
Health Sciences Division of Virginia Commonwealth University, Richmond*

The development of two new radiological techniques has significantly enhanced the performance of neuroradiological diagnostic procedures. The first of these was installed as the prototype unit at the Medical College of Virginia in November of 1972 and has marked advantages for the performance of encephalography, angiography, and air myelography. The present communication will relate the experiences of the author during the initial 15 months of clinical evaluation. The second technique is an entirely new concept of obtaining further information from the data provided by the penetration of x-ray photons. Each of these units will be discussed briefly with an outline of the principle indications and advantages of each system.

An Isocentric Diagnostic System. The principle feature of this system is a fully isocentric unit (Omnitome†) maintaining the head in alignment for filming or fluoroscopy, regardless of the patient's position during 480° of continuous rotation (Fig. 1). A C-arm rotates 300° about the isocenter. The L-arm provides 270° of rotation parallel to the wall axis with consequent alteration in the site of rotation of

the C-arm. This unit was designed primarily for pneumoencephalography and enables one to obtain standard film series as well as Grossman tomography in the frontal or lateral views, as indicated, regardless of the patient's position. A unique feature is the ability to perform tomography at varying angles of incidence (Fig. 1-B). The brain stem may be tomographed coronally, therefore, relative to its vertical alignment and areas such as the temporal horns or corpus collosum may be viewed perpendicularly to their long axis without movement of the head and subsequent alteration in the position of the contrast material. There is lateral, longitudinal, and vertical adjustment of the chair relative to the isocenter, so that once the isocenter has been established, the patient may be moved to readjust as necessary throughout the procedure. An image intensifier and television system are incorporated into the C-arm, allowing constant fluoroscopy regardless of the patient's position. The Omnitome system is also equipped with a phototimed 105 mm camera providing for either single or multiple frame, up to 12 per second, with fluoroscopic control. The unit may be operated from the remote control panel or a mobile hand control may be utilized with closer observation of the patient. Television monitors are available in the control booth and adjacent to the patient. The usual encephalogram includes standard

* Presented by Dr. Vines at the 27th Annual Stoneburner Lecture Series, February 8, 1974, at the Medical College of Virginia, Richmond.

† General Electric Corporation, Medical Systems Division, Milwaukee, Wisconsin.

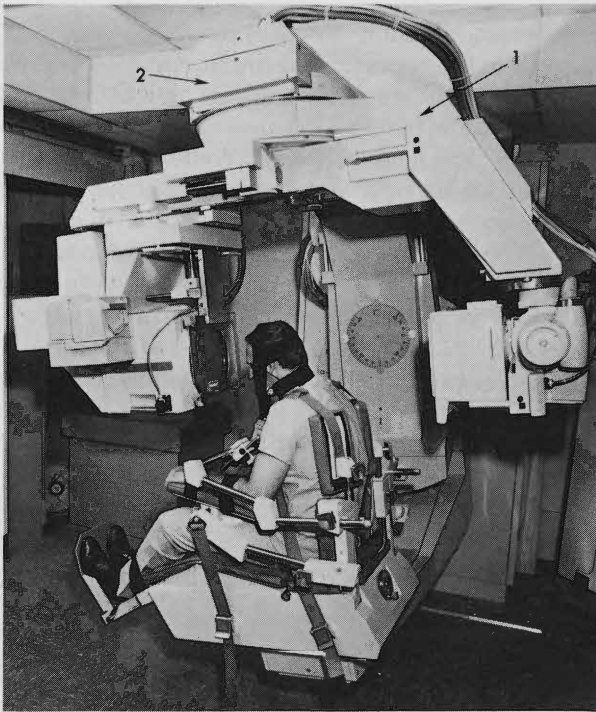


Fig. 1A.

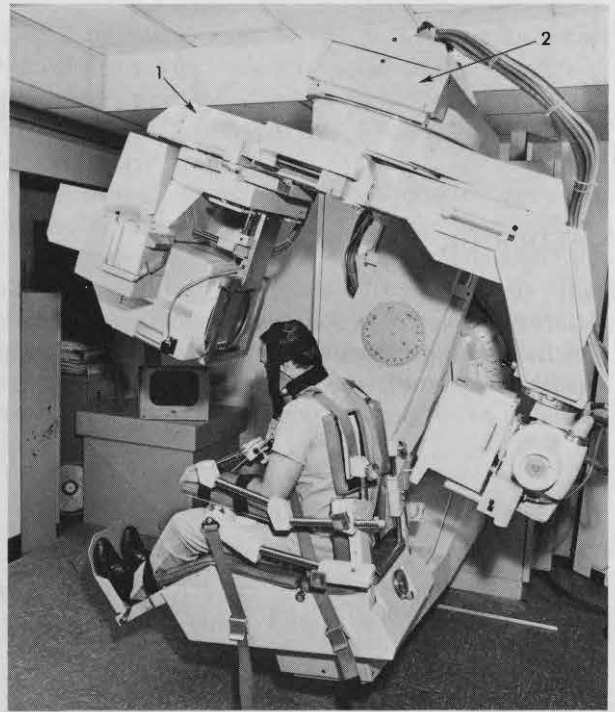


Fig. 1B.

Fig. 1—Omnitome-C-arm-1; L-arm-2 A. Patient positioned for erect frontal views. B. Position for erect frontal view with L-arm angled. C. Prone, A-P view. D. Normal lateral encephalogram tomogram. E. Coronal tomogram of right acoustic neuroma. Fourth ventricle (4) compressed and rotated. F. Coronal tomogram 1 cm anterior to E with mass adjacent to pons.

films in the erect and supine position with the remainder of the film series obtained on the photospot camera. This enables one to obtain multiple different projections and angulations with a significant reduction in the time required to perform

the study. Both filming and positioning are done with fluoroscopy, obviating the time required for changing film cassettes.

An accessory table is utilized for air myelography on the Omnitome (Fig. 2). The technique

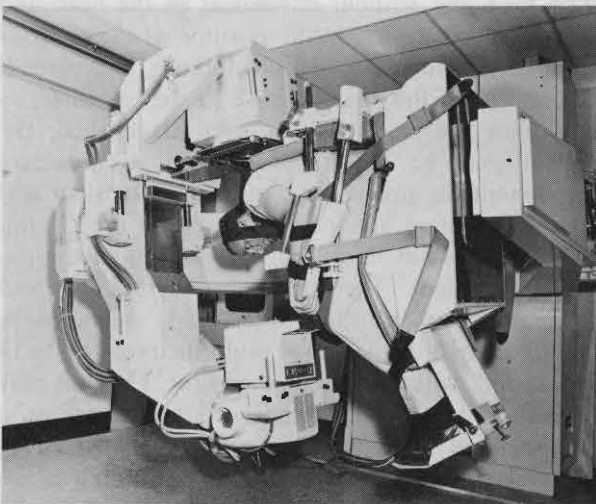


Fig. 1C.

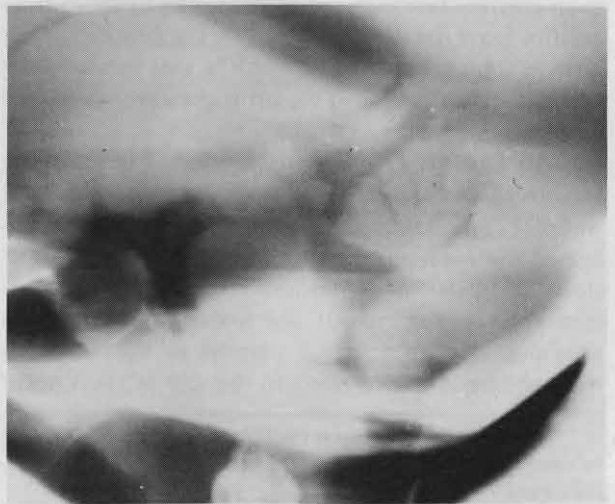

Fig. 1D.

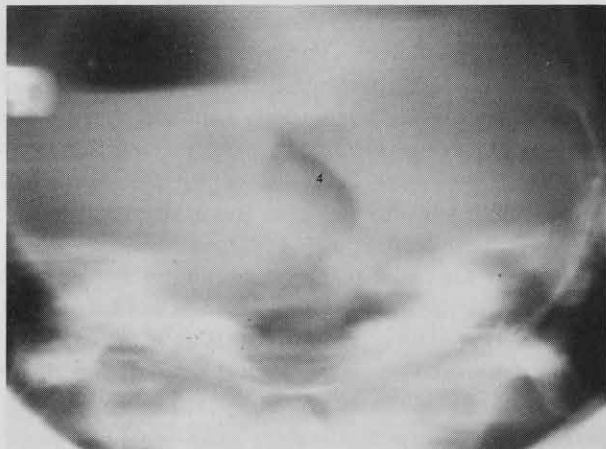

Fig. 1E.

emphasized by Heinz (1) has been used primarily for study of the cervical spine. This technique is usually utilized for patients with cervical fractures or cervical spondylosis. Unstable cervical spine fractures are ideally suited for this study, allowing one to maintain adequate skeletal fixation with the patient supine. Degenerative disease of the cervical spine is also well studied by this method, since the surfaces of the spinal cord can be evaluated with tomography as well as the ventral defects associated with degenerative cervical discs. A lateral puncture of the subarachnoid space is quite easily performed under fluoroscopic control at the C1-2 interspace. Filling of the entire subarachnoid space is obtained with the patient supine and in 20° Trendelenberg position.

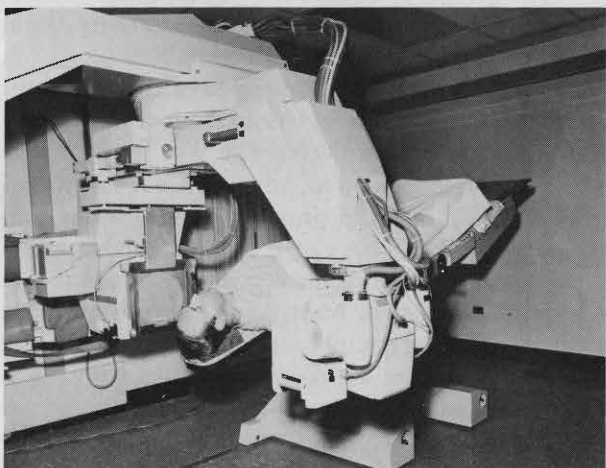


Fig. 2A—Patient positioned for air myelogram in 20° Trendelenberg.

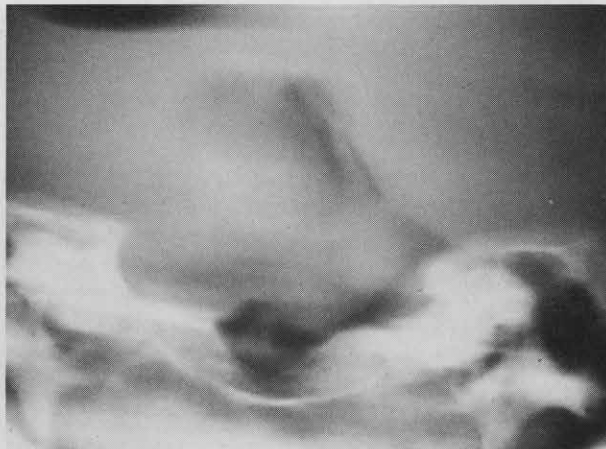

Fig. 1F.

The accessory table is also utilized for angiographic procedures, with the C-arm providing fluoroscopic versatility (Fig. 2-C). Vertical height adjustment of the table of 50 cm is available for magnification studies. The table top may be motor driven or converted into a free-floating surface with a foot switch. Adequate distance is available for femoral catheterization. Filming may be obtained on the 105 mm camera or with standard film changers. The 105 mm camera again is quite beneficial, providing the capability of a “see-through” changer with rapid serial filming available at all times during fluoroscopy. The ability is also preserved to perform multiple complex angle views rapidly. A second tube may be positioned on a floor pedestal for bi-plane filming if desired.

The indications for angiography on this unit are necessarily determined by the availability of other angiographic facilities. The principle advantage of angiography on the Omnitome is the 105 mm camera,

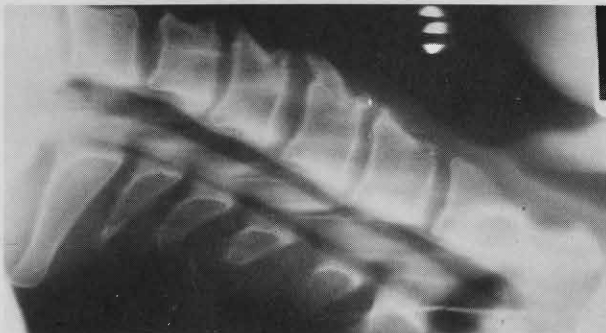


Fig. 2B—Normal lateral tomogram.

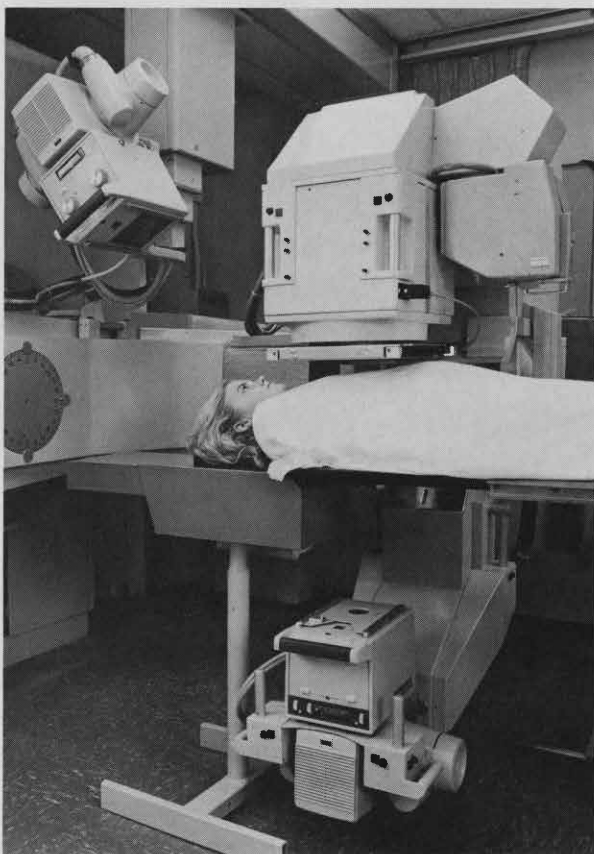


Fig. 2C—Positioning for angiography for serial film changers cephalad to patient.

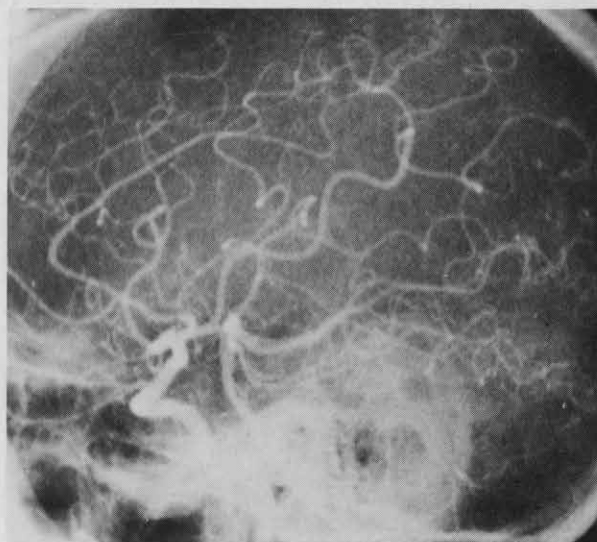


Fig. 2D—Right brachial injection (105 mm).

and therefore, cases are chosen where this would be of significant benefit. Patients studied for spontaneous subarachnoid hemorrhage or extracranial vascular disease are particularly suitable as are those patients requiring selective spinal cord angiography. Multiple views may be obtained with a significant reduction in time to perform the study and consequent reduction in patient discomfort and complications. The possibility of obtaining a standard film series in the optimal projection is available after preliminary study with the 105 mm camera. Angiotomography is also available as an ancillary procedure, since the C-arm maintains its ability to perform tomography wherever positioned.

Supplementary benefits of this system are multiple. One may obtain standard views of the skull or cervical spine utilizing the orbiting system and fluoroscopic centering. Obviously procedures requiring bi-plane fluoroscopy such as ventriculography, orbitography, or cerebral biopsies are simplified with this facility.

Computerized Axial Tomography. The second portion of this discussion will involve a new technique that has been variously compared with the discovery of penicillin or the first use of contrast material to complement standard radiographic techniques. Radiologists have long recognized that less than 10% of the information available on standard radiographs is actually interpreted by the physician. This new technique utilized computer analysis of the x-ray photon transmission, making it possible to analyze physical properties of normal cerebral tissues and a wide variety of pathological lesions.

The prototype equipment was installed in 1971, the first clinical reports appearing in 1972 by James Ambrose at the British Institute of Radiology (2). Since his initial reports, others have confirmed the importance of this unit and its acceptance throughout the world has been universal (3).

The patient lies on an adjustable couch with his head enclosed in a cap projecting into a water contained box (Fig. 3-A). He is comfortable, fully dressed, and no additional contrast materials are necessary. A slit x-ray beam scans the head using the sodium iodide crystal photomultiplier to detect the photons. The detectors move in parallel with the x-ray tube across the patient's head with 160 readings of photon transmission during each horizontal movement (Fig. 3-B). The entire frame then rotates one degree and the horizontal movement is repeated. For each parallel movement of the unit, therefore, 28,800

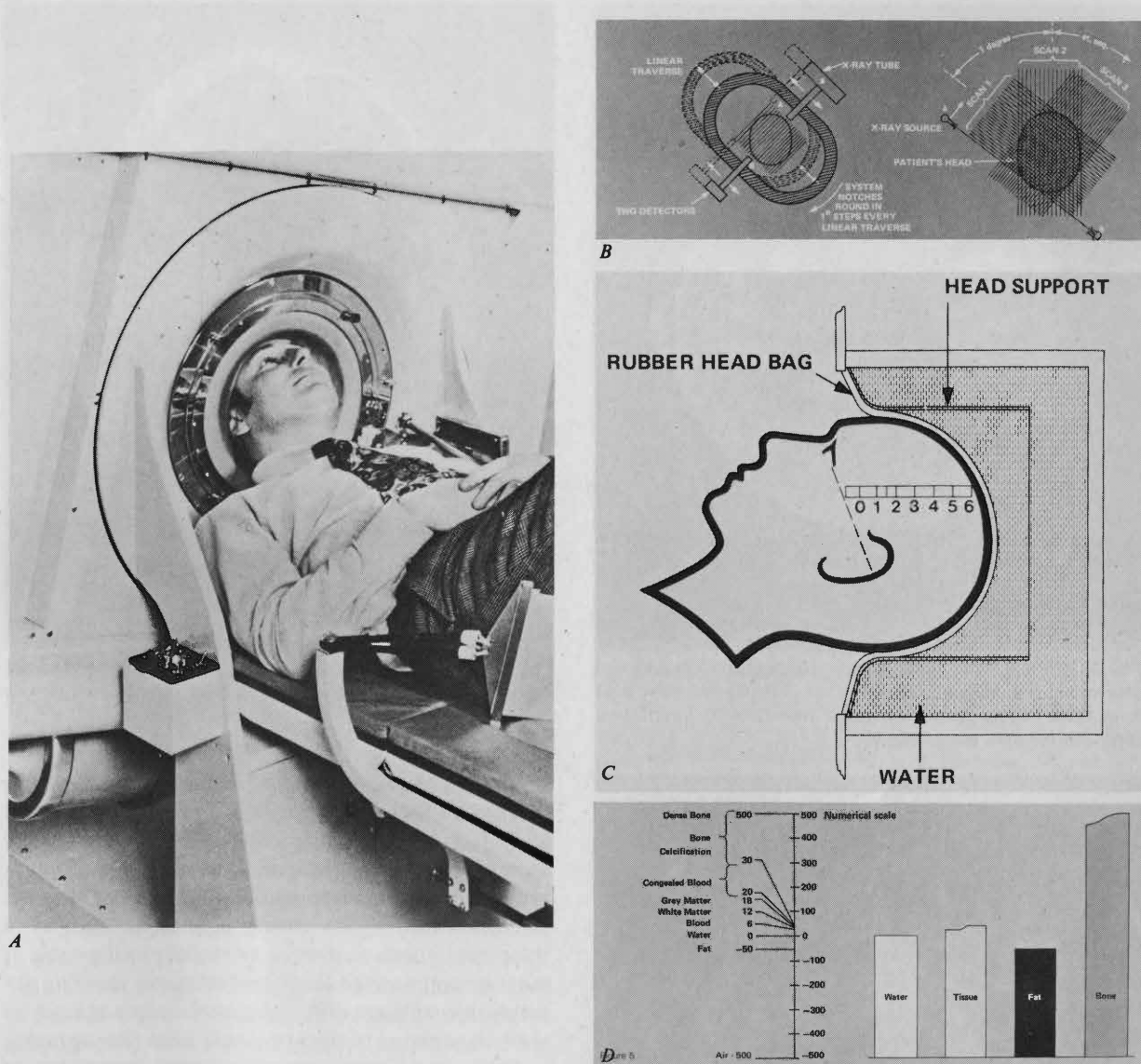


Fig. 3—A. The EMI scanner. B. Rotation sequence of scanning unit. C. Patient positioned for tomograms to include orbits and posterior fossa. D. Arbitrary scale of absorption values with air as -500 and water as 0.

absorption readings are obtained, which the computer can analyze within five-to-ten minutes. Routinely three or four axial sections are obtained with two scans of each slice. The head may be rotated to include the posterior fossa on the caudal scans if clinically indicated (Fig. 3-C). These are normally 13 mm by 2.94 mm by 2.94 mm, but an 8 mm collimator may be used if desired.

The data may be stored in two forms for recall when desired. A paper printout is available with numerical values of the relative absorption

coefficients. There is also a cathode ray tube display of the information in an 80 by 80 matrix form. A Polaroid® camera is used for photographic records of the cathode ray tube display.

The absorption values are a normal function of the physical density and the atomic numbers of the tissue analyzed. The relative absorption values are illustrated in Figure 3-D. Water is used as a reference (i.e., water = 0) and the scale of relative percentage of absorption of intracranial tissues is expanded several times for convenience. Utilizing a gray scale picture

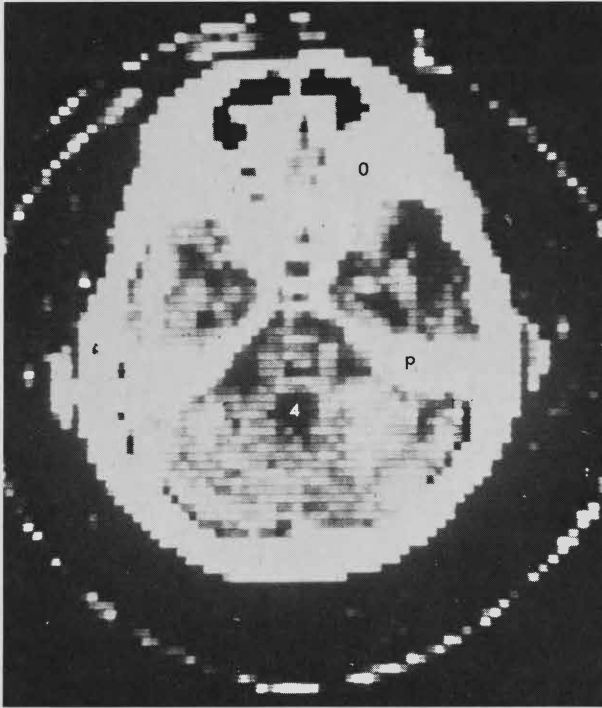


Fig. 4—Normal axial tomograms beginning caudally (A) and progressing superiorly. A. Caudal section. Broad white outer zone is the skull. Petrous temporal bone (p) and orbits (0). Fourth ventricle is black area posteriorly (4).

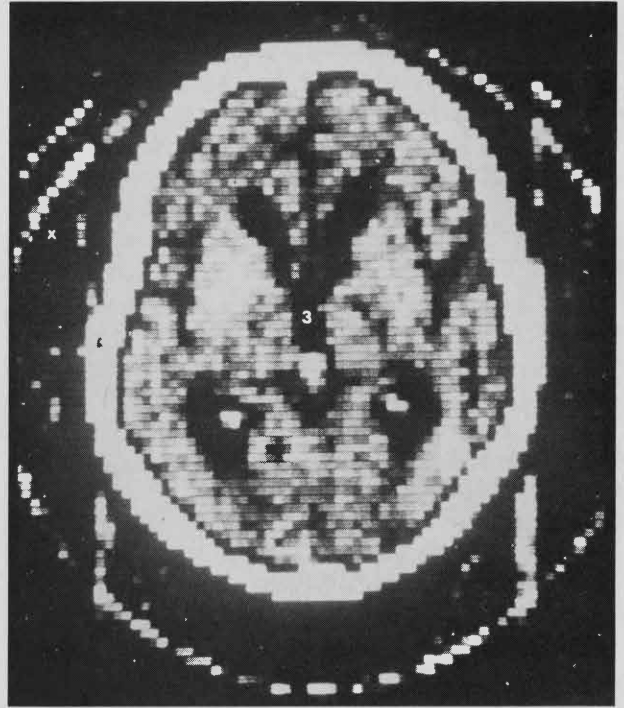


Fig. 4C—Frontal horns, third ventricle (1), and trigone of lateral ventricles. Pineal calcification behind third ventricle and glomus calcifications in trigone.

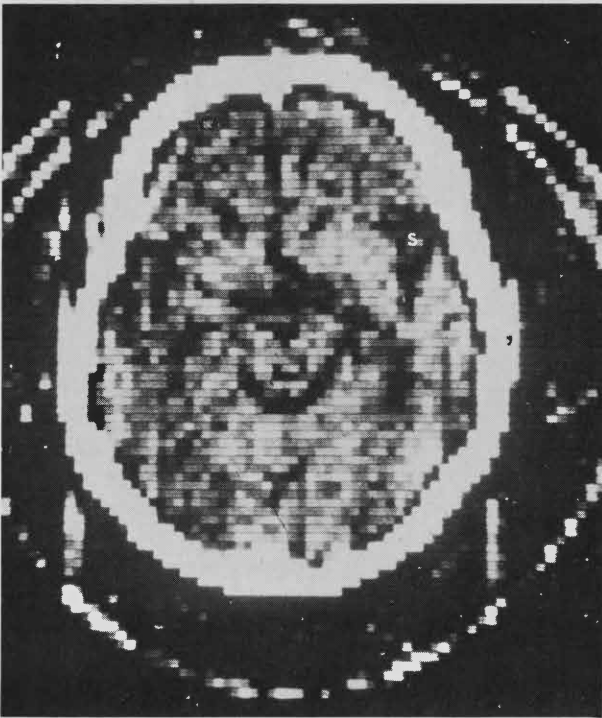


Fig. 4B—Ambient, interpeduncular and sylvian (s) cisterns.

of each tomographic section, water density would be black with increasing grayness-to-white at the bone level. It can be seen that water density is adequately separate and allows the basal cisterns and ventricular system to be visualized with ease (Fig. 4). Likewise, calcifications are very clearly delineated, such as in the pineal gland or glomus of the choroid plexus. It must be emphasized that this technique utilizing absorption coefficient differences and computer analysis is much superior to the previously used photographic methods and computer enhancement processing of photographic images. Preliminary data indicate that all of the cerebral tissue, cerebrospinal fluid, and coagulated blood are very easily distinguished. The matrix actually allows for analysis of individual 3 mm lesions at any point of each tomogram.

The preliminary results obtained in this country have confirmed the reasons for the rapid acceptance of this dramatic new technique. The most striking pathological change is with an intracerebral hematoma (Fig. 5-A). The clotted blood is quite easily seen, with its absorption coefficient in the 20 to 30 range, and extension into the ventricles or the cortex is easily delineated. Cerebral infarcts must be

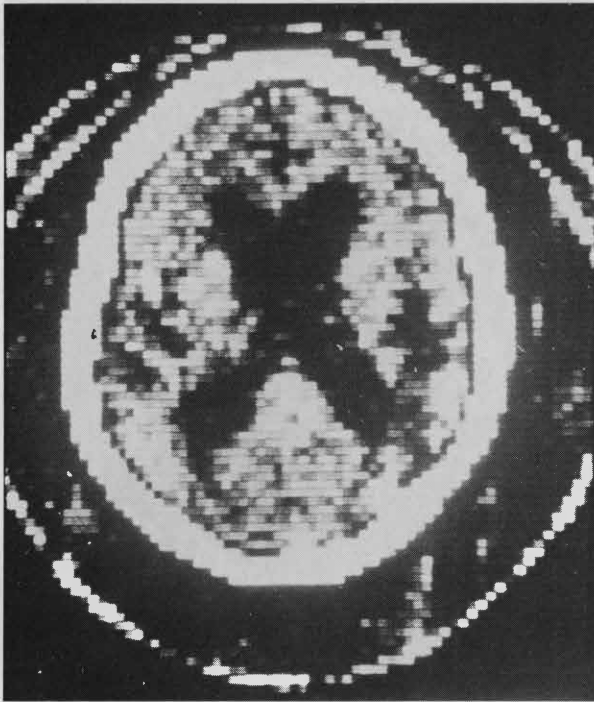


Fig. 4D—Lateral ventricles.

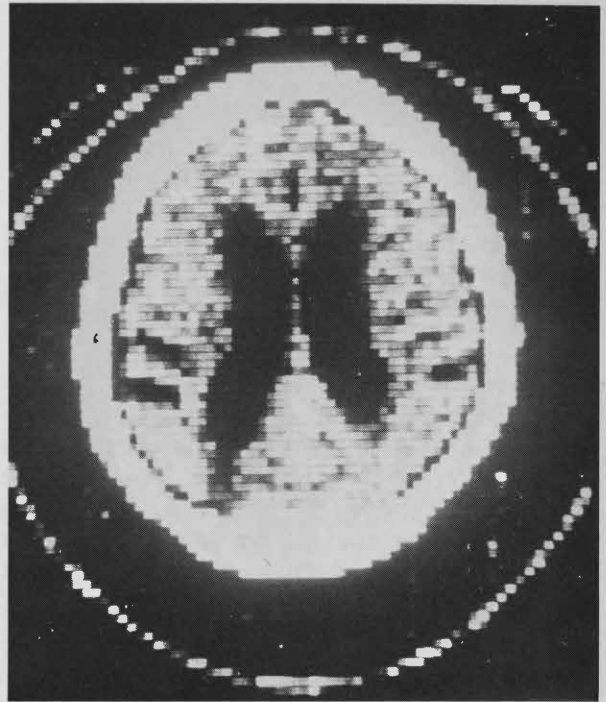


Fig. 4E—Lateral ventricles.

differentiated during their various pathological stages. The early lesion may be patchy with decreased absorption and much larger definition occurring in seven-to-ten days as the necrotic area becomes sharply defined with the onset of phagocytosis.

Gliomas are highly variable not only from case to case, but in different parts of the same tumor (Fig. 5-B). Cystic areas within the neoplasm may be seen by the decreased absorption with areas of more dense and compact tumor delineated by an increased absorption value. More importantly, one is able to evaluate deep infiltration of a portion of tumor into the critical deeper structures.

Metastatic neoplasms tend to be more circumscribed than the primary gliomas (Fig. 5-C). The center may be necrotic and cavitated with a decreased absorption or may be dense and compact with a large surrounding area of cerebral edema and consequently with decreased absorption.

The development of this procedure has significantly altered the evaluation of patients with cerebral dysfunction. One is now able to selectively choose which patients will require the more invasive but precise technique of pneumoencephalography

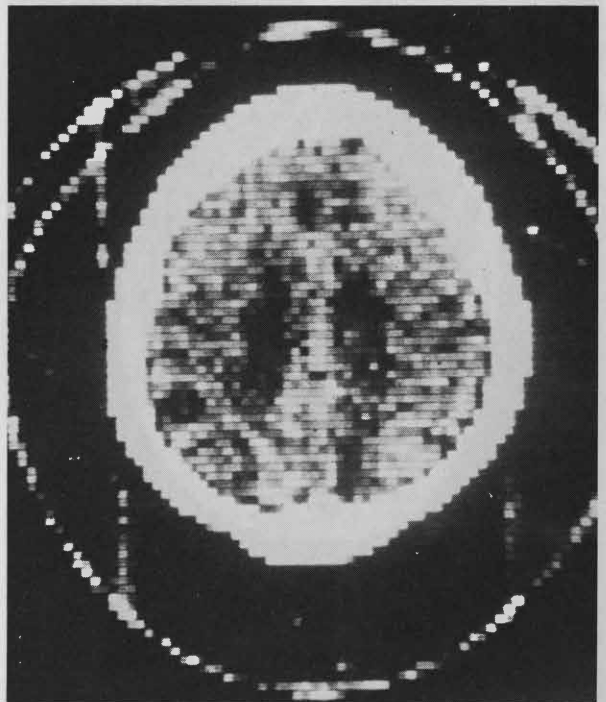


Fig. 4F—Cortical sulci.

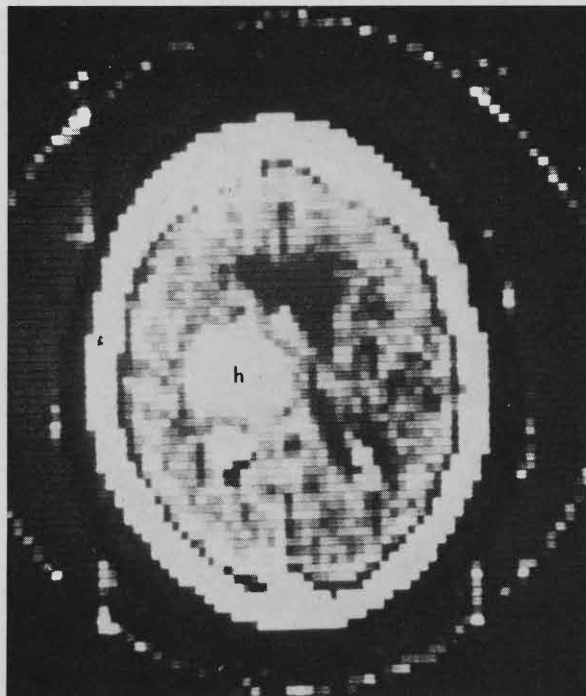


Fig. 5A—Left thalamic hemorrhage (h) with frontal horn compression and shift.

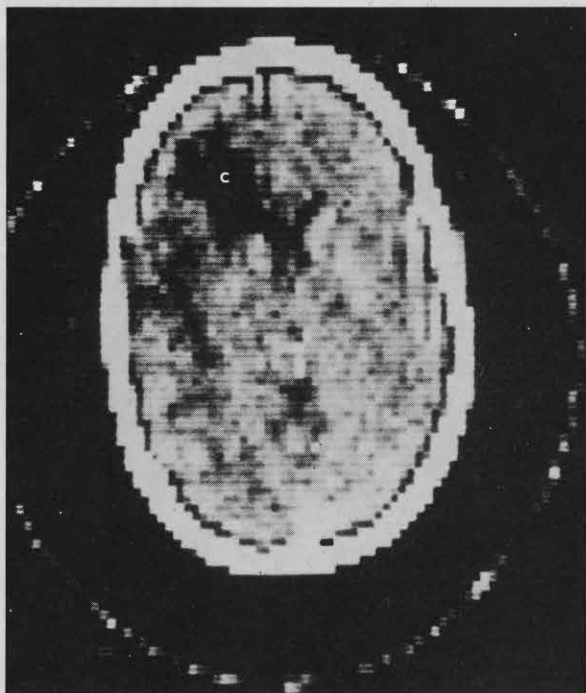


Fig. 5B—Left frontal astrocytoma extending deep into basal ganglia. A large cyst (c) is also present.

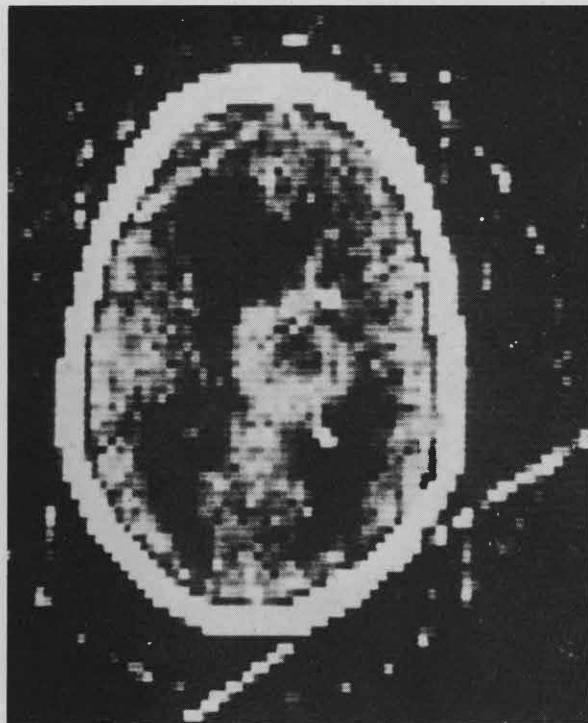

Fig. 5C—Deep right thalamic metastases with a cavitated center.

and angiography. There will also be fewer negative results with these studies. The tomographic study enhances other techniques and will enable isotope brain scanning techniques to become more specific with the development of tissue specific radionuclides. The results from one center (3) indicate that of the first hundred patients that underwent computer assisted tomography, 71 of them required one or more neuroradiological procedures for diagnosis. In the fifth group of 100, however, only 34 required further study.

The expertise required to interpret this tomographic study is somewhat more than one would anticipate. One must not only interpret the pathophysiological data, but he must also know the associated features and types of mass effect created by different lesions. He must understand not only the occurrence of a glioma but its typical pattern and course of infiltration as well as the types of cerebral infarction and their sequential pathological development in time. He must also know what pathological conditions are associated with cerebral edema or necrosis, and how this may modify the absorption values. Likewise, the initial feeling that differentiation of the gray and white matter could be attained

with ease has been less commonly observed in practice. The technical limitations in the evaluation of the base of the skull and particularly the cerebellopontine angles has been less impressive. Most investigators, however, have now shown that with care this area can be seen with certain limitations. Extracerebral hematomas were also considered to be a significant problem with the use of this unit. Extradural hematomas with their larger portion of congealed blood have easily been seen; however, subdural hematomas have varied considerably and require care of the observer in interpreting the results. Since the hematoma may be totally liquid and therefore of water density, the absorption may be considerably different from a hematoma that is mixed in character or contains more clotted blood and is more dense than the surrounding cortex. Frequently there is also adjacent cerebral edema which limits the exact differentiation between the borders of the hematoma and the cortex. Even with this limitation, however, it is considered that with careful evaluation of the edges of the lesion, the hematoma may be ascertained with a high degree of accuracy. Even if the hematoma is not delineated fully, the shift of the ventricular system and cerebral structures is quite easily seen and accurately indicates a source of the cerebral dysfunction.

There is no question that the avenues for research and further investigation available through this technique are unlimited. Most importantly it is a functional and clinically useful tool that can be performed safely on inpatients or outpatients with no morbidity. The procedure may be conducted by an experienced neurotechnologist after a short period of familiarization with the method and equipment. The limitations of this technique are negligible in view of its outstanding advantages. There is clear indication

that there will be a significant reduction in the number of pneumoencephalograms, and in select cases, angiography will also be omitted from the diagnostic evaluation. Carotid angiography will no longer be necessary to evaluate an intracerebral hematoma or hydrocephalus. Radionuclide brain scanning will have a limited place in the diagnostic evaluation. These are immediate benefits and only the future will ascertain the long-term alterations in the evaluation of patients with disease of the central nervous system.

Acknowledgments: I would like to express my appreciation to Kenneth R. Davis, M.D., Massachusetts General Hospital, Boston, Massachusetts for permission to reproduce Figures 5 and 6 and to Emitronics, Inc., Reston, Virginia for permission to use Figure 4. Figures 1 and 2 are reproduced by permission of the author and publisher (5).

REFERENCES

1. HEINZ ER, GOLDMAN RL: The role of gas myelography in neuroradiologic diagnoses. *Radiology* 102:629, 1972.
2. AMBROSE J, HOUNSFIELD G: Computerized transverse axial tomography. *Br J Radiol* 46:148, 1973.
3. BAKER AL JR, CAMPBELL JK, HOUSER OW, REESE DF, HOLMAN CB: Computer assisted tomography of the head. *Mayo Clin Proc* 49:17, 1974.
4. NEW PFJ, SCOTT WR, SCHNEW JA, DAVIS KR, TAVERAS J: Computerized axial tomography with the EMI scanner. *Radiology* 110:109, 1974.
5. VINES FS: An integrated isocentric system for neuroradiology. *Am J Roentgenol* (in press).

Advances in the Management of Pituitary Tumors*

CHARLES B. WILSON, M.D.

*Professor and Chairman, Department of Neurosurgery,
University of California, San Francisco*

A new development in the management of pituitary tumors is the transsphenoidal technique. It will be my purpose to show that it provides an elegant way of handling the great majority of pituitary problems, at least the ones that I have encountered, although it has its shortcomings as well as its advantages.

Pituitary tumors manifest themselves in two ways—by compressing structures in the neighborhood, primarily the optic nerves and chiasm and by the two endocrine manifestations, one being the compression of the normal pituitary gland to produce varying degrees of hypopituitarism and the other, the hyperfunctioning adenoma. A large tumor with a suprasellar extension compresses the optic chiasm and optic nerves; obviously, a tumor of this size would also cause a degree of hypopituitarism. A smaller tumor, a microadenoma, can express itself by hypersecretion of a hormone before it has either produced neighborhood signs or has compressed the normal gland to produce hypopituitarism. A functioning microadenoma secretes an excess of a particular hormone; we have encountered three neoplastic cell types that I will describe later.

We owe the transsphenoidal approach to Harvey Cushing, who took up the procedure because at that time it was safer than craniotomy. Dr. Cushing, working with a headlight (looking very much like a coal miner's lamp) and with a simple speculum, achieved excellent results. He encountered two problems—he was viewing a deep, dark hole without

magnification, and there was a CSF leak and meningitis without the advantage of antibiotics. A Frenchman, Guiot, is largely responsible for reintroducing the transsphenoidal procedure. One of his brilliant students, Jules Hardy, refined the technique, using the operating microscope and an image intensifier, which allows the operator, *during* the procedure, to observe operative maneuvers in the region of the sella.

The anatomical principles underlying the surgical approach to the pituitary are really two: One is a sublabial-transnasal-transsphenoidal approach, maintaining the strict midline which is of great advantage to the surgeon, because he can see equally well to the right and to the left and he knows that he is in the midline. The second is the image intensifier in the lateral projection, because this permits the surgeon to look on the television monitor so that he can approach the sella between the tuberculum and the floor; he can see his instruments within the sella, and he can put air in the ventricular system at the beginning of the operation and watch the third ventricle pulsate down into its normal position as the suprasellar component of the tumor is removed. For maximum safety, the image intensifier is essential. With experience, one can see and identify the normal pituitary gland, and the surgeon can be certain that the suprasellar component has been removed, because the normal intracranial pressure in a semisitting position forces the stretched diaphragm of the sella (which we have erroneously referred to as the tumor capsule in the past) back down into the sella, so that with a sizable suprasellar extension, one actually ends up with a diaphragm almost pulsating on the floor of the sella.

* This is an edited transcript of a lecture presented by Dr. Wilson at the 27th Annual Stoneburner Lecture Series, February 8, 1974, at the Medical College of Virginia, Richmond.

Dr. Hardy has recently suggested that microadenomas of certain cell types occur in preferential sites within the anterior lobe. This has not been our experience, but his larger experience is more valid. The endocrinologists with their elegant techniques can pick up endocrinopathies at an early stage. Our neuroradiology had to improve to identify a microadenoma, when the endocrinopathy was defined. This is particularly true, not so much in acromegaly, but with the galactorrhea-amenorrhea syndrome and postadrenalectomy Nelson's syndrome.

We are completing a paper on our experience with the neuroradiology of microadenomas. Although in the lateral projection, the sella is unremarkable, on plain films, lateral polytome cuts show an obviously abnormal sella. With A-P polytome cuts, one can predict the location of the microadenoma because of depression and thinning of the floor of the sella. The surgeon can expose the microadenoma at the site of the focal sellar bulging.

A microadenoma is 1 cm or less in diameter. These small tumors are ideally suited to transsphenoidal removal. One would not approach a microadenoma with the classical transfrontal technique, since it is difficult to reach and involves going through normal anterior pituitary at an awkward angle to reach the adenoma.

I have removed 60 pituitary tumors by a transsphenoidal approach; one-half presented with hyperfunctioning adenomas. My experience with these tumors has pushed me strongly in two directions: First, we have an extremely active endocrine group and a large number of acromegalic patients; second, I work with a neuro-ophthalmologist, William F. Hoyt, who attracts patients with unusual eye problems, a fair number of whom have pituitary disorders. Approximately one-fourth of his patients had clinical and chemical hypopituitarism at the time of presentation—11% complained of visual loss; 7%, of diplopia; 6%, of headache; and 4% had rhinorrhea. Regarding visual-field defects—58% had no defect, 32% had bitemporal hemianopsia or some variation of that, and 10% had some other type of visual-field defect.

By routine stains, 62% were chromophobe, 36% eosinophil, and 2% basophil. In the chromophobe group are some prolactin-secreting adenomas, some growth hormone-secreting adenomas, and some ACTH-secreting adenomas. According to functional types, 40% secreted nothing or, at least, nothing that

we recognized. I suspect, however, that this number would be smaller, if we checked every patient for prolactin levels, because elevated prolactin levels can exist without any overt clinical manifestation. The remaining 60% secreted an excess of one hormone: 14% prolactin, 10% ACTH, and the remainder, growth hormone. All patients with ACTH-secreting tumors had undergone prior adrenalectomy and presented with hyper-pigmentation and high ACTH levels.

With respect to anatomical extent of the tumors, 33% were entirely intrasellar. Some of these were microadenomas; some were not. Even with very large sellas, the tumor may be contained within the sella. The remainder extended beyond the sella—some with extrasellar extension in more than one direction—42% were suprasellar, 28% had eccentric lateral extension, and 23% went into the sphenoidal sinus. The number of sphenoidal and suprasellar extensions is directly related to the quality of the neuroradiology.

When we began using the transsphenoidal technique, we got only the castoffs—patients who had failed to respond to prior treatment. Ours was the second team in terms of handling pituitary problems, but as we demonstrated our ability to handle recurrent tumors, we began seeing primary cases.

As we gain greater experience with the acromegalic patients, we are reducing growth hormone levels down to very low levels, like 2–3 ng/ml. Not a single patient, primarily treated for acromegaly, has developed hypopituitarism following operation. Transsphenoidal removal constitutes excellent treatment for acromegaly, and we are seeing more and more patients. We are in the process now of designing a study which will compare transsphenoidal removal alone with transsphenoidal removal plus irradiation. Unless postoperative growth hormone levels are in the normal range, the adenoma has not been removed. Because our experience is limited, we do not know how many of these patients will return with late recurrence.

Patients with Nelson's syndrome have undergone adrenalectomy for Cushing's disease, and at variable times thereafter, become hyperpigmented. Many tumors that secrete ACTH are malignant in the biologic behavior, which is a compelling reason to make the diagnosis and to treat them radically as soon as possible.

One of the more interesting facets of the microadenoma story is the syndrome of galac-

torrhea and amenorrhea. Historically, three types of galactorrhea and amenorrhea have been described, depending upon whether the syndrome appeared following delivery or spontaneously. The group of interest here is the Forbes-Albright syndrome, which can have its onset either postpartally or, more often, spontaneously. By definition, the sella turcica is enlarged, and galactorrhea and amenorrhea are permanent. The only difference between the Forbes-Albright and the Del Castillo syndrome is the normal sella, and here I think it is a matter of time. These patients have microadenomas, but until one studies the sella by polytomography, the sella may appear normal. We now have eight of these patients—three harbored macroadenomas and the remainder, microadenomas. These, like the ACTH-secreting adenomas, have a greater liability than the usual chromophobe adenoma to become invasive. For some reason, unlike the growth hormone-secreting adenomas or acromegaly, tumors that secrete prolactin and tumors that secrete ACTH are inherently bad actors; that is, they have a relatively high risk of becoming malignant as judged by invasive behavior.

Excluding one patient with an intrasellar abscess, we have had no operative deaths, and this is a significant advantage of the technique. We divided the morbidity into major and minor, the major including pneumonitis and rhinorrhea. If we think that the patient might be developing rhinorrhea, we treat vigorously in the first five postoperative days; I am certain that we are overtreating and unnecessarily treating a number of patients. We insert a lumbar subarachnoid drain, start Diamox®, and elevate the head; and our rhinorrhea rate falls very rapidly. Two patients had transient cranial nerve palsies due to vigorous use of a curette against the wall of an already compressed cavernous sinus. One patient had a postoperative hematoma within the tumor capsule. This was recognized within four hours, and the patient was returned to the operating room, where it was removed with no consequences. Five patients had diabetes insipidus persisting longer than a month and four patients had transient diabetes insipidus. An aseptic meningeal reaction from blood in the CSF, sinusitis, nose bleed, one corneal abrasion, and urinary tract infections represented minor complications. In no patient who had either normal or impaired vision prior to operation was vision made worse; this makes it a very attractive procedure, because even with the very best results from the

transfrontal technique, vision was made worse in an occasional patient.

The transsphenoidal technique is the procedure of choice under the following circumstances.

1. Sphenoidal extension;
2. Modest suprasellar extension without lateral extension: We can handle the direct upward suprasellar extension. In the last 18 months, I have operated on 40 pituitary tumors, only one of which was done by craniotomy. There was a suprasellar extension that went laterally into one frontal lobe, and you simply cannot turn the corner going through the sphenoid sinus. Consequently, this patient was done transfrontally.
3. The patient with paracentral, bitemporal scotomas: The neuro-ophthalmologist will assure you that this patient has either a prefixed chiasm or a retrochiasmal nodule. This presents a difficult problem for the neurosurgeon operating transfrontally, because the optic nerves are hugging the tuberculum and there is no room to work between the optic nerves. This is, in my opinion, an indication, unless there is some contraindication, to the transsphenoidal route.
4. The microadenoma (mentioned earlier);
5. Spontaneous rhinorrhea in association with a pituitary tumor;
6. Pituitary apoplexy: A low morbidity procedure accomplishes what you want to accomplish very quickly, and since these patients are often ill and need rapid decompression, I think it is clearly the procedure of choice for pituitary apoplexy.
7. The patient who is old or debilitated for whatever reason, or if you simply want to do a biopsy.

Which tumors should be approached by the transfrontal technique? Again, this is my own prejudice. The massive suprasellar extension is a huge mass of intracranial tumor, and what is happening within and immediately above the sella is really not the important part of the tumor. I have discussed the tumor with lateral extension. Perhaps tumors with massive suprasellar and sphenoidal extensions should be removed sequentially by both routes. The one contraindication to any major procedure is unequivocal cavernous sinus invasion. Extraocular motor palsies

alone are not an indication of invasion. As pointed out by Sir Geoffrey Jefferson, a fixed sensory loss is the one clinical sign of cavernous sinus invasion.

In summary, the one thing that is new in the management of pituitary tumors is the

transsphenoidal technique. Obviously, there still remains a place for transfrontal craniotomy and cryosurgery, but I predict that an increasing number of pituitary tumors will be done by the transsphenoidal technique.

Advances in the Treatment of Patients with Benign Brain Tumors*

HAROLD F. YOUNG, M.D.

*Associate Professor of Neurosurgery, Medical College of Virginia,
Health Sciences Division of Virginia Commonwealth University, Richmond*

Introduction. Since the Stoneburner Lecturer for this year, Dr. Thomas Langfitt, is Professor and Chairman at the hospital of the University of Pennsylvania, it would only be proper to recall at least one of the important lessons taught by Dr. Francis Grant, Dr. Langfitt's predecessor at the University of Pennsylvania. One of Dr. Grant's most remembered dictums was that when a benign brain tumor is encountered, the best surgical team the clinic can assemble should be put to work on it (1). This is a valuable concept in the treatment of benign brain tumors. It is of paramount importance to protect the brain, to preserve neurological function, to restore neurological function which has been lost, and to remove the tumor completely if possible. Ample statistics reveal a 20% recurrence rate in operated benign central nervous system tumors, a rate largely related to incomplete removal at the first operation (2).

What are the recent advances which will ensure a better fate for the brain tumor patient? First is the diagnosis of the degree, if any, of increased intracranial pressure (ICP) before surgery; second is the meticulous management of anesthesia at surgery; and third is the use of the operating microscope with the associated microneurosurgical instrumentation to provide magnification surgery.

Intracranial Pressure. The recognition of increased intracranial pressure is important not only in benign brain tumors but all brain tumors which

manifest increased intracranial pressure by headache, altered states of consciousness, and the finding of papilledema. All brain tumor patients treated at MCV have ICP monitoring for three-to-five days before surgery, during surgery, and for at least three days following surgery with a subarachnoid screw (3). Figure 1 is a recording of intracranial pressure demonstrating increased intracranial pressure as the patient is being monitored before and during steroid treatment prior to surgery.

If the baseline ICP is elevated above 40 mm Hg (normal less than 11 mm Hg), there will usually be plateau waves—a transient marked increase in ICP up to 60 Hg. With the rise in ICP or at the time of a plateau wave, there may be a decrease in the level of consciousness, hypoventilation, and an increase in PaCO_2 . The patient may then be aroused by severe headaches, or by an examiner, and may then hyperventilate, lowering the PaCO_2 , relieving the headache, and returning intracranial pressure to the baseline.

We have found, upon establishing the baseline ICP, that there is usually no rapid reduction of ICP in the first 24 hours of steroid therapy even though clinical improvement is seen during the same period. We have often observed a decrease in the number of plateau or Lundberg waves occurring in the first 24–36 hours of steroid treatment. Early clinical improvement in the patient's condition, not associated with a lowering of mean ICP, may reflect a direct effect of steroids on the brain or improvement in cerebral blood flow as brain edema is reduced. Because ICP is usually reduced only after at least 24–36 hours of steroids, all of our patients are prepared for brain tumor surgery with three-to-five

* Presented by Dr. Young at the 27th Annual Stoneburner Lecture Series, February 8, 1974, at the Medical College of Virginia, Richmond.

days of steroids. During this long period of time, in which steroids may be necessary to reduce ICP, effect membrane stabilization and capillary integrity, they also may have a beneficial effect on other subcellular organelles such as lysosomes, which appear better preserved when the patient has been well prepared with steroids. Without steroids, under stress of trauma, breakdown of lysosomes results in formation of lipofuscin bodies and the release not only of acid phosphatases, but of other hydrolytic enzymes as well (4). Experimental evidence also reveals a decrease in the severity of the traumatized brain when treated with steroids (5); thus, we use ICP monitoring and long-term steroid administration prior to surgery to reduce ICP and to protect the brain from any trauma that may occur during surgery.

Anesthesia. The next important aspect of the management of patients with benign brain tumors is induction of anesthesia. This is a most critical time for the patient. Even preoperative sedation can cause hypoventilation, blood gas changes, and alterations in intracranial pressure between the time the patient leaves the floor and the time he arrives in the operating room. All brain tumor patients undergoing surgery have intracranial pressure subarachnoid monitoring not only preoperatively but during the induction of anesthesia as well. Likewise, an arterial line from the patient's radial artery is connected to a 4 channel Grass recorder, and end-expiratory CO_2 is measured on a capnograph. By this technique we have been able to confirm that there are many times during the induction of anesthesia when a change in ICP may occur (6). A rise in ICP may be hazardous for the patient if increased intracranial pressure is present at the induction of anesthesia. It is best to have knowledge of the intracranial pressure prior to the induction of anesthesia as hyperventilation or intravenous mannitol may be needed to reduce intracranial pressure. For instance, while halothane is not a dangerous anesthetic, increasing its concentration quickly increases intracranial pressure. Figure 2 shows the reduction of ICP when intravenous pentothal is administered. This is in agreement with Shapiro's recent report showing that thiopental sodium, or pentobarbital, will reduce intracranial pressure (7). Ethane is an agent useful in lowering intracranial pressure unless increased to a concentration of 4% or more. Intracranial pressure monitoring reveals a balanced barbiturate anesthetic to be a valuable anesthetic technique in brain tumor surgery.

At the time of intubation, there is usually a brief

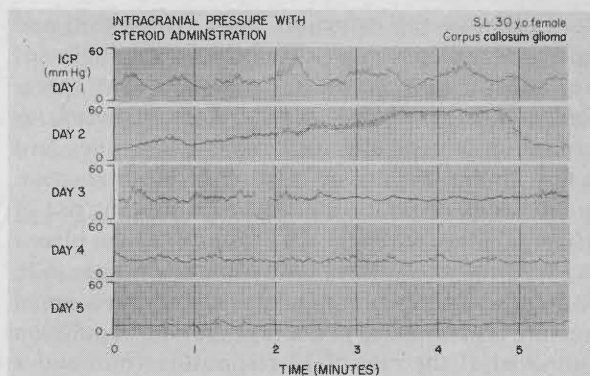


Fig. 1—Intracranial pressure recording in mm Hg during 5 days of steroid (Decadron® 4 mg 1m q6h) treatment. On day 1 and 2 baseline ICP runs between 30–40 mm Hg with plateau waves up to 60 mm Hg. Plateau waves disappear on day 3 but baseline ICP is only in normal range on the fifth day of treatment.

increase in intracranial pressure associated with a small change in arterial blood pressure (Fig. 2). A short period of straining on the endotracheal tube will likewise produce a rise in ICP, and prolonged straining or "bucking" must not be allowed.

After the induction of anesthesia, the surgeon must carefully position the patient's head for his surgical advantage without turning the head so severely that a major blood vessel to or from the head is occluded; this is often overlooked in preparing the patient for surgery. Care must be taken not to obstruct venous drainage from the head as this will certainly increase ICP.

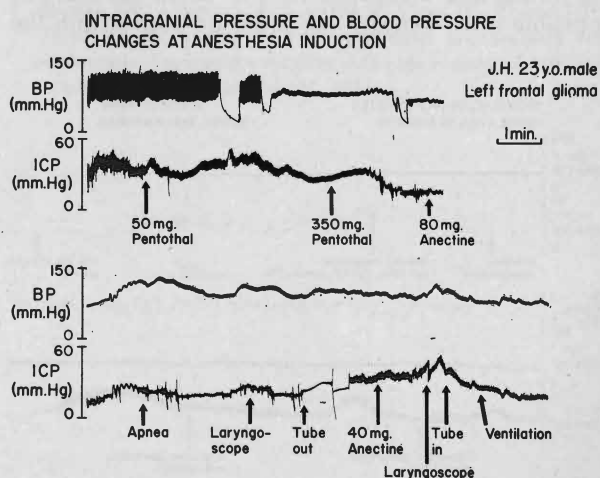


Fig. 2—(Top Tracing) Pentothal lowering ICP within 1 minute of administration; 50 mg pentothal produced a slight decrease in ICP while 350 mg produced a marked decrease in ICP. (Bottom Tracing) Rise in ICP to almost 60 mm Hg during intubation.

Following the induction, both the surgeon and the anesthesiologist must also focus on ventilation of the patient. Figure 3 is the ICP recording of an operation on the posterior fossa where spontaneous respiration is generally used since it is a safeguard against undue trauma or traction of the brainstem. Spontaneous respiration produced a prompt rise in intracranial pressure and the patient was then placed on a respirator to control ventilation and reduce ICP. In order to operate on an adult patient, intracranial pressure is maintained in a safe range with ventilation controlled at the rate of 12 respirations/min and a tidal volume of 900 cc with each respiration. Unfortunately, when the surgeon is operating he may, nevertheless, reach a point where he is about to open the dura only to find it very tight. If the surgeon demands that the anesthetist hyperventilate the patient, an over reaction by the anesthetist of rapid hand ventilation may result in exchange of a small tidal volume too rapidly for sufficient venous return and intracranial pressure may not be lowered but may actually be increased. The induction of anesthesia must be attended by the neurosurgeon as well as the anesthetist. This is one of the most important aspects of the operation, errors in management of the anesthetic resulting in intracranial pressure changes could lead to a tragic result from the operation.

Magnification Surgery. One of the reasons for emphasizing control of intracranial pressure and the induction of anesthesia is that it is important, in the technique of operating on a brain tumor using an operating microscope, to have as much exposure as possible often beneath the brain or deep within the

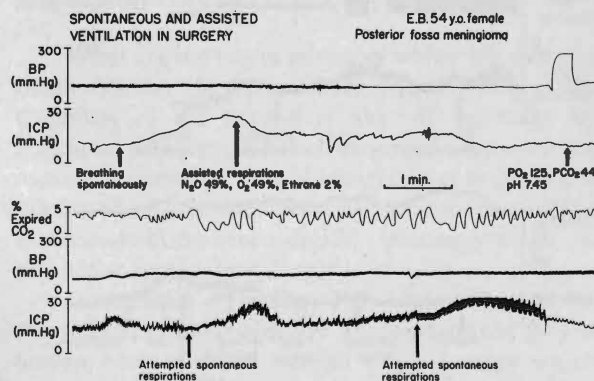


Fig. 3—Intracranial pressure recording during posterior fossa surgery demonstrating repeated elevation of ICP whenever the patient is allowed to breath spontaneously. This elevation of ICP is corrected by assisting respiration (Top Tracing).




Fig. 4—Ceiling-mounted operating microscope in the neurosurgical operating room at the Medical College of Virginia. Focusing is accomplished by foot control pedal not shown in figure.

brain without retracting the brain. Careful attention to the small metabolic parameters discussed above afford a much better opportunity to operate on the brain under relaxed conditions. Brain retractors should be used to protect the brain, not to retract the brain, and the tumor must be removed from the brain, not the brain from the tumor. The operating microscope has changed our approach not only to intracranial vascular surgery, where it is absolutely necessary, but also to benign brain tumor surgery as well. Presently the only type of tumors not requiring use of a microscope are malignant gliomas of the cerebral hemispheres.

At MCV a ceiling-mounted microscope allows the surgeon and one assistant or resident to see and become involved in the operation (Fig. 4). The best place to install a ceiling-mounted microscope is in the center of the operating room. Many surgeons prefer the floor-mounted movable microscope, finding it easier to move the microscope to the patient than to move the patient to the fixed microscope. The limitations of the microscope earlier in our ex-

perience included the fact that it made resident teaching difficult and did not allow the scrub nurse or the anesthesiologist the opportunity to view the surgery. A video tape camera can be attached to the operating microscope allowing both the scrub nurse and the anesthesiologist to view the surgery and also the televising of the surgery to any location in the hospital, providing greater flexibility of the microscope as a teaching instrument.

The important lessons in developing excellent microsurgery techniques are learned in the microneurosurgical laboratory. An extended period of time must be spent in the laboratory learning how to handle and drape the microscope as well as to learn microneurosurgical instrumentation and techniques. The MCV division of Neurosurgery has such a laboratory. One should borrow neither the ophthalmologists' nor the otolaryngologists' microscope for an occasional neurosurgical operation nor purchase a set of a famous neurosurgeon's instruments and expect to immediately perform magnification neurosurgery.

With the proper use of the microscope, it is possible to approach any area in or near the brain to safely remove tumors while preserving vital structure. For instance, the microscope has been the primary reason for the renewed interest in the transsphenoidal approach to pituitary surgery. The small secreting tumors of the pituitary causing acromegaly can now be removed while preserving the pituitary gland (8).

Summary. Reliable ICP measurement allows an exact quantitation and management of intracranial pressure. This precise assessment of ICP is a valuable adjunct in the management of anesthesia for brain tumor patients. The proper combination of ICP and

anesthesia management enables the surgeon to use the operating microscope to approach previously inaccessible areas of the brain and to perform meticulous surgery with a better prognosis for the brain tumor patient.

REFERENCES

1. GRANT FC: A study of the results of surgical treatment in 2,326 consecutive patients with brain tumor. *J Neurosurg* 13:479, 1956.
2. SIMPSON D: The recurrence of intracranial meningiomas after surgical treatment. *J Neurol Neurosurg Psychiat* 20:22, 1957.
3. VRIES JK, BECKER DP, YOUNG HF: A subarachnoid screw for monitoring intracranial pressure. *J. Neurosurg* 39:416, 1973.
4. LONG DM, MAXWELL RE, FRENCH LA: The effects of glucosteroids upon experimental brain edema. In: *Steroids and Brain Edema* Eds. Reulen HJ, Schurmann K, Heidelberg, Springer-Verlag, 1972, pp 66-75.
5. KOBRINE AI, KEMPE LG: Studies in head injury. II. Effect of dexamethasone on traumatic brain swelling. *Surg Neurol* 1:38, 1973.
6. LUNDBERG N: Continuous recording and control of ventricular fluid pressure in neurosurgical practice. *Acta Psychiat Neurol Scand* (Suppl) 149:7, 1960.
7. SHAPIRO HM, WYTE SR, LOESSER J: Barbiturate-augmented hypothermia for reduction of persistent intracranial hypertension. *J Neurosurg* 40:90, 1974.
8. BECKER DP, ATKINSON R, SAKALAS R, VRIES JK, YOUNG HF, VINES FS, MARTINEZ J: Transsphenoidal microsurgery for acromegaly. Successful treatment with preservation of pituitary function. *Confin Neurol* 36:101, 1974.

Advances in the Management of Patients with Malignant Brain Tumors*

CHARLES B. WILSON, M.D.

*Professor and Chairman, Department of Neurosurgery,
University of California, San Francisco*

In describing what is new in the management of malignant brain tumors, I shall confine myself largely to chemotherapy and shall outline what we think is important based on our own experience, what we have achieved with single and multiple agents, and where we are going. We have just reviewed our five-year experience and find that chemotherapy, perhaps, is the only thing that is new.

The development of drugs since 1943 has been escalating at a fantastic rate. Today, we can provide the chemotherapist with a wide array of drugs from which to choose.

Several neoplastic diseases are now recognized as being highly responsive to chemotherapy and the list is growing. The first to be recognized was childhood lymphocytic leukemia, then choriocarcinoma, and now testicular carcinoma and Wilm's tumor.

The first consideration for effective brain tumor chemotherapy, as we see it, is that the agent must have optimum lipid solubility or a special transport system. We are convinced that it must penetrate the normal brain to be truly effective, and I shall indicate our reasoning below.

One must achieve an adequate drug level in brain adjacent to the tumor with minimal or no neural toxicity, and the drug must be given frequently enough to produce maximal DNA damage with insufficient time for repair. At the present time, we are studying the rate of DNA damage and repair in a search for combinations of drugs that will give less

than added toxicity and, at the same time, will produce synergistic antitumor effects.

A water soluble compound is excluded by the intact blood-brain barrier and, administered intravenously, the drug attains a high concentration only in the leaky, central portion of the tumor. As the drug moves toward ventricular and subarachnoid cerebral spinal fluid (CSF), the concentration falls very rapidly, so that the active periphery of the tumor is exposed to low concentrations of its drug and for a brief time only. If one gives a water-soluble drug in the CSF, however, it moves quickly across the ependyma into adjacent brain. It does not exit from the normal brain but diffuses through brain into tumor. This would be a reasonable way, then, to give a water-soluble drug.

On the other hand, if one uses a lipid-soluble agent, for example, the nitrosoureas, it crosses capillaries in the normal brain. Obviously, it crosses the tumor's leaky capillaries, so that one has equal drug concentrations in brain adjacent to tumor and in tumor. If one injects a lipid-soluble drug into the ventricle, it crosses the ependyma, instantly goes out through the capillaries of the normal brain, and none of it ever reaches the tumor, unless it happens to be very close. It would be irrational to use a lipid-soluble drug intrathecally. With lipid-soluble compounds, concentration in the tumor is the same as concentration in the brain. We believe that this is important both from the theoretical standpoint and from our own experience.

Our group is interested in developing effective drugs and drug schedules in the laboratory and in bringing these into clinical trials. We started out with a rat glioma; now we have two rat gliomas and three

* This is an edited transcription of a lecture presented by Dr. Wilson at the 27th Annual Stoneburner Lecture Series, February 8, 1974, at the Medical College of Virginia, Richmond.

mouse gliomas, which we use for drug screening. In the past, we have used reservoirs in pups for intrathecal administration. We can perform intrathecal injections in the rat, so that it provides a model for therapy, either by continuous intra-arterial infusion or by intrathecal injection. We are not limited by the route of administration. It turns out that the models have been extremely useful, not only for screening promising compounds but also for working out drug schedules and routes for administration.

The kinetics of brain tumors are most important. We have studied animal tumors and have completed studies of human tumors *in vivo*. To summarize what we know about a glioblastoma at the present time, we have shown that in a glioblastoma, approximately 30% of viable cells are actively dividing and the other 70% of the cells are nondividing (nonproliferating). The cell cycle, that is, the length of time it takes a glioblastoma cell to go from one mitosis to two cells at the next mitosis, is somewhere in the range of $2\frac{1}{2}$ –3 days. Were it not for a very high rate of cell loss, the volume of a glioblastoma would double in approximately one week. This is unrealistic on the basis of clinical observation. We know that the period of time required for the glioblastoma cell to synthesize its DNA is about 9–10 hours and, interestingly enough, it takes an astrocytoma the same period of time.

In our studies, we have used radioactive thymidine, labelled either with tritium or with ^{14}C . We have documented the intense proliferation seen in blood vessels within a glioblastoma. In all probability, the limiting factor in the growth rate of a glioblastoma is the rate at which the blood vessels can proliferate, because there is good reason to believe that the capillary endothelium cannot divide as rapidly as tumor cells. In brain adjacent tumor, in the absence of tumor cells, because of tumor angiogenesis factor, blood vessels proliferate in advance of invasive tumor.

The brain presents a particular problem. After treatment with an effective chemotherapeutic agent, a dead cell takes up approximately twice as much room as living cell. The result is an increment of edema or swelling of tumor cells and an increase in volume. This increased volume can be detrimental because of the effects of an increase in intracranial pressure. Dead cells must be removed; although these cells are now nonviable, they are still present and therefore act as a mass. We have just completed studies on dead-cell removal and have shown that when one puts

tagged, lethally irradiated cells in brain, muscle, and subcutaneously, brain has a most inefficient, sluggish means of dead-cell disposal. We are convinced, both from pathological studies as well as our own observations, that the brain is relatively inefficient in removing dead cells as opposed to other solid organs. At this period, we often have to use steroids to combat increased intracranial pressure and the question arises as to what steroids do to tumors?

Methyl prednisolone or any of the glucocorticoids will increase the survival of tumor-bearing animals that receive the steroids. Thus, you can increase the survival of a rat bearing a glioma by giving steroids. If one has a control group and a group treated with methyl prednisolone, and they are killed at the same time (in this instance on the 21st day) one finds that the tumors in the control animals vary pretty widely but have a mean weight of 157 mg, whereas the tumors of the animals receiving steroids are much smaller with a mean weight of 36 mg. One can explain this difference in two ways—steroids kill tumor cells and steroids slow down the rate of cell proliferation. We now have evidence that the latter is true. There is no direct oncolytic effect on glial tumors, but the steroid simply puts certain proliferating cells into a nonproliferating state, and it also increases the period of time necessary for a cell to divide, that is, the cell cycle time. This became very important when we checked our own clinical statistics. Were we confusing ourselves in judging drugs by the concomitant use of steroids? To answer the question, we took consecutive patients. One group of patients never received steroids. With an approximately equal number of patients in both groups, we determined how many were chemotherapy responders, probable responders and nonresponders. The concomitant use of steroids did not change the frequency of response to chemotherapy. We have concluded that steroids have one major effect in the brain tumor patient, that of reducing cerebral edema. To date, we have no clinical evidence that they have any effect on tumor cells.

The material that I intend to present is based on a particular group of patients. These are patients who either have tumors recurrent following surgery and radiation therapy or in whom the diagnosis of a malignant tumor could be made without any reasonable doubt and whom we elect to treat by chemotherapy rather than by radiation therapy. In the latter group, we do not insist upon a tissue diagnosis, feeling that the price of obtaining a tissue

diagnosis is to justify the biopsy of a glioblastoma or a brain stem glioma. For reasons that I shall point out, this is more often the case.

Consequently, patients who are eligible for our Phase II trials are those either with recurrent tumors or with primary tumors who are considered candidates for primary chemotherapy without surgical verification. In addition, we treat a small number of patients with metastatic tumors. A phase II trial asks one question: Is the drug effective, that is, does this drug have some activity against the tumor? It asks neither what the cure rate is nor for how long. A phase II study is designed solely for searching out and identifying effective drugs. For a patient to be eligible for this kind of study, he must first be ineligible for other studies in our program. Second, with a pathological diagnosis or an unequivocal radiographic and clinical picture, the patient is deteriorating neurologically. Third, if radiotherapy has been given, it must have been completed at least three months prior to chemotherapy. Dead cells hang around after the completion of radiotherapy, and late improvement can occur following radiotherapy. As a matter of fact, since we have instituted this rule, we have actually confirmed delayed improvement up to three months after radiotherapy. Finally, the patient is expected to live at least two months, and we are sometimes wrong on that estimate, but the patient, or more often his family, understands the complications of chemotherapy. Parenthetically, I can say that we have lost approximately 1% of our patients as a direct result of complications of chemotherapy; our morbidity has been higher. Mortality has remained low because we have means of rescuing the patient who gets thrombocytopenia or leukopenia.

Thirty-four patients were not treated because: 1) we found no evidence of tumor regrowth, 2) we thought that they would live less than two months, 3) they declined treatment after understanding it, or 4) further surgery was elected. In the latter category, a benign fourth ventricle cyst was referred to us as a recurrent brain stem glioma, and we sent the patient back with diagnostic studies to the referring neurosurgeon who removed the cyst. Recently, I removed a nerve sheath tumor of the tenth nerve which had been misdiagnosed as a brain stem glioma and, after radiation therapy, was sent to us for chemotherapy. We have seen a variety of misdiagnosed lesions, emphasizing the need for careful study. In one patient, we thought radiotherapy was the treatment of choice.

To judge the effect of chemotherapy, we use two criteria. We have a third which will probably be added—the EEG (which came as a complete surprise to me). At first, I would not allow our electroencephalographer to charge our patients, because I was convinced that EEG would be valueless, but it did just about as well as a scan in predicting whether a patient was better or worse. We, like others, will be looking to the EMI scanner for a fourth criterion. The two criteria on which our data are based are the clinical status and the brain scan. A patient classed as a responder is better clinically and his brain scan is better. A patient is designated a probable responder if clinical status is: 1) improved and the brain scan is the same, 2) if the clinical status is the same and the brain scan is better, or 3) if both of them remain the same for at least three months in the case of medulloblastomas and glioblastomas and six months for more benign tumors. A nonresponder deteriorates as judged by clinical status and brain scan.

A certain number of patients in our series were nonevaluable. We determined, in retrospect, that patients surviving for less than two months after beginning treatment were not evaluable—again, because of the slow removal of dead cells. Approximately 15% of all responders were considered failures when they returned for their second course of therapy. If a patient receiving a course of chemotherapy is obviously worse six weeks later, it does not mean that the drug is ineffective, because among those patients who eventually turn out to be unequivocal responders, 15% have had an initial deterioration in brain scan and clinical condition. Several patients were nonevaluable because, in the beginning, we were inexperienced. In some, the neurological condition was not clearly deteriorating immediately prior to treatment; others failed to complete one full course; and on five patients, we were unable to obtain an adequate follow-up.

What can we expect in using single drugs? With BCNU (still the best single drug used to date), 27 of our 57 patients showed a response, a rate of 47% over a mean duration of nine months, and this a population of recurrent tumors. CCNU has a response rate of 44% but for a shorter mean duration. Procarbazine, also a powerful drug with a 52% response rate, has a mean duration of six months. We are unable to give an explanation for the fact that when we combine BCNU and vincristine (which should be a good combination because vincristine is not toxic to the bone marrow), we get a response rate of only 45%

over four months. Although BCNU and CCNU are virtually identical and both are highly lipid soluble, BCNU seems to have a clear advantage. Procarbazine is not lipid soluble, but it does proceed rapidly, in high concentration, into CSF. The three most effective single agents, thus, have in common bone marrow toxicity and very rapid entry into brain and into CSF.

What of the patient who receives a first drug and, whether with or without response, then proceeds with a second drug? A response to a second drug is very small, probably for two reasons—one, a possible cross resistance and two, by the time of proceeding to a second drug, the patient is usually in poor condition.

What can be said of tumor types as related to specific drugs? With malignant gliomas and astrocytomas or glioblastomas, the response is similar with all of the three most effective drugs. For ependymomas, BCNU is extremely good, one of our patients responding to BCNU as the second drug administered. The other tumor-specific chemotherapy, which I shall go into later, is the combination of procarbazine, CCNU, and vincristine that seems to be highly effective for medulloblastomas.

As must be well known, BCNU is given intravenously on various schedules; it is quite likely that we do not use the optimal schedule. One of our early patients, a quadriplegic with an ependymoma, had a fantastic response over several months to BCNU, but ultimately could not receive any more due to the development of cumulative bone marrow toxicity. One patient with a malignant astrocytoma, having been treated with BCNU for two years, shows no evidence of tumor regrowth after two and one-half years off treatment. One young boy, who had a recurrent ependymoma of the fourth ventricle with supratentorial metastases, tumor cells in his CSF, and recurrent tumor in his posterior fossa, was treated with BCNU for two and one-half years; he is attending college now with no evidence of recurrent disease after two years off treatment.

The Brain Tumor Study Group has studied BCNU in a phase III trial, taking patients who had had a major craniotomy and removal of a supratentorial glioblastoma. Postoperatively, these patients were not dependent upon steroids and they randomized within three weeks of operation; thus, this is a select group of patients treated in the early postoperative period. Patients who received no further treatment had a median survival of 15

weeks—a little less than four months, which seems to be a little on the low side. Those patients who received only BCNU postoperatively had a median survival of 21 weeks; those who received irradiation therapy had a median survival of 30 weeks; and those receiving BCNU plus irradiation had a median survival of 40 weeks. How do we interpret this? Irradiation and BCNU combined are better than either alone and better than no further treatment after surgery as well. Of the various forms of adjuvant therapy reported for glioblastomas, the most effective is BCNU and irradiation combined following major tumor removal. At the time of this study, about four years ago, BCNU was used because it had been shown to be an active drug in phase II trials.

One of the people in our laboratory became an expert at removing rat gliomas, and we evaluated adjuvant chemotherapy and surgery, using a rat brain tumor model. We asked: Are we giving BCNU at the right time? Should it be given before operation, with the operation, or afterwards? We tried various combinations of BCNU and surgery and in one group, we even added 5-FU to obtain early proliferating postoperative cells. The study showed that there was no combination of surgery and BCNU that was as beneficial as BCNU alone. I could not believe it and we repeated the experiments four times. The experiments defied my prejudice and the basic laws of cell kinetics, and the results have now been submitted for publication. I do not believe, however, that on this basis, neurosurgeons will stop removing glioblastomas, but we did feel encouraged to treat a few human glioblastomas, diagnosed angiographically without histological verification. Of the patients treated in this way, only two harbored primary reticulum cell sarcomas that we called glioblastomas—not a large error.

Procarbazine is a monoamine oxidase inhibitor and patients under treatment, therefore, cannot eat ripe cheese or take certain drugs. One patient, who showed excellent results by brain scan, became irreversibly psychotic, so it is not a perfect drug, but it does move rapidly into the CSF. In one of our first patients, with a recurrent medulloblastoma and a total spinal block, procarbazine alone melted away the mass. Though active against medulloblastomas, procarbazine alone is not as active as a more recent drug combination to be mentioned below. Its activity against malignant gliomas is similar to BCNU.

Single drug therapy for solid tumors is rarely curative in animal or human systems after the tumor

reaches a clinical size. Those people interested in solid tumors, therefore, are looking to combination chemotherapy, using drugs that have qualitatively different toxicity and complimentary mechanisms of action to prevent the emergence of resistance clones, and are combining agents that act on cycling versus noncycling (nonproliferating) cells.

Our first multiple drug protocol involved three drugs: CCNU, which we knew was active and could be given by mouth; vincristine, which was active and did not add toxicity to the bone marrow; and procarbazine, which we thought was an excellent drug. The course was given on a 28-day cycle: CCNU on day 1, procarbazine for the first 14 days, and vincristine twice (days 1 and 8). We obtained a response rate of 57% (I cannot give the median duration, but it has produced some of the most dramatic responses we have seen with medulloblastomas.). We are now persuaded for the first time, that we have something safe enough and effective enough to justify designing a study of combining chemotherapy with radiotherapy for the immediate treatment of verified medulloblastomas. Our response rate here has been well over 75%, but the patients do develop chronic bone marrow toxicity. For example, a little girl who came in with papilledema and huge subfrontal metastases had a normal brain scan two months ago, after receiving procarbazine, CCNU, and vincristine, but due to chronically depressed bone marrow, we are unable to give her more drug and she is experiencing a recurrence.

We tried the combination of Cytoxan® (cyclophosphamide), CCNU, and vincristine. We saw few responses and concluded that this is not an effective combination.

What are the approaches to more effective chemotherapy? We are convinced that drug combinations are the wave of the future. Simultaneously, we are trying to identify new effective single drugs and effective combinations of single drugs. We are now actually putting into practice schedules based on kinetic information, that is, cell cycle and number or percentage of proliferating cells. It may be possible to convert tumor cells that are nonproliferating into a proliferating state in which they are more susceptible to drugs specifically damaging to proliferating cells. Possibly, we can convert some normal cells, such as gut and bone marrow, from their normal proliferating state to a noncycling compartment, particularly bone marrow, so that it will not be devastated by the drugs we use. We do not have a single drug today that is specific for cancer cells and are always on a tight wire between poisoning the host and poisoning the cancer.

We hear a great deal about enhancing immune mechanisms. In the one reported study, patients who were immunized did no better than those who were not. There are some very promising things on the horizon, but at the moment, I see no immediate role for immunotherapy. The successful acceleration of dead cell disposal, in which we are extremely interested, will have some practical application.

In summary, our studies have identified three agents individually active against a variety of brain tumors. Procarbazine belongs in another pharmacological group, but BCNU and CCNU are similar. Combination chemotherapy holds great promise for brain tumor chemotherapy, and one of the two combinations evaluated by us is highly effective against medulloblastomas.

Practical Anticonvulsant Pharmacokinetics*

R. B. DAVID, M.D.

*Associate Professor of Pediatrics and Neurology;
Director, Pediatric Neurology, Medical College of Virginia,
Health Sciences Division of Virginia Commonwealth University, Richmond*

L. K. GARRETTSON, M.D.

*Associate Professor of Pediatrics and Pharmacy-Pharmaceutics,
Medical College of Virginia, Health Sciences Division of
Virginia Commonwealth University, Richmond*

Pharmacokinetic Considerations. Pharmacokinetics is that area of pharmacology concerned with the absorption, distribution, metabolism, and elimination of drugs. The processes by which absorption, distribution, and elimination take place are referred to as unit processes. These occur independently and concurrently, and involve such activities as absorption into the blood, elimination from the blood, distribution between the blood and tissue, inactivation in tissues, and finally, elimination from the blood. Drug handling by the body can be characterized by the rate for each step or, more often, the rate of all processes. Classification of observed kinetics for these rate processes includes first-order, zero-order, and capacity-limited kinetics. In the description of these processes, we will use total body elimination as the model, as this is the way most data are handled clinically (1).

The rate of first-order or exponential drug elimination is proportionate solely to the amount of drug present. The half-life is constant regardless of the quantity present. Thus, if the dosage is doubled, the half-life will remain the same.

Zero-order kinetics is the term used to describe processes where rates are constant per unit time; the time required to rid the body of one-half the drug is prolonged by increasing the body load. It is implied that the rate process is limited, and the rate of elimination is fixed.

Capacity-limited kinetics describe a situation of a rate process being variable and between the limiting situations of first and zero-order. As the number of drug molecules approximates the number of metabolic sites, for example, special mathematical processes must be employed to describe the responses. As drug levels rise, the rate approaches the zero-order rate (constant amount eliminated/time) and as levels fall, first-order rates are approximated.

If we consider the situation of drug overdose or intoxication, it may help to clarify these different kinetic patterns. If zero kinetics are operative as in alcohol, the patient will rid himself of the same number of milligrams each hour regardless of serum level. At high levels in the body, this constant amount is a very small percent of body load and the rate of decline of serum concentration is slow indeed. If first-order kinetics attain, as with phenobarbital, the total body load in the intoxicated patient will decline to one-half in the same time as the amount in the patient with a therapeutic amount. The situation of saturation

* Presented by Dr. David at the 27th Annual Stoneburner Lecture Series, February 8, 1974, at the Medical College of Virginia, Richmond.

tion kinetics is an intermediate between the two. An understanding of these principles is important mainly for preventing intoxication, for efficient alteration of dosage, and for understanding individual variations.

While the determination of rate constants is important, other parameters are of concern. Absorption parameters include both the rate of absorption and the bioavailability or percentage of the drug absorbed which reaches the active sites in the body. Distribution parameters include not only the rate of distribution but also the volume of distribution or extent to which the drug is found outside the blood; this is affected by protein binding. Protein binding may be affected by disease states and other drugs.

The pharmacologic effect on the desired organ or organ system will be dependent upon the amount of time in the body, the time exposed to the target organ, and the specific properties of the drug used. The occurrence of side effects is dependent upon similar considerations.

There are many patient variables such as individual physiology, pathology, and genetic characteristics, as well as developmental and environmental factors which effect drug response. A drug serum assay (drug level determination) is but a small part of the data necessary to make an intelligent judgment with regard to maximizing the desired effect in therapy. Serum assay determines only the quantity in the serum and basic assumptions must be made in regard to the organ or organ system where the drug is active. Many factors affect the relationship between serum concentration and drug effect. An understanding of pharmacokinetic principles will result in less trial-and-error pharmacotherapy and more frequent consideration of important variables. For example, if the physician, as his goal in treating the seizure patient, has established that a patient should have no subsequent seizures, then he will, with a basic understanding, be able to prevent some of the seizures which occur during the start-up and dosage-adjustment phases of drug therapy; he may also avoid intoxication.

Clinical Considerations. The availability of drug assays and pharmacokinetic data has already provided some useful information for the clinician (2). This has increased our knowledge in four areas: the initiation of therapy, dosage regimens, routes of administration, and adjustment of dosage for the four basic anticonvulsants—phenobarbital, diphenylhydantoin (Dilantin®), primidone (Mysoline®), and ethosuximide (Zarontin®). These are

the most commonly used agents, and there are, consequently, more pharmacokinetic data regarding them.

Initiation of Therapy. With respect to the initiation of dosage, there is a rule of thumb that can be helpful: If a maintenance dosage regimen is used to initiate therapy, four times the half-life of the agent will be required to achieve 90% of the ultimate serum plateau. Since such a long time is required to reach this plateau with some drugs, such as diphenylhydantoin, loading has been used, particularly to achieve rapid therapeutic levels. Phenobarbital and primidone, however, produce significant drowsiness, so they are usually not "loaded." With ethosuximide, employed in the treatment of absence seizures, loading doses are usually not used because of the mild nature of the seizure being treated. Agents with long half-lives, however, are, potentially, those with which the initial dose should be larger than the maintenance dose.

The usual starting dose for phenobarbital is 5 mg/kg/day in the child and about 1 mg/kg/day in the adult. The half-life is 18–70 hours in a child (3) and 55–120 hours in the adult (4). In general, the younger the individual, the shorter the half-life.

The starting dose for diphenylhydantoin is 5–8 mg/kg/day for the child and 4–6 mg/kg/day for the adult. Once the therapeutic level is achieved, the apparent half-life is 8–12 hours. Loading of diphenylhydantoin can be accomplished by giving three times the maintenance dose in three divided doses, three hours apart on the first day (5); the second day, the usual maintenance dose is given. Therapeutic levels are reached in 12 hours, and peak serum levels are usually achieved on the third day. Diphenylhydantoin may also be loaded intravenously with accompanying electrocardiographic monitoring, but not more than 50 mg/minute should be given (6).

The initial dose of primidone administered is less than the maintenance level because of the initial potent hypnotic side effects. Usually, a maintenance dose of 20 mg/kg/day is sought. Switching a patient from phenobarbital to full maintenance primidone usually can be accomplished without producing sedative side effects. The half-life of primidone is short—3–12 hours (7).

The starting dose of ethosuximide is 20 mg/kg/day. The half-life is a mean of 66 hours in an adult and 30 hours in a child.

Dosage Regimens. Because phenobarbital and ethosuximide have long half-lives, once-daily ad-

ministration can be employed, and because of diphenylhydantoin's slow absorption, it also can be given once daily. Primidone, having a relatively short half-life, generally, should be given three times a day, although some patients are well treated with twice-daily dosage. Ethosuximide may have a gastric irritant effect, so some clinicians employ it in a twice-daily regimen.

Routes of Administration. Ethosuximide and primidone can be given only orally. Phenobarbital can be given orally, intramuscularly or intravenously. While diphenylhydantoin can be given orally or intravenously, intramuscular administration usually fails to release sufficient diphenylhydantoin to the blood, when given as the usual maintenance dose. Doubling the maintenance dose when giving it intramuscularly is satisfactory, particularly when using this route for short-term replacement of oral therapy, as in surgery (8).

Adjustment of Dose. In adjusting the level of medication, one should remember that phenobarbital and ethosuximide are eliminated by first-order kinetics and diphenylhydantoin, by capacity-limited kinetics (9). Consequently, doubling the dose of phenobarbital will double the blood level, as trebling the dose will triple the blood level. When levels of diphenylhydantoin are low, a similar relationship exists. At higher levels, in practice, apparently, above 10 $\mu\text{g/ml}$, the effect of capacity-limited kinetics is that apparently relatively small dosage increments result in greater serum level increases than is expected or desired. Half increments are probably in order here. The therapeutic ranges given for phenobarbital levels are 10–50 $\mu\text{g/ml}$, for primidone are 5–20 $\mu\text{g/ml}$, and for ethosuximide are 40–80 $\mu\text{g/ml}$. The therapeutic range for diphenylhydantoin is 6–20 $\mu\text{g/ml}$. Recent work indicates that low serum levels are effective in controlling seizures particularly in children.

Compliance. While our knowledge of pharmacokinetics has increased, one larger problem exists in the area of compliance. Compliance is poor when administration of the drug is too frequent, when multiple drugs are used on a different schedule, and when the dosage form is unacceptable.

Three of the anticonvulsants mentioned can be given as infrequently as once a day. This eliminates the necessity for children to take these agents in school. When multiple agents are given, it is relatively easy to give all medications at one time.

Phenobarbital is available as an elixir, diphenylhydantoin and primidone, as suspensions. Where it is

possible, the tablet form assures a more reliable dosage intake. In the young child, all can be crushed and given with jelly or other vehicles. Diphenylhydantoin comes as a chewable tablet, and while it may produce more gingival hypertrophy than the capsule, we continue to use it extensively. Ethosuximide constitutes a rather special problem being a liquid within a rather large gelatin capsule. The capsule can be pricked by a pin and the liquid mixed with juice or another vehicle by the pharmacist or mother. One ingenious mother related that the capsule can be frozen, then cut in half and given with ice cream.

Memory crutches are useful. The most inexpensive is the traditional egg carton. Dial-a-packs are also available and can be loaded by the patient with his drug or drugs.

A new era is here. Practical pharmacokinetics, skillfully utilized by the clinician, should aid immeasurably in producing seizure-free patients and in reaching the goal quickly with fewer side effects.

REFERENCES

1. JUSKO WJ: Pharmacokinetic principles in pediatric pharmacology. *Pediat Clin N Am* 19:81, 1972.
2. GARRETTSON LK: Pharmacology of anticonvulsants. *Pediat Clin N Am* 19:179, 1972.
3. HEINZE E, KAMPFMEYER HG: Biological half-life of phenobarbital in human babies. *Klin Wschr* 49:1146, 1971.
4. LONS P: Plasma levels and urinary excretion of three barbituric acids after oral administration to man. *Acta Pharmacol Toxicol* 10:147, 1956.
5. WILDER BJ, SERRANO EE, RAMSEY RE: Plasma diphenylhydantoin levels after loading and maintenance doses. *Clin Pharmacol Therap* 14:797, 1973.
6. KUTT H, McDOWELL F: Management of epilepsy with diphenylhydantoin sodium. *JAMA* 203:969, 1968.
7. GALLAGHER BB, BAUMEL IP: Primidone: Absorption, distribution, and excretion. In: *Antiepileptic Drugs*. Eds. Woodbury DM, Penry JK, and Schmidt, New York, Raven Press, 1972, p. 357.
8. SERRANO EE, ROYE DB, HAMMER RH, WILDER BJ: Plasma diphenylhydantoin values after oral and intramuscular administration of diphenylhydantoin. *Neurology* 23:311, 1973.
9. HOLCOMB R, LYNN R, HARVEY BJ, SWEETMAN BJ, GERBER N: Intoxication with 5,5-diphenylhydantoin (Dilantin®). *J Pediat* 80:627, 1972.

Advances in the Medical and Surgical Management of Intractable Partial Complex Seizures* **

HOOSHANG HOOSHMAND, M.D.

*Associate Professor of Neurology, Medical College of Virginia,
Health Sciences Division of Virginia Commonwealth University, Richmond*

Introduction. Seizures can be due to a variety of acute, subacute, or chronic diseases with different etiologies. Clinically, they may manifest as focal or generalized phenomena (Table 1). Whereas the majority of the patients suffering from partial seizures are easily controlled with medications, in a small number of patients treatment may fail. The failure may be due to incorrect diagnosis or incorrect therapy. The efficacy of medical treatment for seizure disorder depends upon six factors: 1) dosage; 2) the size of the patient; 3) drug interaction; 4) drug specificity for the disease; 5) the nature of the disease for which the drug is used; 6) the mode and frequency of medication.

Dosage of Anticonvulsant. The dosage of anticonvulsant is very important (Table 2). In our experience, the most common cause of failure in treatment of seizure disorders is undermedication. It is also well known that the anticonvulsants in large enough doses can act as convulsants. This is especially true for diphenylhydantoin, benzodiazepines, and lidocaine. An important factor in dosage of drug is patient reliability. Measurement of blood levels of anticonvulsant can be helpful in this respect (Table 3).

Size of the Patient. The size of the patient should be considered in dosage. Measurement accord-

ing to body surface is safer and more accurate (Table 2). As the child grows, there may be a need to gradually increase the dose of anticonvulsants if seizure control is poor or if the serum level of the anticonvulsant starts to decline.

Drug Interaction. The relationship of multiple drug therapy to its toxic effects on the brain is quite complicated, and many forms of therapeutic failure or toxicity can result.

Combination of Similar Drugs. Failure or toxicity may be the result of a combination of pharmacologically similar drugs. Such a combination may enhance the side effects of drowsiness and ataxia. The patient may suffer from these side effects without attaining therapeutic levels of individual anticonvulsants in the blood. For example, a combination of drugs such as phenobarbital and primidone may result in severe ataxia and drowsiness while measurement of serum levels of phenobarbital and primidone in such patients may show subtherapeutic levels.

The combination of the following pharmacologically similar drugs should be avoided: 1) phenobarbital and primidone, mephobarbital (Mebaral®), and metharbital (Gemonil®); 2) ethosuximide and methsuximide; 3) diphenylhydantoin (DPH) and mephenytoin; 4) trimethadione and paramethadione; 5) benzodiazepines (e.g., combination of diazepam, clonazepam (Clonapin®), chlor-diazepoxide); 6) phenobarbital and ethanol; 7) phenobarbital and benzodiazepines.

Combination of Inducers of Drug Metabolism. This combination may result in less effective

* Presented by Dr. Hooshmand at the 27th Annual Stoneburner Lecture Series, February 7, 1974, at the Medical College of Virginia, Richmond.

** This study was supported by a grant from Hoffman La-Roche Co.

TABLE 1
A Simple Classification of Seizure Disorders*

1. Focal (partial)
 - a. cortical
 - b. subcortical
 - c. both cortical and subcortical
2. Generalized
 - a. low threshold (e.g. drug withdrawal, toxic-metabolic, benign febrile seizures)
 - b. secondary to focal

* Any of the above may be clinical or subclinical (EEG manifestation).

therapeutic doses of each drug in the blood, and less effective control of seizures, despite toxic side effects.

Whereas the failure may be due to genetic, pharmacological or physiological factors which alter absorption metabolism or excretion of the drug, or the failure may be due to compliance behavior of the patient or to lack of drug specificity for the disease, the clinician may add other anticonvulsants which are inducers of drug metabolism and may result in toxicity without control of seizures. The combination may fail to control the seizures, but may result in side effects of drowsiness (1) and/or hyperactivity, also.

For example, diphenylhydantoin (DPH) at 5 mg/kg/day would result in a stable blood level of the drug (2); however, an occasional patient on the same dosage may represent marked blood accumulation of the drug and toxicity (3), while others on the same dosage may reveal very low drug levels and poor

TABLE 2
Dosage, Therapeutic Drug Levels, Indications, and Side Effects of Routinely Used Anticonvulsants

	Indications	Average Daily Dose (ED 50)	TD 50 (Toxicity) (mg/kg)	Safety Range (TD/ED)	Serum Level [†] Therapeutic Range	Skin Rash Leukopenia	Hyper- activity
DPH (Dilantin®)	F, G, S	5 mg/kg (0.3 g/sqM)	20	4	10-20 µg/ml	±	±
Phenobarbital (Luminal®)	F, G, P, C, S	1.5 mg/kg (0.1 g/sqM)	4.5	3	10-50 µg/ml	±	+++
Primidone (Mysoline®)	L, G	10 mg/kg (0.6 g/sqM)	140	14	4-12 µg/ml	±	+
Ethosuximide (Zarontin®)	P	20 mg/kg (1.2 g/sqM)	150	10	40-100 µg/ml	+	+
Methsuximide (Celontin®)	P, C	10 mg/kg (0.6 g/sqM)	15	1.5	2-7.5 µg/ml	++	+
Trimethadione (Tridione®)	P	20 mg/kg (1.2 g/sqM)	25	1.2	100-1000 µg/ml	+++	+
Diazepam (Valium®)	S, P	2-10 mg IV repeated dose	30	10	150-550 ng/ml	-	++
Clonazepam* Acetazolamide (Diamox®)	S, P, C	0.3 mg/kg	6	20	20-70 ng/ml	-	+++
Carbamazepine* (Tegretol®)	P, PMS	500-750 mg/day 400 mg (children)/day	200	18	10-75 µg/ml	-	-
ACTH	L, G Infantile spasms	1200 mg (adults)/day 40-80 u	23	1.5	4-6 µg/ml	±	+
ED—Effective dose			g/sqM—gram per square body meter				
C—Complex (myoclonic akinetic, focal and gen., "petit mal variant")			TD—toxic dose				
F—Focal seizure			±—Rare				
G—Generalized			+—Infrequent				
L—Limbic (Temporal lobe, etc.)			++—Occasional				
P—Petit mal			+++—Not uncommon				
PMS—Premenstrual seizures			*—Use as anticonvulsant experimental				
S—Status epilepticus			‡—Gross guidelines				

TABLE 3
Measurement of Blood Levels of Anticonvulsants

1. Patient reliability
2. Undermedication and overmedication
(typical and atypical toxicity; acute and chronic toxicity)
3. Drug interaction
4. Seizure aggravation by anticonvulsants
5. Neurologic deterioration due to drugs vs other causes
6. Use of anticonvulsants in hepatic or nephritic patients

seizure control (4). Notwithstanding this variability in individual patients, the clinician may become frustrated with the patient's lack of response to treatment. Without further inquiry as to the cause of this lack of response, the clinician may add subtherapeutic doses of other drug inducers. The combination is apt to fail.

The combination of the following inducers of drug metabolism should be avoided: 1) phenobarbital and antipyrine; 2) phenobarbital and butazones; 3) phenobarbital and diphenylhydantoin (DPH); 4) phenobarbital and gyraseofulvin; 5) chlordiazepoxide and Coumadin®.

Drug interaction is variable from case to case; however, high anticonvulsant levels are achieved of each drug, if the metabolic inducers are not given simultaneously (5). If in some cases a combination of drugs seems to be more effective, it is most likely that subtherapeutic doses of each agent have been used to begin with. This is especially true in combining phenobarbital and DPH.

The combination of phenobarbital and DPH is in vogue. While in occasional patients such a combination may be more rewarding than the individual

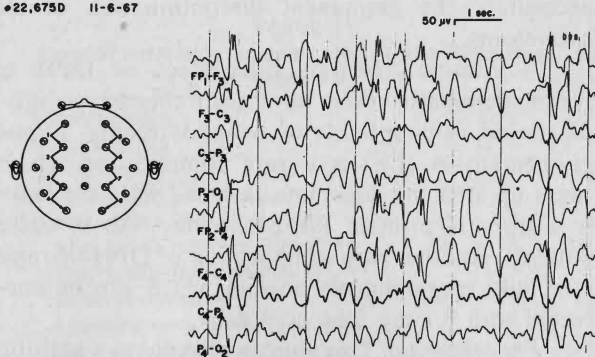
use of phenobarbital or DPH, in our study of 182 patients suffering from focal as well as generalized seizures (Table 4), patients responded better to phenobarbital or DPH alone than to the combination of the two drugs. When the patients were randomly divided into three groups, the group receiving DPH and phenobarbital in combination had more tendency to suffer from side effects of drowsiness and ataxia, and therapeutic levels of the anticonvulsants could not be achieved in most cases without the complications of undesired side effects. The patients who received single anticonvulsants had a higher level of serum anticonvulsants with fewer side effects of drowsiness, poor appetite, and hyperactivity. The patients in the combination group had more rapid control of seizure disorder from the start, but did not fare as well in the long-term follow-up. This was blamed on the fact that the patients on combination therapy did not follow the treatment schedule as religiously as the patients in other groups because of the side effects. The patients receiving individual anticonvulsants had a delay of two-to-five days in complete control of their seizures, but had better control of seizure disorder when followed for a period of over two years (Table 4).

Drug toxicity can be enhanced by the use of *hormones* such as salt-retaining hormones or by the use of *psychotherapeutic drugs* such as phenothiazines. It is a well-known fact that phenothiazines can exacerbate seizures in some patients; this is especially true in patients suffering from limbic system originated seizures. This does not, however, contraindicate the use of phenothiazines in the epileptic patients. The use of some phenothiazine drugs may be absolutely necessary to control the emotional problems which

TABLE 4
Treatment of Focal and Generalized Seizures in 182 Randomly Distributed Patients
Age Range 6-37 Years with a Two-Year Follow-up

	No. of Patients	Mean Blood DPH ($\mu\text{g/ml}$)	Mean Blood Phenobarbital ($\mu\text{g/ml}$)	Therapeutic Failures in Two Years
DPH				
5.0 mg/kg/day	61	11	—	13 (21.3%)
Phenobarbital				
1.5 mg/kg/day	51	—	12.3	16 (27.1%)
Combination	62	6.2	7.1	24 (38.6%)

22,675D 11-6-67



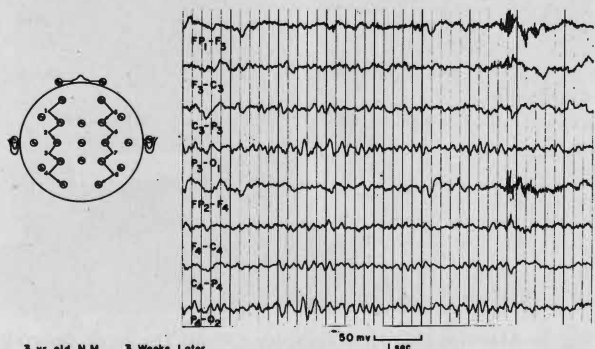
3 yr. old N.M. Measles 2 years of age. Brief episodes of head dropping >100x daily. Dx'd "Petit mal" Rx = Zaronin, Gemonil, Valium, Tridione, Diamox. No Help.

Fig. 1A—Frequent, partial, complex seizures in a three-year-old boy diagnosed as "petit mal" without success.

may be more incapacitating than the seizures themselves. Among the phenothiazines, however, the epileptogenic effect is variable. For example, chlorpromazine (Thorazine®) is a much stronger epileptogenic agent than thioridazine (Mellaril®); the use of the latter drug is more strongly preferred of the two.

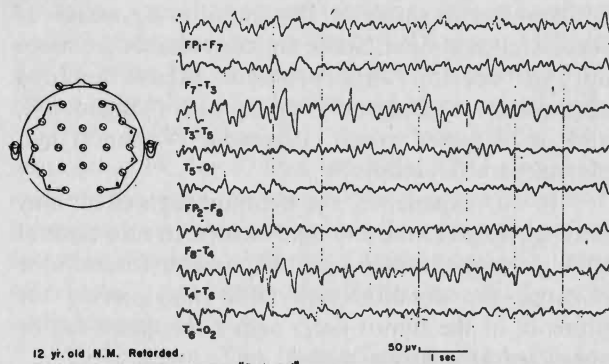
Drug Specificity for the Disease. Whereas in therapeutic doses, anticonvulsants have in common the characteristic of raising the threshold of the seizure discharge, clinical experience has revealed that some of the anticonvulsants are more useful for specific forms of seizures. The review study by Coatsworth (6) has demonstrated that ethosuximide is more effective in the treatment of petit mal. Trimethadione is less effective in petit mal and is not effective in treatment of generalized convulsive seizures. Primidone is more helpful in the treatment of limbic (psychomotor) seizures and is not effective in petit mal seizures. If these guidelines are used, the medical treatment will be more successful (Table 2).

22,675N 11-30-67



3 yr. old N.M. 3 Weeks Later.
No Seizures for One Week. Rx = Methsuximide

Fig. 1B—Methsuximide, 300 mg per day, stopped the seizures.



12 yr. old N.M. Refracted.
Brief Staring Spells Diagnosed as "Petit mal"

Fig. 2—Temporal lobe seizures in a 12-year-old boy misdiagnosed as "petit mal."

It should be kept in mind that an anticonvulsant may be very effective experimentally for a specific form of seizure, but it may have a narrow safety range measured by toxic dose compared to effective dose (7) (Table 2). The toxic side effects will limit the usefulness of such an anticonvulsant. This is true for trimethadione and phenacemide. Phenacemide, an anticonvulsant tried for treatment of temporal lobe seizures, is so toxic that its use is unwarranted (6).

The Nature of the Disease for Which the Drug is Used. Therapeutic failure may be the result of *incorrect diagnosis* such as the treatment of hysterical seizures with anticonvulsants. Other examples may include treatment of psychosensory seizures originating from the temporal lobe, misdiagnosed as petit mal, with medications for petit mal seizure or treatment of complex infantile seizures as "petit mal" seizures (Figs. 1, 2).

Electroencephalography (EEG) can be a priceless tool in confirming the diagnosis. One cannot always rely on clinical expertise and judgment in diagnosis of seizure disorder; EEG must be used as a guideline for accurate diagnosis and treatment.

Accurate diagnosis of etiologic factors in seizure disorder is most important in the treatment of *neonatal seizures*. More than half of these neonatal seizures may be caused by correctable factors such as calcium, magnesium, glucose, or pyridoxine metabolism disturbance (8). If instead of correcting these metabolic disturbances, anticonvulsants in large doses are used, the infant can easily be born toxic.

The problem of the "breakthrough effect" can play a significant role in drug toxicity. This problem refers to the phenomenon of the loss of control of seizures despite adequate therapeutic blood levels of

anticonvulsants after a few months or years of successful treatment. Some anticonvulsants are more apt to develop this problem. These include acetazolamide (Diamox®), nitrazepam (Mogadon®), and, to a lesser extent, diazepam (Valium®) and clonazepam (Clonopin®).

In our experience, the breakthrough effect may also be related to the etiologic factors. In rare cases of slow-growing gliomas with temporal or frontal lobe seizures, the breakthrough effect may herald the presence of the tumor *years before the tumor can be visualized by contrast studies*.

The Mode and Frequency of Medication. The route and the frequency of administration of anticonvulsants plays a role in efficacy and toxicity. The frequency of administration should be approximately equal to the half-life of the drug (which is quite different from one drug to another).

Diphenylhydantoin (DPH). The approximate half-life of DPH in man ranges from 4–50 hours according to various studies. The mean figure is 22 hours. Unfortunately, all patients do not fall in the mean rate of plasma half-life. As a result, single-dose administration of DPH can cause fluctuations of the drug level in the blood in a small number of patients causing confusion in treatment. This method, which apparently can be quite effective in adults (9), can cause some complication in children. In our experience, a single-dose administration of DPH can be irritative to the stomach, causing nausea and vomiting. There is no need, however, of dividing the dosage of DPH to more than two times per day. *This drug should never be given intramuscularly (IM)*, but can be administered intravenously or by mouth; IM use causes necrosis of muscle and DPH is not transferred to the blood from the muscle in any significant therapeutic dose. *DPH should not be mixed with other IV fluids* because it is strongly alkaline.

Long-term administration of over 7 mg/kg of DPH causes lethargy, drowsiness, diplopia, confusion, and ataxia; ataxia and nystagmus are crude signs of toxicity. Rarely, hyperactivity, poor school performance, psychosis, hallucinations, and delusions may result. Hirsutism, seen in three-fourths of all patients taking DPH, is annoying but not serious. Gum hypertrophy is also frequently seen and can become so severe as to necessitate excision.

Morbilliform rash may occur in 2% of patients; in these cases, DPH will have to be discontinued. Even though some patients can later be restarted on the drug, this is a risky practice. The rare complications of blood dyscrasia and hepatitis definitely

necessitate the permanent discontinuation of all hydantoins.

A common benign side effect of DPH is lymphadenopathy. We have seen this to be misdiagnosed as lymphoma or lymphosarcoma. Lupus erythematosus (LE) is a rare complication which clears up after the discontinuation of DPH. The family history is positive for LE in one-fifth of these patients. Another rare complication of DPH therapy is a mild megaloblastic anemia which can be corrected with 0.1 mg folic acid daily.

Phenobarbital. This anticonvulsant has a half-life of three-to-six days in man. As a result, a single daily dose should be efficient and effective. This single dose is best given at bedtime.

The main side effect of this drug is drowsiness and/or aggravation of preexisting hyperactivity. This side effect can be effectively overcome by the addition of methylphenidate (Ritalin®), 10–30 mg in divided doses in the morning and at noon. A scarlatiniform rash may develop in 2% of patients. This necessitates discontinuation of the drug as does allergic erythematosus rash.

Primidone (Mysoline®). This drug has a plasma half-life of 4–19 hours in man with a mean of eight hours. It should not be given as a single dose, and preferably should be given every four-to-eight hours; tolerance to this drug develops slowly.

Diazepam (Valium®). This drug is effective mainly as an anticonvulsant for the control of status epilepticus. It should be given in IV form in frequent doses. The half-life of this drug is not more than three

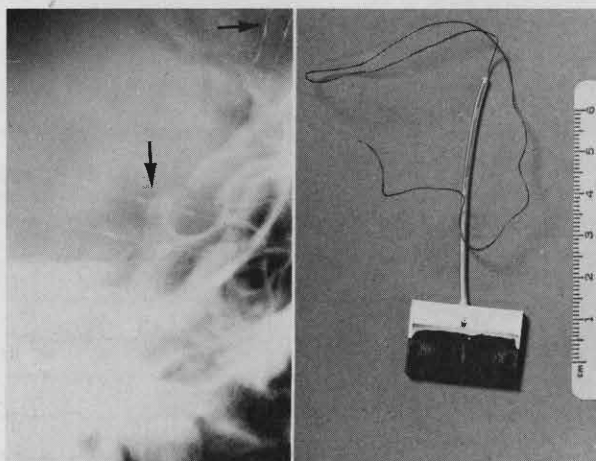


Fig. 3—Manning (16) depth electrode. (Right) The depth electrode with six exposure points 5–10 mm apart. (Left) The electrodes seen in the middle fossa and anterior fossa of the skull. Arrows show points of exposure.

TABLE 5
Cases of Intractable Seizures Excluded After Adjustment of Standard Rx*

Undermedication	6
Drug interaction	4
Drug toxicity	1
Wrong diagnosis and Rx:	
petit mal vs limbic seizures**	4
petit mal vs complex seizures***	5
hyperventilation syndrome	1
conversion reaction	2
1 hypoglycemia, 1 lead poisoning	
and 1 congenital heart disease	3
Total	26

* Of the 70 patients referred for intractable seizure, 26 were satisfactorily treated after correction of diagnosis or adjustment of medication.

** One case treated successfully with primidone alone, three cases with carbamazepine.

*** All five responded favorably to methsuximide.

hours. As a result, frequent injections should be given until the seizure is under control. Diazepam should not be given IM or by mouth for the treatment of status epilepticus; neither should it be mixed with other IV medications; it is most incompatible with most other IV fluids. This incompatibility manifests itself in the form of venous blood coagulation and pulmonary embolus, which may have been the major factor in blaming this drug for the rare complications of respiratory arrest and death that are due to benzodiazepines.

Clonazepam. This is an effective anticonvulsant in the treatment of petit mal as well as complex minor motor seizures (10, 11). Its half-life is five-to-six hours and it should be given by mouth every six hours. The major side effects are drowsiness (when given in toxic doses) and aggravation of hyperactivity. The hyperactivity can be corrected by treatment with methylphenidate (Ritalin®).

Trimethadione. Because of the high tendency for toxicity in the form of skin rash, blood dyscrasias, as well as hemeralopia, and because the diones are not as effective anticonvulsants as succinimides (6), we

TABLE 6
Results of Treatment with Clonazepam in 44 Cases of Uncontrollable Seizures

Type of Seizures	Number of Cases	EEG	Follow-up EEG*	Results of Rx**
Petit mal (absence)	5	Gen. S & W	Infrequent or no S & W; focal S 2 cases; slow background 3 cases	++++ 3 cases ± 2 cases
Photic sensitive	3	Photoconvulsive	Normal	++++
Petit mal status (absence-continuing)	1	Cont. S & W	Slow background	++++
Sylvian	1	Mid-temporal S	Less frequent S	++++
Myoclonic	5	S & W plus frontal or temporal S	No change	+++ 3 cases ± 2 cases
Temporal lobe (psycho-motor, psychosensory)	7	Temporal S	Slightly less frequent S	++++ 4 cases ±*** 3 cases
Focal cortical	4	Focal S (motor 3, Occip. 1)	No change	++ 3 cases ± 1 case†
Akinetic	10	S & W, poly S 8‡ plus frontal 3 temporal S 2 hemispheric 1	±	+++ 6 cases ++ 2 cases ± 2 cases
Complex (akinetic and myoclonic)	7	Focal or gen. multiple spikes	±	± 6 cases ++ 1 case
Infantile spasm	2	Hypsarrhythmia	No change	- 2 cases

S & W—spike and waves

* Low voltage fast activity was invariably present

** 4+ excellent control, -3+ over 75%, 2+ over 50%, + over 25% decrease of seizures, - no change

*** ± temporary effect

‡ Simultaneous EEG anomalies were common

† Expired (meningitis)

TABLE 7
Results of Surgical (Ablation) Therapy in Eight Intractable Seizure Patients
with a Two-to-Eight Year Follow-up

Seizure	X-Ray Findings	Age at Onset of Seizures	Age at Surgery	Procedure	Pathology	Seizure Control* After 2-7 Years
Psychomotor	Neg	8 yrs	14 yrs	temporal lobectomy	glioma III	+++**
Psychomotor	Neg	9 yrs	15 yrs	temporal lobectomy	oligodendro-glioma	+++
Akinetic	Neg	11 yrs	17 yrs	temporal lobectomy	no lesion	+++
Akinetic	Neg	9 yrs	21 yrs	temporal lobectomy	gliosis	++++
Akinetic & adverse	Neg	2 yrs	6 yrs	frontal lobe section	AV malformation	++++
Akinetic & grand mal	Neg	12 yrs	22 yrs	frontal lobe section	gliotic cyst	++++
Complex (akinetic, focal, gen.)	Hemiatrophy	Birth	11 yrs	Hemi-spherectomy	atrophy	++++
Grand mal	R. occip. cyst	1 yr	19 yrs	Removal of cyst	gliosis	±†

* 4+ excellent control, -3+ over 75%, 2+ over 50%, +over 25% decrease of seizures, - No change

** 4 years postop, post Ro-Rx, and post chemo-Rx

† Died of *E. coli* meningitis 13 months postop

have abandoned the use of this drug altogether. The usual dose in children with petit mal is 300-900 mg/-day in two-to-three doses.

Succinimides. At present, ethosuximide (Zarontin®) is the drug of choice for petit mal seizures (6). It can aggravate generalized convulsive episodes in akinetic and temporal lobe seizure patients (12). Because of its long half-life, once- or twice-daily doses should be sufficient. It is metabolized as quickly in children as in adults.

Methsuximide (Celontin®). In our experience,

this has been a very useful drug in the treatment of difficult to control (akinetic, myoclonic, etc.) seizures. One daily dose seems to be sufficient. It has more tendency for toxic side effects than does ethosuximide (Table 2). Phenylsuccinimide, a biproduct of this drug, has a long half-life and can cause deep coma (13).

Carbamazepine (Tegretol®). Because of fluctuation in blood levels, this drug should be administered three-to-four times daily. Blood levels of over 7 µg/ml may result in ataxia, nausea, diplopia, dysarthria, and drowsiness, all dose-related (Table 2).

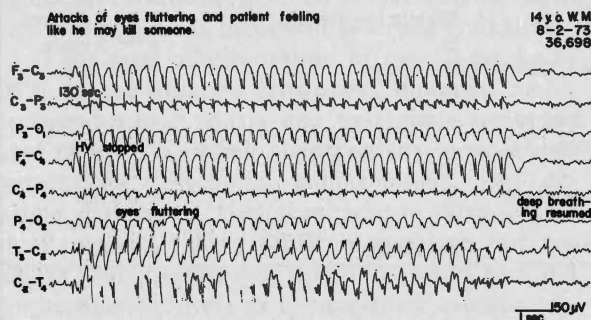


Fig. 4—EEG of 14-year-old boy suffering from psychosensory seizures with concomitant fluttering of eyes. Note 3/sec S&W followed by a left temporal spike transient. Poor response to ethosuximide treatment.

TABLE 8
Outcome of 70 Cases of Difficult Seizure Control with
Two-to-Eight-Year Follow-up

Management	Patients	Successful Rx
Drug adjustment, misdiagnosis	26	23
Clonazepam	44*	27
Surgery	[8]*	6
Total	70	56
Failures—14 cases (20%)**		

* The surgical cases were from the clonazepam failure group.

** The failure rate was decreased from 100% to 20%.

TABLE 9
Results of Medical and Surgical Treatment in 32 Patients
Suffering from Akinetic Seizures*

	Patients	Intractable
Lennox syndrome (age at onset birth- 5 yrs, average IQ 78)	7	5
Complex Akinetic (age of onset 1-12 yrs, average IQ 82) and Myoclonic	18	6
Late Onset Akinetic (age of onset 5-13 yrs, average IQ 89)	7	—
Total	32	11

* Note the relationship of patients' age to the prognostic response to therapy—the later the age of onset of the disease, the better the prognosis.

Rare serious, allergic-type complications of blood dyscrasia, hepatitis, and skin rash may necessitate discontinuation of this drug (14); however, this drug can be quite safe and effective in the treatment of seizure disorders in children (15).

Adrenocorticotrophin (ACTH). This is the drug of choice in infantile spasm. Although it can cause cushingoid features, this side effect is worth coping with. Every-other-day dose decreases this side effect.

Management of Intractable Seizures. The following is our experience with the management of intractable seizures.

Material and Method. Seventy intractable partial seizures were studied and followed for two-to-eight years. Patients who demonstrated the evidence of brain tumor or arteriovenous (AV) malformation on contrast studies were excluded from this study. The 70 patients were evaluated for medical or surgical treatment. Age range was 2-34 years with an average of 14 years. The majority of patients were in childhood and teen-age groups. Thirty-eight were female, 32 were male.

The depth electrode studies were done on the patients who had failed to respond to medical treatment, and regardless of the type of generalized EEG discharges, showed focal spikes in their ictal, interictal, or postictal EEG recordings. Manning (16) depth electrode was used. This is a fine depth electrode, thinner than other types, which can be inserted with little risk of trauma (Fig. 3); its six exposure points,

5-10 mm apart, facilitate recording several points in depth.

The depth studies were performed immediately after contrast studies, psychological tests, as well as an intra-arterial amobarbital test for diagnosis of cerebral dominance. The ventricular air remaining from the air encephalogram was an important guide in locating the position of the depth electrodes. The depth electrode studies consisted of the study of the suspicious focal discharge as well as symmetrical depth electrodes positioned in temporal lobes, frontal lobes, and thalamic nuclei. The temporal lobe electrodes were inserted from the posterior temporal region, advancing towards the amygdaloid nucleus with the tip of the electrodes resting adjacent to this nucleus (Fig. 3). This method would provide a recording from surface to depth, from posterior to anterior aspects of the temporal lobes, and would facilitate localization of the abnormal discharges. An average of ten days-to-two weeks of recordings were done and an attempt was made to record an ictus on depth electrode recording of all patients with the help of all-night EEG recordings or EEG telemetry recordings.

Results. Twenty of the patients were helped by adjustment of standard medical treatment (Table 5). Six patients were found to have been misdiagnosed. This group consisted of one patient with lead poisoning, one with hypoglycemia, and one patient with congenital heart disease.

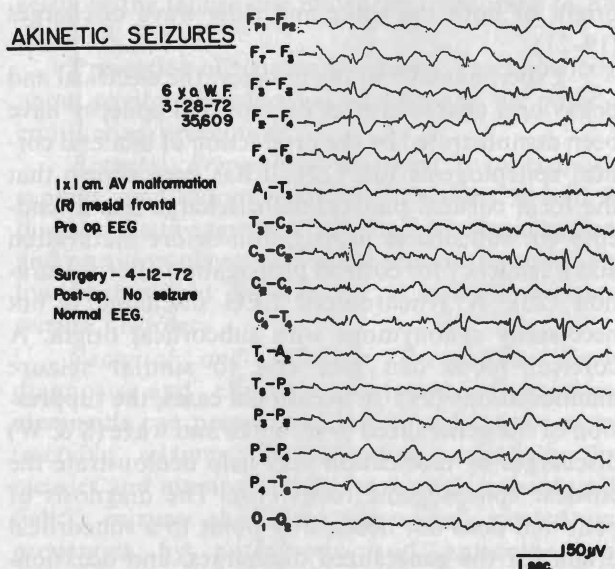


Fig. 5—Six-year-old girl suffering from intractable seizures. Surface EEG recording shows slow S&W. EEG returned to normal after removal of a right mesial frontal AV formation.

The remaining 44 patients were tried on a benzodiazepine—clonazepam (Table 6). This drug was most effective in petit mal, petit mal status, and photosensitive seizures. It was less effective in complex seizures and infantile spasm (hypsarrhythmia).

Of the 27 patients who failed to respond to clonazepam therapy, 15 underwent depth electrode studies. Of these 15 patients, eight eventually had surgical treatment. These eight patients were selected after the depth electrode studies revealed that the epileptogenic focus was the source of the patients' clinical seizures and was amenable to surgical treatment (Table 7).

Despite the fact that repeated angiography and air encephalography performed in intervals as far apart as three-to-six years were negative before operation, with the help of depth electrodes, lesions such as tumors and AV malformation were found at the site of epileptogenic focus (Table 7). The end result was a drop of failure rate from 100% before the study to 20% at the completion of this study (Table 8).

Discussion. The clinical and surface EEG diagnoses are not always accurate. The interictal surface EEG findings do not necessarily correlate with the region of the epileptogenic focus, and may not be localizing in even half of the partial, adverse, or controversial seizures (17, 18). Simultaneous depth and surface recordings in patients with petit mal epilepsy reveal inconclusive data regarding the site of origin of both the spike and slow wave discharges (19–21).

Experimentally in the monkey, the electrical and behavioral characteristics of petit mal epilepsy have been demonstrated by the production of bilateral cortical epileptogenic foci (22). It has been shown that the focal cortical paroxysmal discharge has a tendency for subcortical propagation before maturation and a tendency for cortical propagation after maturation (23). A synchronized EEG discharge is not necessarily synonymous with subcortical origin. A cortical focus can give rise to similar seizure manifestations (29). In occasional cases, the suppression of the generalized 3/sec spike and wave (S & W) discharges by medication may help demonstrate the cortical epileptogenic focus (10). The diagnosis of petit mal does not necessarily point to a subcortical origin for the generalized discharges, and occasionally, a limbic system focus may mimic the petit mal attacks (Fig. 4). The limbic system has been demonstrated to extend to subcortical structures as

well (30). Even in the cases of "typical petit mal," the generalized S & W on EEG may be accompanied by complex behavior and automatism which may be environmentally influenced (31, 32). They may be accompanied by increased or decreased postural tone of the body (31, 32). The above may explain the complexity of the subject partial seizures and the problem of misdiagnosis or incorrect treatment.

A large number of patients in this study (Tables 6, 7) suffered from akinetic seizures. This form of seizure (33–35) may be accompanied by slow S & W discharges on EEG—the "petit mal variant" (36, 37). The akinetic and atonic seizures seem to form a syndrome variable in etiologies as well as in EEG findings. The "Lennox syndrome" (37), a name which has been used synonymously for these seizures, is characterized by 1) *age of onset*, usually below six years of age; 2) *complex seizure manifestations*, such as akinetic and myoclonic seizures; 3) *retardation*; 4) *resistance to treatment*; and 5) *generalized slow S & W discharges plus other abnormalities* in three-fourths of cases (38, 39). Whereas this syndrome comprises the majority of akinetic seizures in young children who are also retarded, it does not encompass the entire spectrum of akinetic seizures.

When the akinetic seizures occur in the older age patients, or in patients who do not have other aspects of Lennox syndrome (such as retardation), the prognosis seems to be more favorable. This is reflected clearly in our study of 32 akinetic seizure patients (Table 9). The EEG findings, usually that of slow S & W discharges in Lennox syndrome, may demonstrate focal discharges in older age patients (40–44). Our depth electrode studies confirm cortical origin of the epileptogenic focus in some of these patients (Figs. 5, 6; Table 7).

Depth electrode studies may be very helpful in care of seizure patients if the following minimal criteria are met: 1) the use of the *thinnest possible depth electrodes*; 2) a *suggestion of focal discharges* on surface recording; 3) the confirmation of cerebral dominance by intra-arterial *amobarbital test* before any surgical procedure; and 4) the *recording of the ictal event* from the surgically resectable epileptogenic focus.

In our experience (Table 7), repeated negative contrast studies over the years do not rule out the possibility of brain tumor or AV malformation as the cause of seizure disorder (Fig. 5). Crandall (45), in his experience with depth electrode studies in seven intractable partial seizures, noted one patient suffering

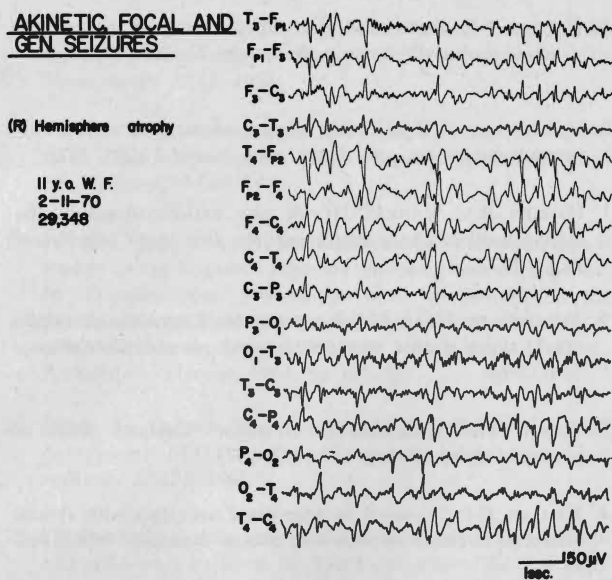


Fig. 6A—Eleven-year-old girl with intractable seizures and left-sided hemiplegia since birth. Surface EEG recording shows bilateral multispikes.

from corpus callosum astrocytoma who suffered from attacks of becoming rigid and falling backward as well as psychomotor seizures. This patient, along with another patient who had a small meningeal angioma, had negative contrast studies. Page et al.

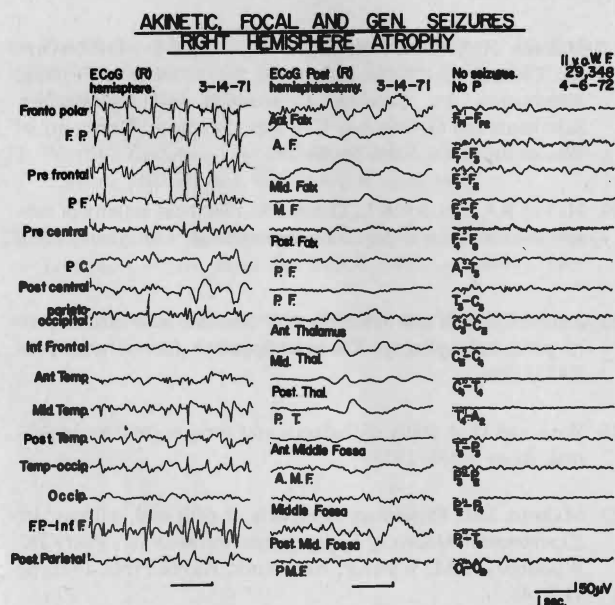
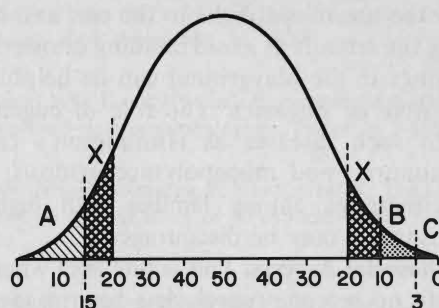


Fig. 6B—Electrocortigraphy (ECOG) before and after hemispherectomy. Right-postoperative surface EEG shows no more spikes. Patient is seizure free. No more need for anticonvulsant therapy.

SEIZURE PATIENTS (%)



- A UNDER-MEDICATION ; OR WRONG TREATMENT
- B TOXICITY ; OR WRONG DIAGNOSIS
- C SURGICAL TREATMENT ; PROGRESSIVE LESIONS
- X PARTIAL CONTROL

Fig. 7—Comparison of the results of therapy among seizure patients referred to the seizure control clinic. As noted, undermedication and overmedication comprise the majority of failure cases.

(46), while underlining the importance of brain tumor as the causative factor in rare cases of childhood seizure disorders, emphasized the fact that a change of seizure pattern in EEG or in behavioral school performance should make one suspicious of the possibility of brain tumor as the causative factor.

It is concluded that with adjustment of treatment, accurate diagnostic work-up, trial of new anticonvulsants, and surgical therapy for partial seizures, the failure rate may drop from 100% to 20% (Table 8, Fig. 7).

Prevention of Seizure Disorders. The knowledge about seizure disorders has advanced to the point of considering prevention.

Prenatal Prevention. Maternal toxoplasmosis, syphilis, and cytomegalovirus infections should be diagnosed and aggressively treated. Maternal hygiene and nutrition play a role in the size of the child. The low birth-weight children are at risk for neonatal seizure disorders.

Neonatal and Infantile Prevention. Early diagnosis and effective treatment of neonatal meningitis can prevent the late complications of intractable seizures. Immunization, especially for measles and mumps, should be strongly encouraged. Febrile seizures should be aggressively treated and prevented by antipyretic and anticonvulsant (phenobarbital) therapy to prevent mesial and temporal anoxic damage and subsequent late-onset temporal lobe seizures.

Prevention of Head Injury. Prevention of head injury by the use of seat-belts in the car, and by encouraging the schools to avoid building cement floors under swings in the playground can be helpful.

The Role of Eugenics. The role of eugenics is limited to such diseases as Huntington's chorea, phenylketonuria, and mucopolysaccharidosis; however, intermarriage among families with high risk seizure disorders may be discouraged.

Psychosocial Aspects. This is one area where unfortunately no recent progress has been made. The general public still has a medieval attitude toward epileptics. More education for the public as well as for health officials is needed.

Acknowledgment: I would like to thank Dr. Donald Becker for the contribution of his surgical skill which helped make this research work possible.

REFERENCES

1. GUEY J, CHARLES C, COQUERY C, ROGER J, SOULAYROL R: Study of psychological effects of ethosuximide (Zarontin®) on 25 children suffering from petit mal epilepsy. *Epilepsia* 8:129, 1967.
2. KUTT H: Biochemical and genetic factors regulating Dilantin® metabolism in man. In: Drug metabolism in man. Ed. Vessel ES, *Ann NY Acad Sci* 179:704, 1971.
3. KUTT H, WOLK M, SHERMAN R, MCDOWELL F: Insufficient parahydroxylation as a cause of diphenylhydantoin toxicity. *Neurology* 14:542, 1964.
4. KUTT H, HAYNES J, MCDOWELL F: Some cases of ineffectiveness of diphenylhydantoin. *Arch Neurol* 14:489, 1966.
5. MORSELLI PL, RIZZO M, GARATTINI S: Interaction between phenobarbital and diphenylhydantoin in animals and in epileptic patients. *Ann NY Acad Sci* 179:88, 1971.
6. COATSWORTH JJ: Studies on the clinical efficacy of marketed antiepileptic drugs. DHEW Publication No. (NIH) 73-51, 1971.
7. MILLICHAP JG: Relation of laboratory evaluation of clinical effectiveness of antiepileptic drugs. *Epilepsia* 10:315, 1969.
8. COCKBURN F, BROWN JK, BELTON NR, FORFAR JO: Neonatal convulsions associated with primary disturbance of calcium, phosphorus, and magnesium metabolism. *Arch Dis Child* 48:99, 1973.
9. HAERER AF, BUCHANAN RA: Effectiveness of single daily doses of diphenylhydantoin. *Neurology* 22:1021, 1972.
10. HOOSHMAND H: Intractable seizures—treatment with a new benzodiazepine anticonvulsant. *Arch Neurol* 27:205, 1972.
11. HANSEN RA, MENKES JH: A new anticonvulsant in the management of minor motor seizures. *Dev Med Child Neurol* 14:13, 1972.
12. LORENTZ DE HAAS AM, KUILMAN M: Ethosuximide (alpha ethyl, alpha methyl succinimide) and grand mal. *Epilepsia* 5:90, 1964.
13. KARCH SB: Methsuximide overdose. Delayed onset of profound coma. *JAMA* 223:1463, 1973.
14. KILLIAN JM: Tegretol® in trigeminal neuralgia with special reference to hematopoietic side effects. *Headache* 9:58, 1969.
15. SCHEFFNER D, SCHIEFER I: The treatment of epileptic children with carbamazepine. Follow-up studies of clinical course and EEG. *Epilepsia* 13:819, 1972.
16. MANNING GC JR: A new miniature contact electrode for subcortical recording and stimulation. *Electroencephalogr Clin Neurophys* 17:204, 1964.
17. LAVY S, CARMON A, YAHR I: Assessment of a clinical and electroencephalographic classification of epileptic patients in everyday neurological practice; a survey of 450 cases. *Epilepsia* 13:498, 1972.
18. HECAEN H, GASTAUT H, BANCAUD J, REBUFAT-DESCHAMPS M: Clinical and EEG aspects of the problem of cortical localization. In: *Cerebral Localization and Organization*. Schaltenbrand G, Woolsey CN, Eds., Madison, University of Wisconsin Press, 1964, pp 67-88.
19. HAYNE RA, BELINSON L, GIBBS FA: Electrical activity of subcortical areas in epilepsy. *Electroencephalogr Clin Neurophysiol* 1:437, 1949.
20. APIEGEL EA, WYCIS HT, REYES V: Diencephalic mechanisms in petit mal epilepsy. *Electroencephalogr Clin Neurophysiol* 3:473, 1951.
21. WILLIAMS D: A study of thalamic and cortical rhythms in petit mal. *Brain* 76:50, 1953.
22. MARCUS EM: Experimental models of petit mal epilepsy. In: *Experimental Models of Epilepsy*. Eds. Purpura DP, Penry JK, Woodbury DM, Water P, New York, Raven Press, 1972, pp 113-146.
23. CAVENESS WF, ECHLIN FA, KEMPER TL, KATO M: The propagation of focal paroxysmal activity in the macaca mulatta at birth and 24 months. *Brain* 96:757, 1973.

24. PETSCHÉ H, STERC J: The significance of the cortex for the traveling phenomenon of brain waves. *Electroencephalogr Clin Neurophysiol* 25:11, 1968.
25. PETSCHÉ H, RAPPELSBERGER P, TRAPPL R: Properties of cortical seizure potential fields. *Electroencephalogr Clin Neurophysiol* 29:567, 1970.
26. PETSCHÉ H, SCHINKO H, SEITELBERGER F: Neuropathological studies on van Bogaert's subacute sclerosing leucoencephalitis. In: Encephalitides; proceedings of a symposium on the neuropathology, electroencephalography, and biochemistry of encephalitides, Antwerp, 1959; Eds. van Bogaert L, et al., Amsterdam, Elsevier, 1961, pp 363-385.
27. COHN R, LEADER HS: Synchronization characteristics of paroxysmal EEG activity. *Electroencephalogr Clin Neurophysiol* 22:421, 1967.
28. LEHMANN D: Human scalp EEG fields: Evoked, alpha, sleep, and spike-wave patterns. In: *Synchronization of EEG Activity in Epilepsies*. Eds. Petsche H, Brazier MAE, Berlin, New York, Springer-Verlag, 1972, pp 307-326.
29. AJMONE MARSAN C, RALSTON BL: *The Epileptic Seizure*. Springfield, Thomas, 1957.
30. LIVINGSTON KE, ESCOBAR A: Anatomical bias of the limbic system concept. A proposed reorientation. *Arch Neurol* 24:17, 1971.
31. PENRY JK, DREIFUSS FE: Automatisms associated with the absence of petit mal epilepsy. *Arch Neurol* 21:142, 1969.
32. PENRY JK: Behavior and generalized spike-waves. In: *Epilepsy—Its Phenomena in Man*. Ed. Brazier MAE, New York, Academic Press, 1973.
33. WEST C: *Lectures of the Diseases of Infancy and Childhood*. 3rd Edition, Philadelphia, Blanchard & Lea, 1860.
34. HUNT JR: On the occurrence of status seizures in epilepsy. (abstract) *J Nerv Ment Dis* 56:351, 1922.
35. LENNOX WG, LENNOX MA: *Epilepsy and Related Disorders*. Vol. 1, Boston, Little, Brown & Company, 1960.
36. GIBBS FA, GIBBS EL, LENNOX WG: Influence of the blood sugar level on the wave and spike formation in petit mal epilepsy. *Arch Neurol* 41:1111, 1939.
37. LENNOX WG, DAVIS JP: Clinical correlates of the fast and slow spike-wave electroencephalogram. *Pediatrics* 5:626, 1950.
38. SCHNEIDER H, VASSELLA F, KARBOWSKI K: The Lennox syndrome—a clinical study of 40 children. *Europ Neurol* 4:289, 1970.
39. BLUME WT, DAVID RB, GOMEZ MR: Generalized sharp and slow wave complexes—associated clinical features and long-term follow-up. *Brain* 96:289, 1973.
40. THARP BR: Orbital frontal seizures. A unique electroencephalographic and clinical syndrome. *Epilepsia* 13:627, 1972.
41. GASTAUT H, ROGER J, SOULAYROL R, TASSINARI CA, REGIS H, DRAVET C, BERNARD R, PINSARD N, SAINT-JEAN M: Childhood epileptic encephalopathy with diffuse slow spike-waves (otherwise known as "petit mal variant" or Lennox syndrome). *Epilepsia* 7:139, 1966.
42. PENFIELD W, JASPER H: *Epilepsy and the Functional Anatomy of the Human Brain*. Boston, Little Brown & Company, 1954, p 269.
43. MAZARS Y, MAZARS G, GOTUSSO C, MERIENNE L: Place de l'épilepsie cingulaire dans le cadre des épilepsies focales corticales. *Rev Neurol (Paris)* 114:225, 1966.
44. BANCAUD J, TALAIRACH J, BONIS A, SCHAUB C, SZIKLA G, MOREL P, BORDAS-FERER M: *La stéréoelectro-encéphalographie dans l'épilepsie*. Paris, Masson, 1965, p 321.
45. CRANDALL PH: Depth EEG in partial seizures. In: *Epilepsy—Its Phenomena in Man*. Ed. Brazier MAE, New York, Academic Press, 1973, pp 287-310.
46. PAGE LK, LOMBROSO CT, MATSON DD: Childhood epilepsy with late detection of cerebral glioma. *J Neurosurg* 31:253, 1969.

Radical Reconstruction of Complex Cranio-Orbito-Facial Abnormalities*

JOHN A. JANE, M.D., Ph.D. and MILTON T. EDGERTON, M.D.

*Departments of Neurosurgery and Plastic Surgery,
University of Virginia, School of Medicine, Charlottesville*

Introduction. The two possible justifications for surgery in craniosynostosis are first, to allow room for the growing brain, thus preventing damage to developing neural structures and second, to prevent or correct deformity. There is considerable doubt about the extent to which the first consideration is valid. Objective signs of increased intracranial pressure are rarely seen with a single closed suture. This fact, along with the difficulty in demonstrating either impairment or improvement in psychological functioning following single suture removal, has led to a generally negative view toward synostectomy with a closed single suture. On the other hand, there is very little question that multiple suture closure can lead to increased intracranial pressure, and here, early surgery is certainly justified. This ongoing argument about the benefits that might accrue with release of the fused sutures seems to have prevented growth of interest in the purely cosmetic aspects of the procedure. Although there is general agreement that early release gives better long-term results, there has been very little interest in the late effects of synostosis, such as marked frontal bossing or the associated facial deformities like those seen in Figure 1.

We have recently been attempting to reconstruct complex abnormalities involving the skull, orbit, and face at a progressively earlier age. Our cases include such conditions as Apert's and Crouzon's syndromes and single and multiple premature suture closure. We wish to present two illustrative cases, one of a com-

bined unilateral coronal and sagittal synostosis and the other, a Crouzon's syndrome.

Case 1. T. D. was seen at the age of two weeks. He showed (Figs. 1, 2) the typical appearance of a right unilateral coronal combined with a sagittal synostosis. There was considerable frontal bossing on the left side opposite the coronal synostosis, which had resulted in depression of his left orbit. He was

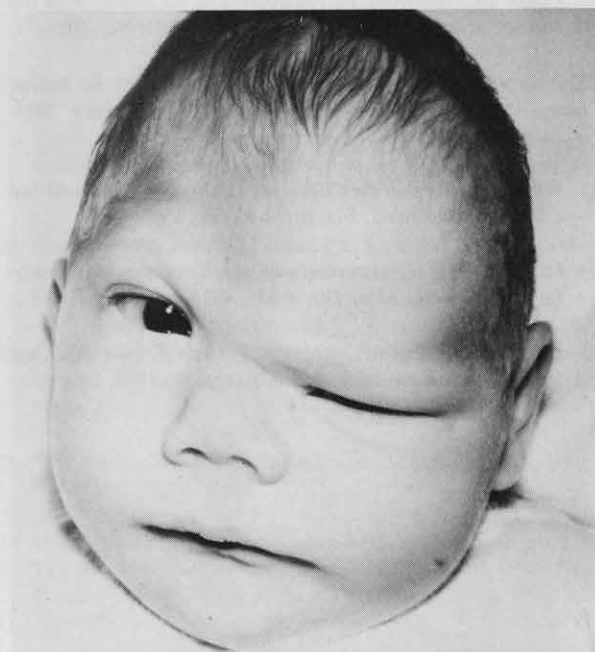

Fig. 1—Case 1 showing flattening of the right brow and depression of the left orbit in the instance of combined right coronal and sagittal synostosis.

* Presented by Dr. Jane at the 27th Annual Stoneburner Lecture Series, February 7, 1974, at the Medical College of Virginia, Richmond.

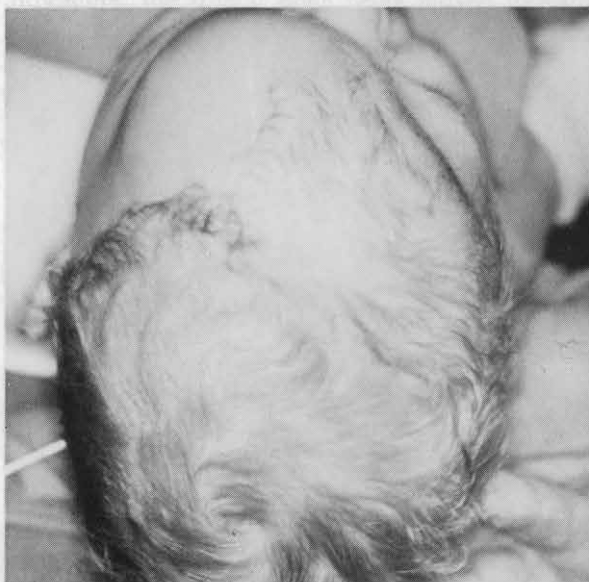

Fig. 2—View from above showing the extent of the left frontal bossing resulting in depression of the orbit.

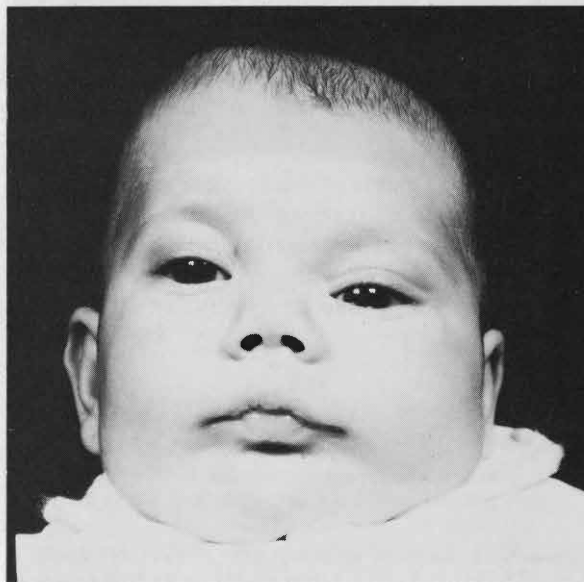

Fig. 3—A postoperative view showing improvement in the skull shape with some residual depression of the orbit.

taken to the operating room where the fused sagittal suture was removed and used to reconstruct the deficient orbital rim on the side of the coronal synostosis. A dural graft also was placed on this side, and the dura was plicated over the side of the frontal

bossing. This resulted in shifting the intracranial contents to the right side with a more normal appearance of the skull. We consider this maneuver of remoulding the dura to be an important step in the long-term results. Figure 3 is a postoperative

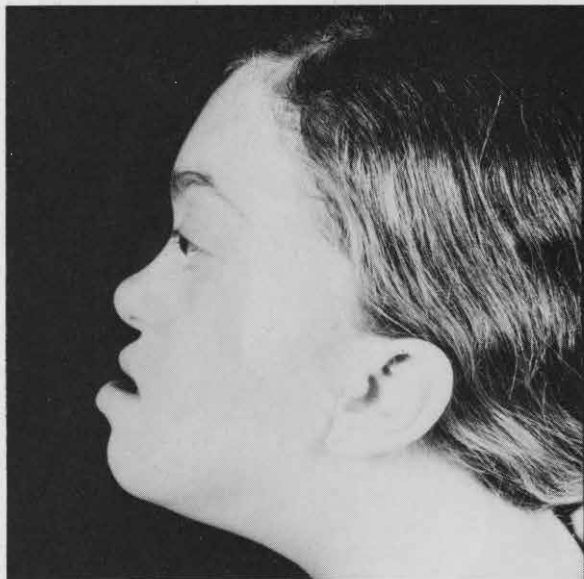
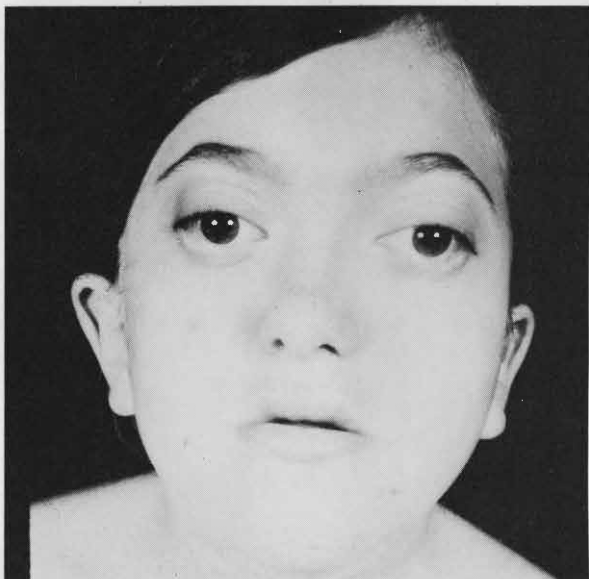
Fig. 4A, B—The typical appearance of Crouzon's deformity with proptosis, underdevelopment of the maxilla, and relative overdevelopment of the mandible.

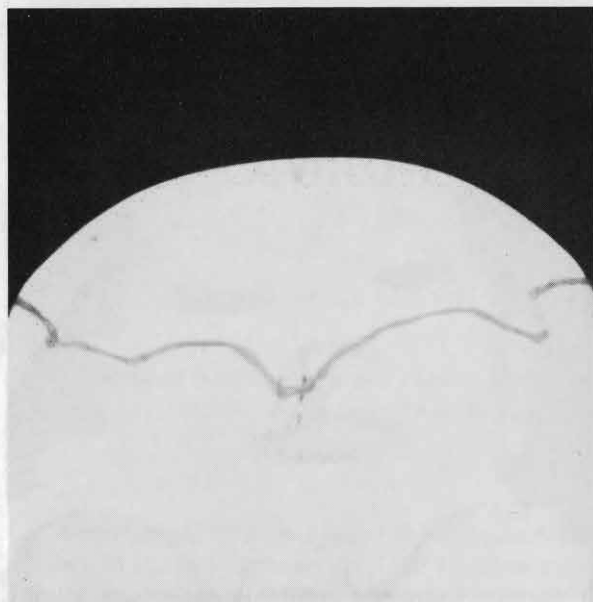


Fig. 5—Cadaver skull showing the point at which the osteotomy is carried out.

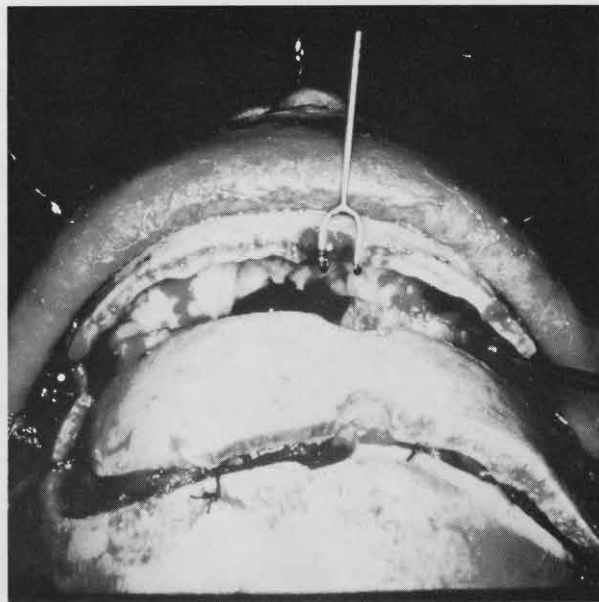


Fig. 6—Operative photograph showing the frontal bone being pulled forward over the orbit.

photograph showing excellent skull shape, although the orbit is still slightly depressed. Facial appearance has continued to improve.

Case 2. Figure 4A, B shows a 13-year-old girl with the typical appearance of Crouzon's disease. There is relative underdevelopment of the maxilla

and overdevelopment of the mandible with proptosis. Our surgical procedure involved a combined intracranial and extracranial approach; one of the procedures used is illustrated in Figure 5. The line across the frontal fossa indicates the cut that is made in the bone. Figure 6 shows the actual operative

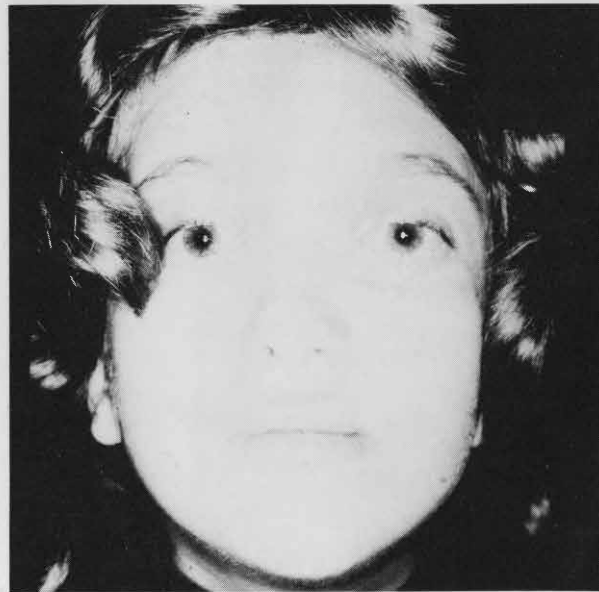
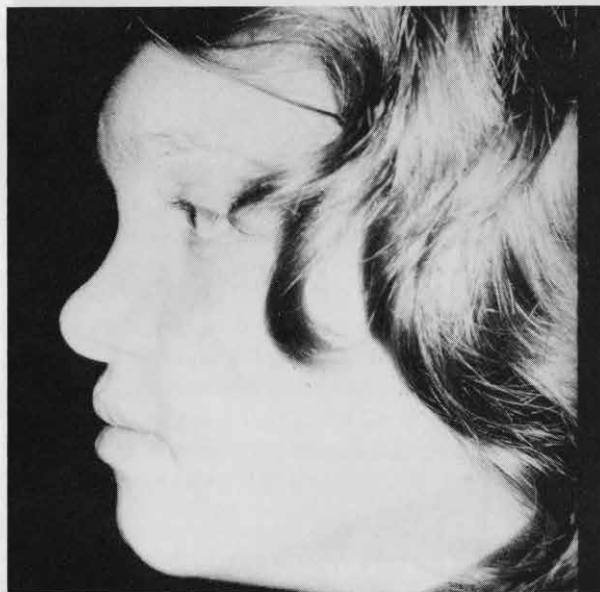
Fig. 7A, B—Postoperative photographs.

procedure, the frontal bone being moved forward over the orbits to relieve the proptosis. Figure 7A, B shows the postoperative results.

Discussion. These procedures are generally long and, particularly when performed on young children, considerable care must be taken in the maintenance of blood volume and humidification of the respiratory system. In the postoperative period, chronic measurement of intracranial pressure has also proven to be most helpful.

The first case illustrates what we think may be an important aspect of the early repair of craniofacial malformation, that is, the question as to whether remodeling of the cranial vault alone, without concomitant remodeling of at least the dura, is sufficient to obtain good late results. It may well be that the underlying brain and dura are the prime factors responsible for the ultimate shape of the cranial vault as has been suggested (1). Experiments in our own laboratory also suggest that this is the case. We have

performed a series of experiments on neonatal hooded rats, in which we have systematically altered the brain or the dura alone or we have altered both together. The findings suggest the importance of the dura and brain in determining skull shape (2).

Summary. Excellent cosmetic results can be obtained by early intervention in severe cranial-orbital-facial deformity. This intervention should take the form of a combined intracranial and extracranial approach. While the procedure is of great magnitude, the benefits to the patient and to the family seem worth the risk.

REFERENCES

1. YOUNG RW: The influence of cranial contents on postnatal growth of the skull in the rat. *Am J Anat* 105:383, 1959.
2. JONES TH, JANE JA: The role of the brain and dura in determining skull shape. (Ms in prep.)

Progress and Problems in the Rehabilitation of Patients with Central Nervous System Injuries*

L. D. AMICK, M.D.

*Professor and Chairman, Department of Physical Medicine and Rehabilitation;
Professor of Neurology, Medical College of Virginia,
Health Sciences Division of Virginia Commonwealth University, Richmond*

The Stoneburner lecturer and other colleagues have discussed diverse pathologies which may create a wide spectrum of lesions and dysfunctions of the central nervous system. Rehabilitation medicine is primarily involved in the care of patients with disabilities of skilled motor performance, which commonly result from neurologic impairment. Additional alterations in performance may be contributed by personality, as well as societal and cultural backgrounds. Rehabilitation is particularly opportune when the diseases causing disability are static, are in prolonged remission, or are only slowly progressing. Central nervous system dysfunction may involve sensory, motor, and cognitive performance as well as psychologic issues. Rehabilitation considered here is the prevention, minimization, and functional compensation for neurologic disability. Rehabilitative principals and methods, such as positioning, padding, and range of motion to avoid decubiti and contractures, with strengthening exercises, and with orthotic and prosthetic devices, usually apply regardless of etiology of the lesions but do not obviate the need for enlightened individuation of therapy and the provision of continuing medical management.

Let us briefly consider the general nature of contemporary rehabilitation with highlights of its

progress and problems. Paraplegia and hemiparesis may be thought of as the models of neurologic impairment.

Psychologists such as Fink, Maslow, and Benton have made brilliant contributions to modern rehabilitation. Their theoretical models of the processes of human adaptation under stress have proved important and useful in dealing with the problems of motivation. A stressful event is a crisis when the patient's normal coping ability is inadequate for the event. A major neurologic catastrophe is such a crisis and is a turning point in the life of a patient (Table 1). After the initial neurologic shock in terms of coma or confusion and atony or areflexia, the patient's awareness brings initial psychologic shock marked by anxiety and/or bewilderment. The initial stages of recovery and improvement of neurologic function favor his hope for further gain, but any considerable persisting disability is usually rejected by the patient as temporary, since he wishes and assumes that structure and function will be fully returned. During this psychologic phase of defensive retreat and relief of anxiety, possibly even to the point of euphoria, it not only is not useful for us to confront the patient with dire facts and probabilities but is even likely to prove deleterious, this is because once we, as therapeutic agents, are associated with anxiety reinforcement, we are less likely to be accepted later as a constructive guiding force. The next psychologic phase of admission or acknowledgment of disability accompanies the completion of any

* Presented by Dr. Amick at the 27th Annual Stoneburner Lecture Series, February 8, 1974, at the Medical College of Virginia, Richmond.

TABLE 1
Crisis and Motivation

Time	Precipitant	Psychologic Phase	Self-Image	Affect and Cognition
↓	Acute somatic damage	Shock	Structural threat	Overwhelming anxiety; cannot plan, understand
	Physical recovery	Retreat	"Regain" structure	Avoids reality; autistic; resists change
	Early plateau	Admission	Give up structure; self-depreciation	Faces imposing reality; depressed ± bitter
	Final plateau	Adaptation	Form new structure; renewed self-worth	New reality, satisfactions; reorganizes resources, future

early improvement and the establishment of an early plateau of disability. The patient now faces reality with reactive depression and possibly self-depreciation or bitterness. During this renewal of stress, therapeutic support may be critical, and it is fitting and useful to emphasize the support and acceptance that the institution and therapists are continuing to provide for the patient. This is based upon the simple dichotomy of Maslow that people have basic safety needs pertaining to food, health, security, and predictable environment, and that these safety needs are a chassis on which are erected the growth needs of greater independence, personal achievement, and creativity. A positive therapeutic environment takes advantage of the final phase of adaptation, occurring when the patient faces the structure of disability combined with residual capability and progresses to the struggle for renewed independence, which will require a different utilization of resources in his life and reorganization for the future. I should like to quote a paraplegic physician and psychiatrist, who says, "Management of spinal cord injury is, today, seriously handicapped by almost exclusive emphasis upon physiologic and pathologic processes. I believe that greater progress in comprehensive care will be achieved when a true integration is reached in physical and psychosocial therapy."

Another major concept that has emerged as an integral part of modern rehabilitation is that of the comprehensive regional rehabilitation center. Standard-bearers exemplifying this approach are Stoke-Mandeville (England) National Paraplegic Center, Georgia Warm Springs Foundation, NYU-Bellevue Institute of Physical Medicine and Rehabilitation, and Rancho Los Amigos, California. This concept is further being supported and tested by the federal government in the recent proliferation of spinal cord

injury centers in this country adding to the preexistent ones in a few VA hospitals. Much significant research and development have emanated from these centers. Virginia is privileged to have three such centers, some of whose contributions will be mentioned, at the McGuire VA Hospital in Richmond, at the Tower Hospital for traumatic paraplegics in Charlottesville, and at the the Woodrow Wilson Rehabilitation Center in Fishersville. A medical school has regional and exemplary functions and should itself, through a department of rehabilitation medicine or through its affiliates, develop a comprehensive rehabilitation center. We have embarked on this course at the Medical College of Virginia.

Another major concept has been evolving at the direct therapeutic level—the concept of organ reserve applied to the brain, sometimes called cerebral plasticity, which contends that surviving cerebral parenchyma may be trained to perform the functions of destroyed tissue. This phenomenon must be distinguished from restored function in temporarily malfunctioning but intact tissue. A good example is found in disability caused by cortical sensory defects. We are familiar with the loss of recognition of objects being handled, a loss of stereognosis, due to a parietal lobe lesion. Ruch and Fulton earlier demonstrated in primates that when one of three principal regions of sensory cortex is ablated there is a marked decrease in stereognosis but, with further training, this function will return. Forster and Shields pointed out the implication that we may retrain patients to recover stereognostic function. Instances of improvement following such retraining in occupational therapy occur, although there are obvious limits to this process.

Closely related to this concept are the various methodic approaches to the physical therapy of voluntary motor dysfunction based upon propriocep-

tive or reflex facilitation. Cohen's experimental results showed that while the effect of such facilitation of the limbs upon cortically induced muscle contractions could be generalized for the whole population, the influence, whether facilitatory or inhibitory, of a given sensory stimulus in a single individual remained consistent under repetitive testing. We are appropriately skeptical of specific "method schools" of therapy, but we welcome the safe, empirical trial of various techniques in some individual patients.

The concept of operant conditioning explored by Skinner and Bachrach is currently in vogue and is being vigorously tested in a number of rehabilitation centers; it essentially supports a learning theory that a voluntary choice or act on the part of patient may be rewarded so that he will choose to repeat the act and thus may eventually perfect it—positive reinforcement of behavior and means of motivation. Benton, Blackburn, and Shankweiler specifically studied motivational influences on performance in brain-damaged patients and controls. Standard retest instructions brought little change but both "urging" instructions and "failure" instructions that told the patient he was not doing well resulted in significant improvements in performance in both groups. There was no breakdown in performance in the face of this degree of stress. By contrast, both instructions to "relax" and "success" instructions telling the patient he was doing very well brought only small or no improvement in performance. They conclude that a complete concept of motivation includes readiness to engage in specific modes of behavior as well as a drive level of sufficient strength to energize that behavior. This internal state of the organism consisting of drive level and behavior-readiness is decisive in determining the possibility and rate of modification of behavior in learning situations.

Let us descend for a moment from the brain to the bladder. Spinal cord injury often disturbs bladder function, and ever after we must also continue to share with the patient a concern for preservation of the upper urinary tract. Urosthesis and insertion of catheters lead to urinary infection which readily ascends. Another renal threat is back pressure from obstruction or vesicoureteral reflux. Cord injury above the conus gives a spastic bladder, called automatic or reflex, that may empty in a sporadic, unpredictable manner either without a catheter or around a catheter. If residual urine is modest, this reflex bladder is satisfactory, particularly in men who learn to use an external collecting appliance. Diffi-

culty arises when spasticity spreads to the external urethral sphincter and blocks urinary outflow. When detrusor pressure dominates over the sphincter, we have a so-called "balanced bladder," whereby we may say that the spasticity which creates a reflex bladder is good. But spasticity which is severe or excessive is apt to involve the sphincter and be unfavorable. In fact, we have learned that decubitus, calculus, infection, and indwelling catheters are potent stimuli to cord facilitation which can lead to excess spasticity and obstruction to urinary outflow. Abramson even contends that the nature of the spasticity after cord injury "seems to be permanently influenced by the consistency with which noxious stimuli arrive at the cord during its (posttraumatic) functional reorganization." The special importance of preventing these early complications becomes obvious. Guttman at Stoke-Mandeville proved that intermittent catheterization from the beginning, never resorting to the indwelling catheter, will keep the urine sterile and so allow greater residual toleration without risk of ascending infection. This has been verified in this country in hospitals where the required but expensive personnel utilization has been funded. Nevertheless, imbalance between detrusor and sphincter tone may occur. Bunts and Hackler at McGuire VA Hospital followed Gibbons' lead to develop the external sphincterotomy to decrease urethral resistance and thus to restore balance. This succeeded in restoring a negligible postvoiding residual urine in 74% of 150 patients, the majority of whom have maintained this good result beyond five years. Given a permanent neurologic defect, the wish to eliminate use of the indwelling catheter, residual urine more than 30 percent of bladder capacity, and a positive sphincterometrogram, Bunts and Hackler favor such surgery without further delay. They have found pudendal neurectomy to be less effective. Regular six-month reevaluations, including cystourethrogram, appear advisable for all paraplegic bladders. If reflux or a small spastic bladder develops, Bunts and Hackler then advise a selective rhizotomy to convert the spastic reflex bladder to a lower motor neuron or flaccid bladder. The latter may be emptied by abdominal contraction or Credé maneuver. They consider surgeries at the ureteral level such as ileal conduit only as a later resort.

Several other research developments are also worth mentioning. Kantowitz implanted a radio-linked bladder stimulator in three male paraplegic

patients with variable results—the electrodes might corrode and might lose their position in the bladder wall, and an effective voltage might close the external sphincter. Grimes (Fig. 1). Nashold, and Currie at Duke University reported last year that they have implanted electronic stimulators (neuroprostheses) directly into the sacral spinal cord itself in five paraplegic patients. One patient had a temporary tendency to autonomic hyperreflexia and male patients obtained penile erection from such stimulation and three patients have maintained good bladders by this means for more than a year. Others have even proposed to restore a functional gait in paraplegic man by programming the electronic stimulation of peripheral nerves in series, intending to produce muscle contractions in a pattern of ambulation. Nooney at MCV has developed a tiny mirror attachment for spectacles to permit awareness of the blind side in homonymous hemianopia. Robinson and Warner at the Yerkes Regional Primate Research Center have evoked certain behavior patterns in monkeys using remote control telestimulation (Fig. 2). In a more extensive study (of electrically controlled behavior in animals, von Holst and von Saint Paul at the Max Plank Institute for the Physiology of Behavior in Seewiesen, Germany, were able with brain electrodes to make the chicken carry out most of the actions of its normal repertory and thus clarify the nature of its drives (Fig. 3). In the upper and lower photograph at the left, a formerly in-

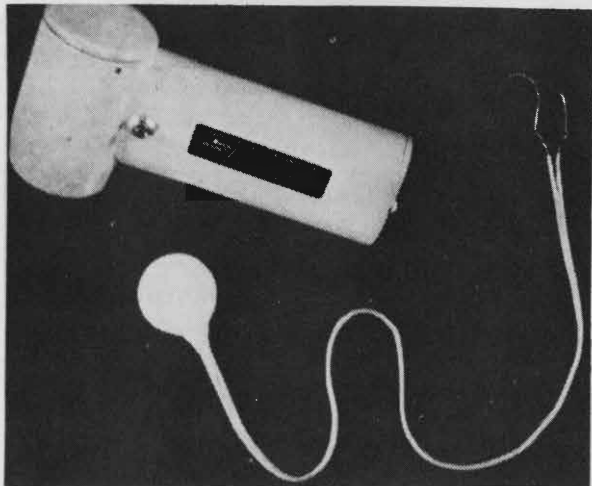


Fig. 1—Implantable stimulator and electrode assembly with portable transmitter.



Fig. 2—Mounting evoked by telestimulation of the lateral hypothalamus.

different rooster was electrically stimulated to attack a small stuffed predator, culminating in attack with spurs and triumphant call. At the right, the same rooster which had always treated the keeper as a friend is shown attacking the keeper's face which appears to be a better substitute for an enemy than her hand. If all substitutes for an enemy are lacking, the rooster exhibits only motor restlessness. They concluded from duplicating various natural drives that stimulation of the brain stem set off essentially complete and normal processes and that effects of stimulation are therefore not imitations or "pseudo-affective" states but genuine drives. "The organism comprises a bundle of drives which support one another or oppose one another to greater or lesser extent. Spontaneous activity is the result of a continual and shifting interplay in forces of the central nervous system." Freedman et al report that electrical stimulation of the septal brain area in humans has halted epileptic seizures, dulled the pain of

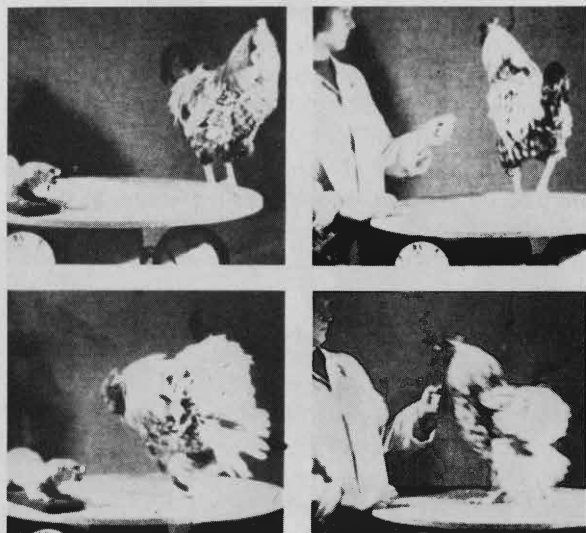


Fig. 3.

cancer, produced sexual pleasure, and brought relief from anger and frustration.

It is difficult to predict what ethical dilemmas future technological developments may bring, but in the sweep of progress, we expect that CNS function will be spared and restored as a result of further breakthroughs in biologic and behavioral research.

BIBLIOGRAPHY

ABRAMSON AS: Modern concepts of management of the patient with spinal cord injury. *Arch Phys Med Rehab* 48:113, 1967.

BACHRACH AJ: Operant conditioning and behavior. In: *The Psychological Basis of Medical Practice*, Ed. Lief Hoeber, 1963, p. 94.

BENTON AL: Motivational influences on performance in brain-damaged patients. (Brain and Behavior, Session II, Symposium, 1959) *Am J Orthopsych* 30(2): 315-21, 1962.

COMARR AE: Practical management of the patient with traumatic cord bladder. *Arch Phys Med Rehab* 48:122, 1967.

DILLER L: Cognitive and motor aspects of handicapping conditions in the neurologically impaired. In: *Rehabilitation Psychology*, Am Psychol Assoc 1971. Proceedings of the National Conference on Psychological Aspects of Disability, Monterey, California, October 25-28, 1970.

FORSTER F, SHIELDS C: Cortical sensory defects. *Arch Phys Med Rehab* 40:56, 1959.

FREEDMEN AM, KAPLAN HI, SADOCK BJ: *Modern Synopsis of Psychiatry*, Baltimore, Williams and Wilkins Company, 1972.

GRIMES JH, NASHOLD BS, CURRIE DP: Chronic electrical stimulation of the paraplegic bladder. *J. Urol* 109:242, 1973.

HACKLER RH: Spinal cord injuries: Urologic care. *Urology* 2:13, 1973.

VON HOLST E, VON SAINT PAUL U: Electrically controlled behavior. *Sci Am* 206:50, 1962.

KANTROWITZ A: Development of an implantable externally controlled stimulator for the treatment of chronic cord bladder in paraplegic patients. *Arch Phys Med Rehab* 46:76, 1965.

NOONEY TW: An optical approach to aid cerebral hemiplegics. *MCV/Q* 8:274, 1972.

ROBINSON BW, WARNER H: Telestimulation of the primate brain. *Arch Phys Med Rehab* 48:467, 1967.

SCHELLHAMMER PF, HACKLER RH, BUNTS RC: External sphincterotomy: Evaluation of 150 patients with neurogenic bladder. *J Urol* 110:199, 1973.


Volume Ten

TABLE OF CONTENTS

1974 • Number One			
<i>Immunology and the Rheumatic Diseases</i>			
Introduction	8	Histocompatibility Antigens and Spondylitis	76
ROBERT IRBY, M.D.		ROBERT IRBY, M.D.	
		WILLIAM EDWARDS, M.D.	
		JAMES PIERCE, M.D.	
		RODERICK MACDONALD, M.D.	
Modern Immunology: Cells and Molecules	9	Juvenile Rheumatoid Arthritis: Early	
FRANKLIN MULLINAX, M.D.		Diagnosis, Management, and Prognosis	82
		JOHN J. CALABRO, M.D., F.A.C.P.	
Recent Advances in Synovial Fluid Analysis	13		
DUNCAN S. OWEN, JR., M.D., F.A.C.P.		A Review of Some Aspects of L-Forms	
		and Gonococci	91
		CHARLES L. COOKE, M.D.	
		BERNARD GERMAIN, M.D.	
		BONNIE BALDUCCI, M.S.	
		HARRY P. DALTON, PH.D.	
Surgery in Rheumatoid Arthritis: General	18		
Indications and Philosophic Considerations		Summary of Papers Presented at the 45th Annual	
R. S. BRYAN, M.D.		McGuire Lecture Series	93
		ROBERT IRBY, M.D., <i>Program Chairman</i>	
Surgical Treatment of the Upper Extremity	21		
in Rheumatoid Arthritis			
CHARLES L. MCDOWELL, M.D.			
Surgical Care of the Lower Extremity in	24		
Rheumatoid Arthritis			
ROBY C. THOMPSON, JR., M.D.			
Diagnostic Concordance of Serological Tests	34		
for Antiglobulin Antibodies			
MARION WALLER, PH.D.			
Still's Disease in Adults	38		
WILLIAM M. EDWARDS, M.D.			
STEPHEN R. KOLLER, M.D.			
MICHAEL J. MILLER, M.D.			
Genetic-Metabolic News	43		
1974 • Number Two			
<i>Immunology and the Rheumatic Diseases</i>			
Introduction	56	<i>Clinical Advances in Medical and Surgical Neurology</i>	
ROBERT IRBY, M.D.		Introduction	100
		DONALD P. BECKER, M.D.	
Viruses and the Connective Tissue Diseases	57	The Interrelationship of Intracranial Pressure,	
MORRIS ZIFF, M.D., PH.D.		Cerebral Blood Flow, and Brain Metabolism in	
		Experimental Brain Injury	101
		THOMAS W. LANGFITT, M.D.	
The "Three R's" of Delayed Hypersensitivity	61		
DAVID HORWITZ, M.D.		Arteriography of Cerebrovascular Disease	108
		FREDERICK S. VINES, M.D.	
Immune Complex Reactions in Systemic	65	The Neuro-Ophthalmology of Cerebrovascular	
Lupus Erythematosus		Disease	114
JOHN STAIGE DAVIS, IV, M.D.		JOHN W. HARBISON, M.D.	
		Medical Management of Cerebral Vascular Disease	118
		WILLIAM K. HASS, M.D.	
		Cerebral Blood Flow Studies in Stroke	123
		JOHN STIRLING MEYER, M.D.	
		Advances in the Surgical Treatment of Patients with	
		Extracranial Cerebral Vascular Disease	128
		THORALF M. SUNDT, JR., M.D.	
Ankylosing Spondylitis	71	Clinical Advances in the Diagnosis of Cerebral	
JOHN BAUM, M.D.		Vascular Disease	134
		JOHN STIRLING MEYER, M.D.	

AMICK, L.D., M.D., 224
BALDUCCI, BONNIE, M.S., 91
BAUM, JOHN, M.D., 71
BECKER, DONALD P., M.D., 100, 166
BRYAN, R. S., M.D., 18
CALABRO, JOHN J., M.D., F.A.C.P., 82
CHEN, ANDREW T.L., PH.D., 163
COOKE, CHARLES L., M.D., 91
DALTON, HARRY P., PH.D., 91
DAVID, R. B., M.D., 205
DAVIS, JOHN STAIGE, IV, M.D., 65
EDGERTON, MILTON T., M.D., 220
EDWARDS, WILLIAM M., M.D., 38, 76
ENGLISH, SUSAN, B.S., 163
GARRETTSON, L. K., M.D., 205
GERMAIN, BERNARD, M.D., 91
HARBISON, JOHN W., M.D., 114, 178
HASS, WILLIAM K., M.D., 118
HERITAGE, DEBORAH W., M.S., 163
HOOSHMAND, HOOSHANG, M.D., 208
HORWITZ, DAVID, M.D., 61
IRBY, ROBERT, M.D., 8, 56, 76, 93
JANE, JOHN A., M.D., PH.D., 220
KOLLER, STEPHEN R., M.D., 38
LANGFITT, THOMAS W., M.D., 101, 167
MCDOWELL, CHARLES L., M.D., 21
MACDONALD, RODERICK, M.D., 76
MEYER, JOHN STIRLING, M.D., 123, 134
MILLER, MICHAEL J., M.D., 38
MULLINAX, FRANKLIN, M.D., 9
OWEN, DUNCAN S., JR., M.D., F.A.C.P., 13
PIERCE, JAMES, M.D., 76
SUNDT, THORALF M., JR., M.D., 128, 146
SUTER, CARY, M.D., 152
TEW, JOHN M., JR., M.D., F.A.C.S., 139
THOMPSON, ROBY C., JR., M.D., 24
VINES, FREDERICK S., M.D., 108, 183
VRIES, JOHN K., M.D., 174
WALLER, MARION, PH.D., 34
WILSON, CHARLES B., M.D., 192, 200
YOUNG, HAROLD F., M.D., 196
YOUNG, REUBEN B., M.D., 163
ZIFF, MORRIS, M.D., PH.D., 57

**after taking a
potent analgesic
360 times
in 3 months...**



Clinical Advisor for

Introduction

Donald P. Becker, M.D.

Clinical Advisor for the

Patients with Severe Pain

Thomas W. Longitt, M.D.

Clinical Advisor for the

Technique and Application

John K. Vane, M.D.

ANNE, L.D., M.D., 328

BAJOVIC, BOBIE, M.D., 31

BAIR, JOHN, M.D., 71

BECKER, DONALD P., M.D., 1

BRYAN, R. S., M.D., 18

CALABRO, JOHN F., M.D., 3

CANE, ANDREW T., M.D., 1

CORRE, CHARLES L., M.D., 1

DARTON, HARRY P., M.D., 1

DAVID, R. B., M.D., 305

DAVE, JUDY STONE, 15

EDMONTON, MILTON L., M.D., 1

ELIASSON, WHITMAN M., M.D., 1

ELIASSON, SUSAN, B.S., 18

ELIASSON, J. K., M.D., 1

ELIASSON, JUDITH, M.D., 1

ELIASSON, JOHN W., M.D., 1

ELIASSON, JOHN W., M.D., 1

ELIASSON, JOHN W., M.D., 1

ELIASSON, JOHN W., M.D., 1

ELIASSON, JOHN W., M.D., 1

ELIASSON, JOHN W., M.D., 1

how big a dose will now bring relief if it is a narcotic?

"Tolerance is an ever-present hazard to continued use of narcotics.... The very first dose diminishes the effects of subsequent doses."¹ And, as increasing amounts of narcotics are required to control pain, distressing adverse effects—lethargy, hypotension, constipation, etc.—can needlessly debilitate the patient.

1. Sadove, M. S.: A look at narcotic and non-narcotic analgesics, *Postgrad. Med.* 49:102, June 1971.

how big a dose will now bring relief if it is Talwin®?

Chances are, the same 50 mg. Talwin Tablet you prescribe originally will continue to provide good pain relief. Talwin can be compared to codeine in analgesic efficacy: one 50 mg. tablet appears equivalent in analgesic effect to 60 mg. (1 gr.) of codeine. However, patients receiving Talwin Tablets for prolonged periods face fewer of the consequences you've come to expect with narcotics. There should be fewer "adverse effects" on her way of life.

Tolerance rare: Tolerance to the analgesic effect of Talwin Tablets is rare.

Dependence rare: During three years of wide clinical use, there have been a few reports of dependence and of withdrawal symptoms with orally administered Talwin. Patients with a history of drug dependence should be under close supervision while receiving Talwin orally.

*In prescribing Talwin for chronic use, the physician should take precautions to avoid increases in dose by the patient and to prevent the use of the drug in anticipation of pain rather than for the relief of pain.**

Generally well tolerated by most patients*: Infrequently causes decrease in blood pressure or tachycardia; rarely causes respiratory depression or urinary retention; seldom causes diarrhea or constipation. Acute, transient CNS effects, described in product information, have occurred in rare instances following the use of Talwin Tablets. If dizziness, lightheadedness, nausea, or vomiting is encountered, these effects may decrease or disappear after the first few doses.

*See important product information for adverse reactions, patient selection, prescribing and precautionary recommendations.

in chronic pain of moderate to severe intensity

Talwin® 50 mg.
Tablets
brand of
pentazocine
(as hydrochloride)

Talwin® Tablets brand of pentazocine (as hydrochloride)

Analgesic for Oral Use—

Indication: For the relief of moderate to severe pain.

Contraindication: Talwin should not be administered to patients who are hypersensitive to it.

Warnings: *Drug Dependence.* There have been instances of psychological and physical dependence on parenteral Talwin in patients with a history of drug abuse and, rarely, in patients without such a history. Abrupt discontinuance following the extended use of parenteral Talwin has resulted in withdrawal symptoms. There have been a few reports of dependence and of withdrawal symptoms with orally administered Talwin. Patients with a history of drug dependence should be under close supervision while receiving Talwin orally.

In prescribing Talwin for chronic use, the physician should take precautions to avoid increases in dose by the patient and to prevent the use of the drug in anticipation of pain rather than for the relief of pain.

Head Injury and Increased Intracranial Pressure. The respiratory depressant effects of Talwin and its potential for elevating cerebrospinal fluid pressure may be markedly exaggerated in the presence of head injury, other intracranial lesions, or a preexisting increase in intracranial pressure. Furthermore, Talwin can produce effects which may obscure the clinical course of patients with head injuries. In such patients, Talwin must be used with extreme caution and only if its use is deemed essential.

Usage in Pregnancy. Safe use of Talwin during pregnancy (other than labor) has not been established. Animal reproduction studies have not demonstrated teratogenic or embryotoxic effects. However, Talwin should be administered to pregnant patients (other than labor) only when, in the judgment of the physician, the potential benefits outweigh the possible hazards. Patients receiving Talwin during labor have experienced no adverse effects other than those that occur with commonly used analgesics. Talwin should be used with caution in women delivering premature infants.

Acute CNS Manifestations. Patients receiving therapeutic doses of Talwin have experienced, in rare instances, hallucinations (usually visual), disorientation, and confusion which have cleared spontaneously within a period of hours. The mechanism of this reaction is not known. Such patients should be very closely observed and vital signs checked. If the drug is re-instituted it should be done with caution since the acute CNS manifestations may recur.

Usage in Children. Because clinical experience in children under 12 years of age is limited, administration of Talwin in this age group is not recommended. *Ambulatory Patients.* Since sedation, dizziness, and occasional euphoria have been noted, ambulatory patients should be warned not to operate machinery, drive cars, or unnecessarily expose themselves to hazards.

Precautions: *Certain Respiratory Conditions.* Although respiratory depression has rarely been reported after oral administration of Talwin, the drug should be administered with caution to patients with respiratory depression from any cause, severely limited respiratory reserve, severe bronchial asthma and other obstructive respiratory conditions, or cyanosis.

Impaired Renal or Hepatic Function. Decreased metabolism of the drug by the liver in extensive liver disease may predispose to accentuation of side effects. Although laboratory tests have not indicated that Talwin causes or increases renal or hepatic impairment, the drug should be administered with caution to patients with such impairment.

Myocardial Infarction. As with all drugs, Talwin should be used with caution in patients with myocardial infarction who have nausea or vomiting. *Biliary Surgery.* Until further experience is gained with the effects of Talwin on the sphincter of Oddi, the drug should be used with caution in patients about to undergo surgery of the biliary tract.

Patients Receiving Narcotics. Talwin is a mild narcotic antagonist. Some patients previously given narcotics, including methadone for the daily treatment of narcotic dependence, have experienced withdrawal symptoms after receiving Talwin.

CNS Effect. Caution should be used when Talwin is administered to patients prone to seizures; seizures have occurred in a few such patients in association with the use of Talwin although no cause and effect relationship has been established.

Adverse Reactions: Reactions reported after oral administration of Talwin include *gastrointestinal:* nausea, vomiting; infrequently constipation; and rarely abdominal distress, anorexia, diarrhea. *CNS effects:* dizziness, lightheadedness, sedation, euphoria, headache; infrequently weakness, disturbed dreams, insomnia, syncope, visual blurring and focusing difficulty, hallucinations (see *Acute CNS Manifestations* under **WARNINGS**); and rarely tremor, irritability, excitement, tinnitus. *Autonomic:* sweating; infrequently flushing; and rarely chills. *Allergic:* infrequently rash; and rarely urticaria, edema of the face. *Cardiovascular:* infrequently decrease in blood pressure, tachycardia. *Hematologic:* rarely depression of white blood cells (especially granulocytes), usually reversible and usually associated with diseases or other drugs which are known to cause such changes, moderate transient eosinophilia. *Other:* rarely respiratory depression, urinary retention, toxic epidermal necrolysis.

Dosage and Administration: *Adults.* The usual initial adult dose is 1 tablet (50 mg.) every three or four hours. This may be increased to 2 tablets (100 mg.) when needed. Total daily dosage should not exceed 600 mg.

When antiinflammatory or antipyretic effects are desired in addition to analgesia, aspirin can be administered concomitantly with Talwin. *Children Under 12 Years of Age.* Since clinical experience in children under 12 years of age is limited, administration of Talwin in this age group is not recommended.

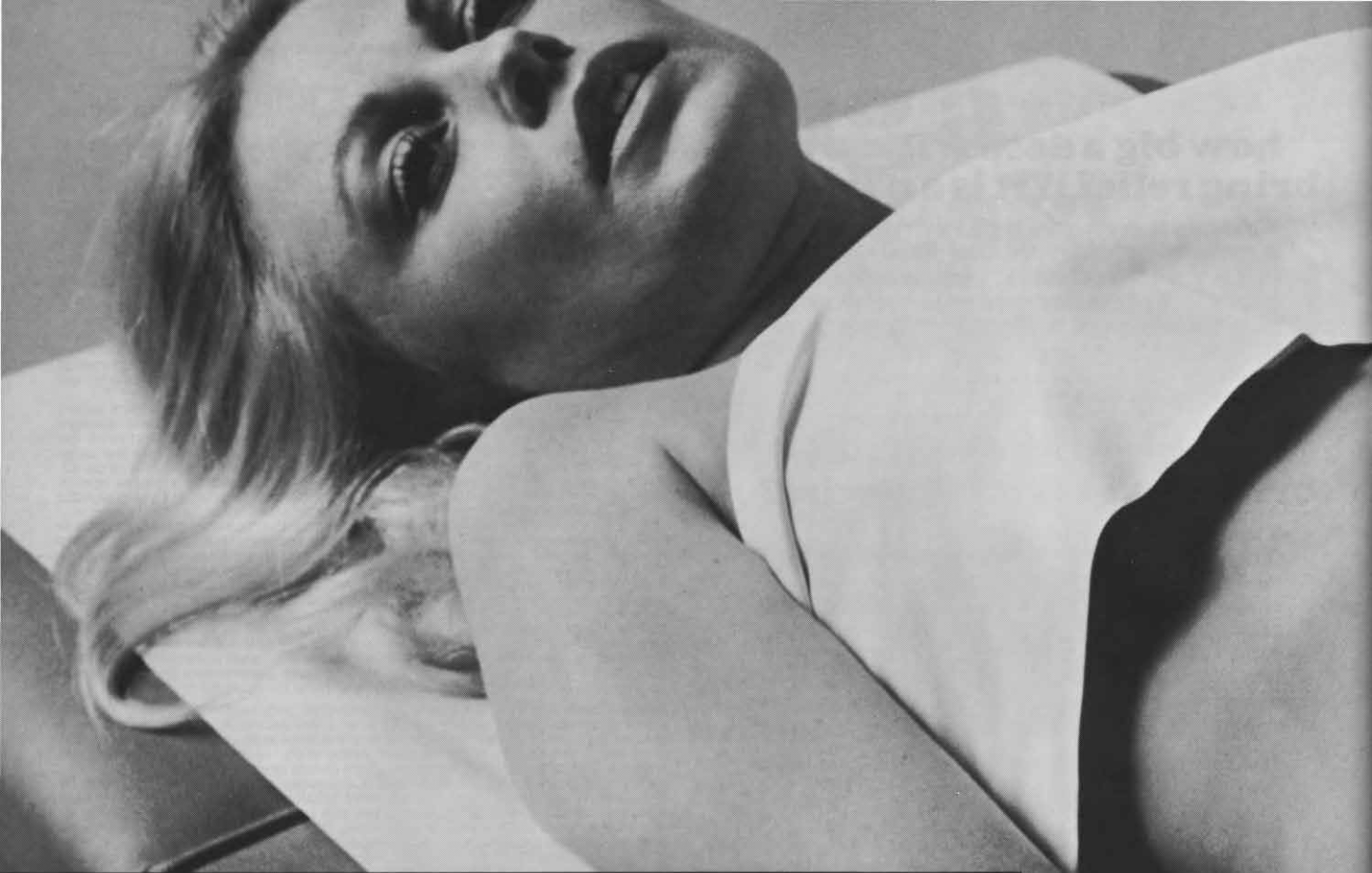Duration of Therapy. Patients with chronic pain who have received Talwin orally for prolonged periods have not experienced withdrawal symptoms even when administration was abruptly discontinued (see **WARNINGS**). No tolerance to the analgesic effect has been observed. Laboratory tests of blood and urine and of liver and kidney function have revealed no significant abnormalities after prolonged administration of Talwin.

Overdosage: *Manifestations.* Clinical experience with Talwin overdosage has been insufficient to define the signs of this condition.

Treatment. Oxygen, intravenous fluids, vasopressors, and other supportive measures should be employed as indicated. Assisted or controlled ventilation should also be considered. Although nalorphine and levallorphan are not effective antidotes for respiratory depression due to overdosage or unusual sensitivity to Talwin, parenteral naloxone (Narcan®, available through Endo Laboratories) is a specific and effective antagonist.

Talwin is not subject to narcotic controls.

How Supplied: Tablets, peach color, scored. Each tablet contains Talwin (brand of pentazocine) as hydrochloride equivalent to 50 mg. base. Bottles of 100.



A service to medical education from A. H. Robins:

Excerpted from Volume 2

of the
G.I. Series

on physical examination
of the abdomen:

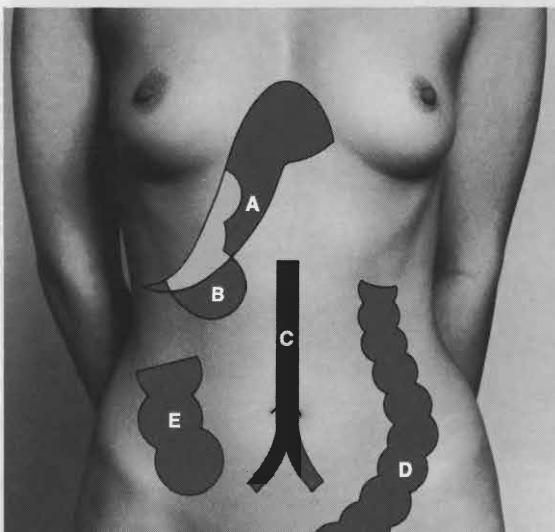
The A. H. Robins G.I. Series consists of six booklets, designed to provide a quick, yet comprehensive review of basic procedures and practices in G.I. medicine—with particular emphasis on the physical examination as performed in the office or at bedside. If you have teaching responsibilities, limited quantities are available: Part 1—*Inspection*, Part 2—*Palpation*, Part 3—*Percussion*, Part 4—*Auscultation*, Part 5—*Abdominal Pain* and Part 6—*Differential Diagnosis of Abdominal Disorders*. Write to: The Medical Department, A. H. Robins Company, 1407 Cummings Drive, Richmond, Virginia 23220



Normally palpable organs:

the edge of the liver descending, on inspiration, below the costal margin (A); the lower pole of the right kidney (B); the abdominal aorta (C); the descending colon and the sigmoid (D); the ascending colon (E); and occasionally the bladder (though rising of this organ beyond the pubis does not necessarily indicate disease).

Impossible to outline, unless diseased, distended or enlarged: the gallbladder, pancreas, stomach, small intestine, transverse colon and spleen.





A service to medical education from A. H. Robins:

Excerpted from Volume 2

of the G.I. Series

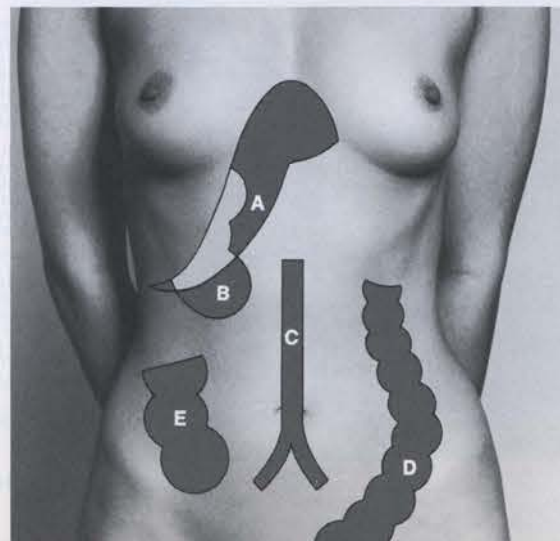

on physical examination
of the abdomen:

Normally palpable organs:

the edge of the liver descending, on inspiration, below the costal margin (A); the lower pole of the right kidney (B); the abdominal aorta (C); the descending colon and the sigmoid (D); the ascending colon (E); and occasionally the bladder (though rising of this organ beyond the pubis does not necessarily indicate disease).

Impossible to outline, unless diseased, distended or enlarged: the gallbladder, pancreas, stomach, small intestine, transverse colon and spleen.

The A. H. Robins G.I. Series consists of six booklets, designed to provide a quick, yet comprehensive review of basic procedures and practices in G.I. medicine—with particular emphasis on the physical examination as performed in the office or at bedside. If you have teaching responsibilities, limited quantities are available. Part 1—*Inspection*, Part 2—*Palpation*, Part 3—*Percussion*, Part 4—*Auscultation*, Part 5—*Abdominal Pain* and Part 6—*Differential Diagnosis of Abdominal Disorders*. Write to: The Medical Department, A. H. Robins Company, 1407 Cummings Drive, Richmond, Virginia 23220.

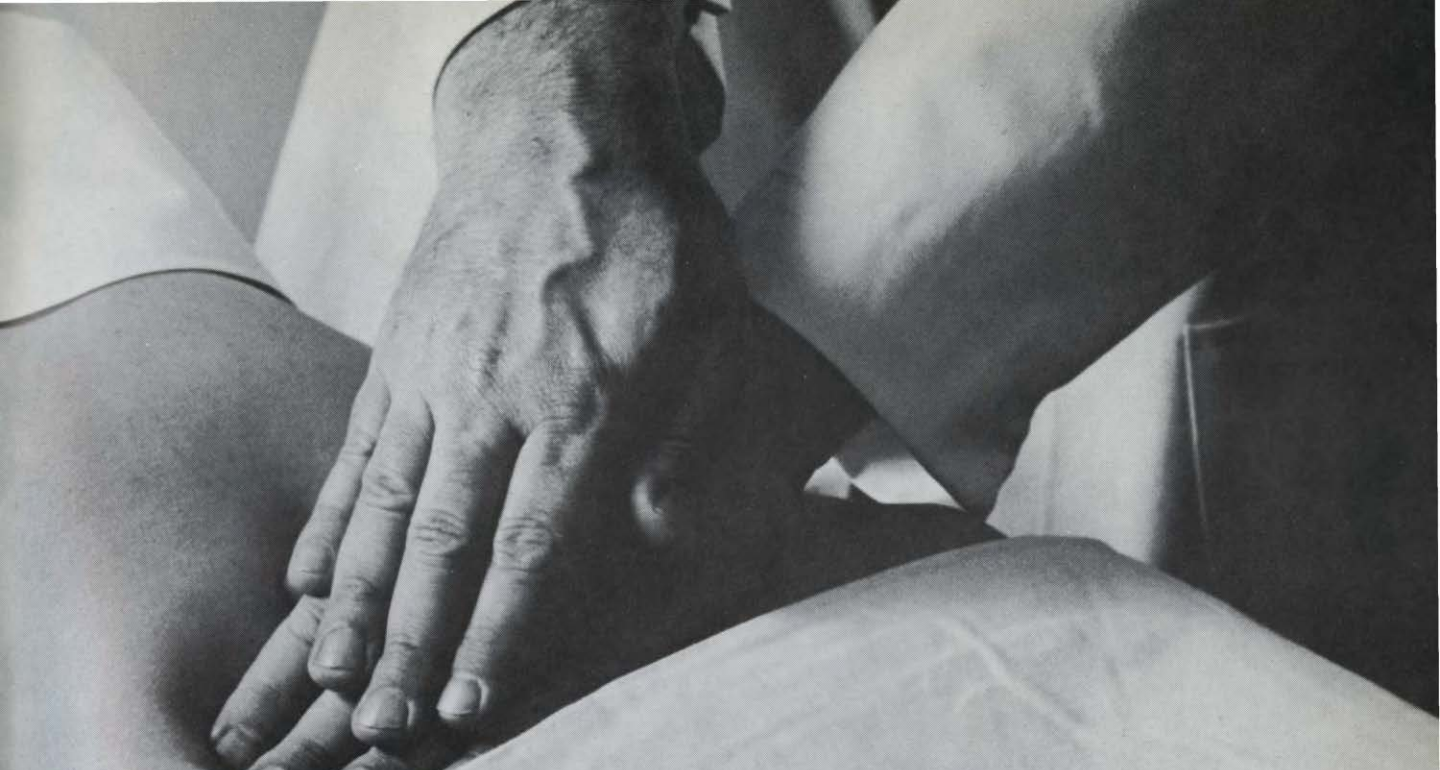

Spasm reactor? Donnatal!

	each tablet, capsule or 5 cc. teaspoonful of elixir (23% alcohol)	each Donnatal No. 2	each Extentab
hyoscyamine sulfate	0.1037 mg.	0.1037 mg.	0.3111 mg.
atropine sulfate	0.0194 mg.	0.0194 mg.	0.0582 mg.
hyoscine hydrobromide	0.0065 mg.	0.0065 mg.	0.0195 mg.
phenobarbital	($\frac{1}{4}$ gr.) 16.2 mg.	($\frac{1}{2}$ gr.) 32.4 mg.	($\frac{3}{4}$ gr.) 48.6 mg.
(warning: may be habit forming)			

Brief summary. Adverse Reactions: Blurring of vision, dry mouth, difficult urination, and flushing or dryness of the skin may occur on higher dosage levels, rarely on usual dosage. Contraindications: Glaucoma; renal or hepatic disease; obstructive uropathy (for example, bladder neck obstruction due to prostatic hypertrophy); or hypersensitivity to any of the ingredients.

A-H-ROBINS A. H. Robins Company, Richmond, Virginia 23220



Spasm reactor? Donnatal[®]!

	each tablet, capsule or 5 cc. teaspoonful of elixir (23% alcohol)	each Donnatal No. 2	each Extentab
hyoscyamine sulfate	0.1037 mg.	0.1037 mg.	0.3111 mg.
atropine sulfate	0.0194 mg.	0.0194 mg.	0.0582 mg.
hyoscine hydrobromide	0.0065 mg.	0.0065 mg.	0.0195 mg.
phenobarbital	(1/4 gr.) 16.2 mg.	(1/2 gr.) 32.4 mg.	(3/4 gr.) 48.6 mg.
(warning: may be habit forming)			

Brief summary. Adverse Reactions: Blurring of vision, dry mouth, difficult urination, and flushing or dryness of the skin may occur on higher dosage levels, rarely on usual dosage. Contraindications: Glaucoma; renal or hepatic disease; obstructive uropathy (for example, bladder neck obstruction due to prostatic hypertrophy); or hypersensitivity to any of the ingredients.

A-H-ROBINS A. H. Robins Company, Richmond, Virginia 23220

Before prescribing, please consult complete product information, a summary of which follows:

Indications: Tension and anxiety states, somatic complaints which are concomitants of emotional factors; psychoneurotic states manifested by tension, anxiety, apprehension, fatigue, depressive symptoms or agitation; symptomatic relief of acute agitation, tremor, delirium tremens and hallucinosis due to acute alcohol withdrawal; adjunctively in skeletal muscle spasm due to reflex spasm to local pathology, spasticity caused by upper motor neuron disorders, athetosis, stiff-man syndrome, convulsive disorders (not for sole therapy).

Contraindicated: Known hypersensitivity to the drug. Children under 6 months of age. Acute narrow angle glaucoma; may be used in patients with open angle glaucoma who are receiving appropriate therapy.

Warnings: Not of value in psychotic patients. Caution against hazardous occupations requiring complete mental alertness. When used adjunctively in convulsive disorders, possibility of increase in frequency and/or severity of grand mal seizures may require increased dosage of standard anticonvulsant medication; abrupt withdrawal may be associated with temporary increase in frequency and/or severity of seizures. Advise against simultaneous ingestion of alcohol and other CNS depressants. Withdrawal symptoms (similar to those with barbiturates and alcohol) have occurred following abrupt discontinuance (convulsions, tremor, abdominal and muscle cramps, vomiting and sweating). Keep addiction-prone individuals under careful surveillance because of their predisposition to habituation and dependence. In pregnancy, lactation or women of childbearing age, weigh potential benefit against possible hazard.

Precautions: If combined with other psychotropics or anticonvulsants, consider carefully pharmacology of agents employed; drugs such as phenothiazines, narcotics, barbiturates, MAO inhibitors and other antidepressants may potentiate its action. Usual precautions indicated in patients severely depressed, or with latent depression, or with suicidal tendencies. Observe usual precautions in impaired renal or hepatic function. Limit dosage to smallest effective amount in elderly and debilitated to preclude ataxia or over-sedation.

Side Effects: Drowsiness, confusion, diplopia, hypotension, changes in libido, nausea, fatigue, depression, dysarthria, jaundice, skin rash, ataxia, constipation, headache, incontinence, changes in salivation, slurred speech, tremor, vertigo, urinary retention, blurred vision. Paradoxical reactions such as acute hyperexcited states, anxiety, hallucinations, increased muscle spasticity, insomnia, rage, sleep disturbances, stimulation have been reported; should these occur, discontinue drug. Isolated reports of neutropenia, jaundice; periodic blood counts and liver function tests advisable during long-term therapy.

If there's good reason to prescribe for psychic tension...



When, for example, despite counseling,
tension and anxiety continue to produce
distressing somatic symptoms

Prompt action is a good reason to consider Valium[®] (diazepam)

2-mg, 5-mg, 10-mg tablets



Roche Laboratories
Division of Hoffmann-La Roche Inc.
Nutley, N.J. 07110