



2016

Analysis of Radiographic Changes Associated with the Periradicular Diagnosis of Symptomatic Apical Periodontitis

Preeti Batra
VCU, batrap@vcu.edu

Follow this and additional works at: <http://scholarscompass.vcu.edu/etd>

 Part of the [Endodontics and Endodontology Commons](#)

© The Author

Downloaded from

<http://scholarscompass.vcu.edu/etd/4141>

This Thesis is brought to you for free and open access by the Graduate School at VCU Scholars Compass. It has been accepted for inclusion in Theses and Dissertations by an authorized administrator of VCU Scholars Compass. For more information, please contact libcompass@vcu.edu.

© Preeti Batra, BDS 2016

All Rights Reserved

Analysis of Radiographic Changes Associated with the Periradicular Diagnosis of Symptomatic Apical Periodontitis

A thesis submitted in partial fulfillment of the requirements for the degree of
Master of Science in Dentistry at Virginia Commonwealth University

By

Preeti Batra

BDS, United Medical Schools of Guys and St. Thomas' Hospitals, 1997

Thesis Director: Karan J. Replogle, DDS, MS
Assistant Professor, Department of Endodontics

Virginia Commonwealth University
Richmond, Virginia
May 2016

Acknowledgements

The author wishes to thank several people. I am grateful to Drs. Replogle, Gunsolley, Archer, and Best for their help and guidance with this project. I would like to thank my co-residents and clinical staff for their support during this process.

Lastly I would like to thank my husband, Manpreet, and our children, who have been so patient and supportive over the past two years. I could not have done this without the love and encouragement from my family.

Table of Contents

List of Tables	v
List of Figures	vi
Abstract	vii
Introduction.....	1
Materials and Methods.....	7
Results.....	11
Discussion	22
References.....	32
Appendices	37

List of Tables

1. Study Demographics	11
2. Distribution and Frequency of Teeth Included in Study.....	12
3. Objective Test Results	13
4. Frequency of Pulpal Diagnosis by Number and Percentage of Teeth	14
5. Weighted Kappa Statistical Analysis Ranges	15
6. Periapical Radiolucency in Relation to Tooth Type.....	16
7. Tooth type and Relative Position by Size	17
8. Diagnosis and Endodontic Test Results Versus Periapical Radiolucency Size.....	18
9. Vital and Non-Vital Pulp Diagnoses and Presence or Absence of Periapical Radiolucency ..	20

List of Figures

1. Chart Representation of the Prevalence of Pulpal Diagnosis in SAP 15
2. Scatterplot Matrix Showing High Correlation Between Two Measures 17
3. Contingency Analysis of Presence/Absence of PARL and PARL size by Pulp Diagnosis 20

Abstract

ANALYSIS OF RADIOGRAPHIC CHANGES ASSOCIATED WITH THE PERIRADICULAR DIAGNOSIS OF SYMPTOMATIC APICAL PERIODONTITIS

Preeti Batra, B.D.S

A thesis submitted in partial fulfillment of the requirements for the degree of Master of Science in Dentistry at Virginia Commonwealth University.

Virginia Commonwealth University, 2016

Major Director: Karan J. Replogle, DDS, MS, Assistant Professor, Department of Endodontics

Symptomatic apical periodontitis (SAP) is indicative of inflammation of the periodontal ligament. It may or may not be accompanied by radiographic changes and may occur with vital or necrotic pulpal diagnosis. Purpose of this study was to analyze clinical and radiographic presentations of SAP in a retrospective electronic dental chart and digital radiograph review utilizing the endodontic diagnostic template note of predoctoral dental school patients presenting with SAP. The aim was to determine prevalence of periapical radiolucencies (PARLs) in SAP, association of SAP to pulpal diagnosis, and define associated radiographic changes. Most prevalent pulpal diagnosis with SAP was symptomatic irreversible pulpitis (44%). A tooth presenting with SAP was more likely to have an intact lamina dura, but presented with a PARL 38% of the time. When a PARL was present the most common pulpal diagnosis was pulp necrosis however, 24.5% of teeth presented with a vital pulp diagnosis and lesions <2mm.

Introduction

Diagnosis has been defined as the art and science of detecting and distinguishing deviations from health and the cause and nature thereof (1). Arriving at an endodontic diagnosis involves the culmination of subjective information, clinical and radiographic examination, thorough periodontal evaluation and clinical testing. This process is necessary to determine a pulpal and periapical diagnosis and thus provide the cornerstone upon which treatment decisions are based. Endodontic diagnosis has been likened to a jigsaw puzzle - a diagnosis cannot be made from one single piece of information (2).

Diagnostic terminologies have been debated for years with an evolution of classifications used in endodontics. Historically histologic terms were used to classify pulpal disease on a clinical basis (3). This intertwining of terminology was often misleading and led to confusion, and incorrect diagnoses. In 1965 Seltzer was critical of redefining a classification based on histologic terms that may not accurately depict the actual condition of the pulp and supporting periodontal tissues, and that was not useful to the clinician rendering treatment (4). Diagnostic terminologies continued to evolve and most recently in 2008, the American Association of Endodontists (AAE) convened a *Consensus Conference on Diagnostic Terminology* in an attempt to standardize the terminology used for classification of pulpal and periapical disease conditions.

The periapical diagnoses include apical periodontitis, which is an inflammatory process of the periodontium around the tooth apex. It occurs as a response to microbial infection of the pulp space within teeth (5). It can be further classified as symptomatic apical periodontitis and asymptomatic apical periodontitis, depending upon presentation of clinical symptoms. In 2009, the American Association of Endodontics and American Board of Endodontics (ABE) approved the current diagnostic terminology for pulpal and periapical diagnoses including the following definition for symptomatic apical periodontitis (SAP): “Symptomatic Apical Periodontitis represents inflammation, usually of the apical periodontium, producing clinical symptoms involving a painful response to biting and/or percussion or palpation. This may or may not be accompanied by radiographic changes.” There may be normal width of the periodontal ligament or there may be a periapical radiolucency depending upon the stage of the disease. Severe pain to percussion and/or palpation is highly indicative of a degenerating pulp and root canal treatment is needed (6).

Apical periodontitis is a remarkably prevalent disease that increases with age, affecting one in two individuals by 50 years of age (7). Patients with symptomatic apical periodontitis often present with an intense, pounding, spontaneous and localized pain (8). Presence of symptomatic apical periodontitis does not indicate that the tooth is vital or non-vital, but is rather an indication of inflammation in the periodontal ligament.

Endodontic research provides evidence that the major etiological cause of apical periodontitis is bacteria (9, 10). The primary route of infection of the pulpal tissue is by caries. Once caries has invaded the pulp space an acute inflammatory response occurs, which leads to the establishment

of necrotic foci followed by microbial colonization in the coronal pulp. This advancing front of inflammation followed by necrosis proceeds in an apical direction. In areas of transition between necrotic and vital pulp tissue a gradient of tissue reaction is seen. Infected necrotic tissue will be adjacent to areas of acute inflammation, which in turn lies next to areas of chronic inflammation with vital tissue underlying the areas of inflammation (11). Histological observations show that radiographic changes such as enlargement of the periodontal ligament space or even a distinct periapical radiolucency appear when necrosis/infection has reached the radicular pulp (12-15). In these cases an inflammatory continuum forms involving the apical pulp and periapical tissues. Paradoxically it is not necessary for total pulp necrosis and infection to be established at the apical foramen for apical periodontitis to develop (12, 14, 15). Periradicular changes can be detected before this happens. If a vital pulp becomes infected due to caries or other pathways, periapical inflammation can develop even when inflamed but vital tissue is still present in the apical portion of the root canal. In fact, apical periodontitis has been demonstrated to be a direct extension of apical pulpitis into the periapical tissues before total pulp necrosis.

Kovacevic and colleagues studied the transition from pulpitis to apical periodontitis by artificially producing apical periodontitis in an animal model. It was demonstrated that acute periapical periodontitis begins during pulpitis (16). Two independent studies, Yamasaki and group and Stashenko and colleagues, showed that periapical inflammatory infiltrates, increased osteoclast numbers and bone destruction were apparent well in advance of total pulp necrosis, with vital pulp tissue still present in the apical portion of the root canal (17, 18). Microbial byproducts and toxins diffuse through the inflamed apical pulpal tissue to the periapical tissues and cause pathological changes. Development of symptomatic apical periodontitis largely

reflects the innate immune system and is the first line of active defense against irritants from the root canal. The host immune response can be considered a double-edged sword as it is both protective and destructive. In one respect, it attempts to contain the irritants and protect against infection and prepares the injured site for repair. However, it also can result in unwanted effects such as pain and intense tissue damage resulting in bone loss and the development of a lesion that can be seen radiographically.

Radiographic examination forms an essential part of the testing armamentarium used in formulating a diagnosis, and in the evaluation of outcome of teeth with apical periodontitis. At present in clinical practice periapical radiographs are the most common modality used to evaluate for periapical lesions (19). The radiographic diagnosis of apical periodontitis is based on deviations from the normal periapical anatomy. The inflammatory process that originates within the pulp transgresses through the pulpal space into the surrounding periapical tissues and bone. Apical periodontitis lesions comprise soft tissues occupying the periapical space that was previously occupied by bone tissue. Resorptive and bone remodeling activities in response to the inflammation are the main causes of changes that become visible on the radiograph. The periodontal ligament, the lamina dura, cancellous and cortical bone, and the root itself may all be affected by the biological activities of apical periodontitis (20).

Generally when endodontic pathology can be detected on a radiograph, it appears as bone loss in the area of the periapex. Pre-operative periapical radiographs are assessed to estimate the size and extent of periapical radiolucencies prior to treatment. In a study by Kaffe in 1988, he stated the most consistent radiographic feature aiding diagnosis of the periapical condition of teeth was

a break in or the widening of the lamina dura when a tooth is necrotic (21). In addition the 2001 Spring/Summer endodontics: Colleagues for Excellence insert titled *Systematic Pulpal Diagnosis* stated, “Pathologic vital pulps are not visible on radiographs” and goes on to state “if a radiolucency is in the periradicular region of a tooth with a vital pulp, it cannot be of pulpal origin and will be either a normal structure or another type of pathosis” (22). These findings support the idea that suspected radiographic lesions of pulpal origin are likely to be non-vital. However, Langeland demonstrated histologically that the pulp in the apical portion of the root canal, in lateral canals and in apical ramifications remain vital and often uninfamed, even in the presence of a radiolucency (23, 24). In a more recent histological study by Ricucci vital tissue with varying degrees of inflammation were observed in the apical portion with periradicular radiolucencies in one third of specimens (15).

Radiography is not a perfect diagnostic tool, partly because radiographs are two-dimensional representations of three-dimensional structures, and partly because particular clinical and biological features may not be reflected in radiographic changes. The presence of a lesion may not be directly evident and its real extent and the spatial relationships to important anatomical landmarks are not always easily visualized (20). Bony pathology and its radiographic visibility have considerable variability based upon the relative position of the root to the cancellous/cortical bone around it. Historically the belief was that radiographic changes from bone loss would not be detected if the bone loss was confined within cancellous bone (25). Radiographic evidence of pathosis would be observed once bone loss extends to the junction of the cortical and cancellous bone, as was illustrated by Bender and Seltzer (26). Independent studies by Paurazas, and Barbat support the findings of these classic studies by Bender and

Seltzer reporting that lesion detection occurred with significantly greater accuracy in cortical bone than in trabecular bone, as well as when the cortical plate was involved (27, 28). However, a study by Lee and Messer counters these findings by demonstrating that periapical radiolucencies confined to cancellous bone were detected in 80% of cases (29). Despite limitations of periapical radiographs and their limited capacity to show small bone lesions, a systematic review by Petersson states that periapical radiographs have a high capacity to identify normal periapical conditions (30).

With the duplicity of presentation of periapical radiolucency in the recognized diagnosis of symptomatic apical periodontitis and the histological evidence that periapical radiolucency may exist in the presence of vital pulp this study was conducted. The purpose of this study was to analyze the clinical and radiographic presentation of teeth with the diagnosis of symptomatic apical periodontitis. The aim was to determine the prevalence of periapical radiolucencies in SAP, the association of SAP to pulpal diagnosis and to define the radiographic changes associated with SAP.

Materials and Methods

This study is a retrospective electronic dental chart and digital radiograph review of patients presenting with SAP utilizing the endodontic diagnostic template note used by predoctoral dental students in the School of Dentistry at Virginia Commonwealth University. The Institutional Review Board of Virginia Commonwealth University, Richmond, Virginia, approved this study (IRB # HM20003432).

Virginia Commonwealth University School of Dentistry (VCU SoD) uses the dental software program axiUm™ for its electronic dental charting and MiPACS™ for its digital radiographs. All predoctoral dental students enter diagnostic testing results into a standardized endodontic diagnostic template note (see Appendix A).

The initial data sample group consisted of all endodontic diagnosis templates entered for patients who presented to the predoctoral clinics at the VCU SoD over a 3 year time period from July 2012 to June 2015. The subjects' axiUm™ dental records were queried to record their chart number, age, gender, and date of endodontic diagnosis. Application of initial exclusion criteria resulted in the removal of all subjects under 18 years old and subjects who were pregnant.

The study population was further reduced to include only completed template notes that included a periapical diagnosis of SAP. The recorded endodontic test results included in the template were then assessed for positive results to percussion and/or palpation to confirm the diagnosis of SAP. Any endodontic template notes containing inconsistent test results were removed from the data set. The resultant study population was comprised of 1418 template notes.

Evaluation of the existence of a periapical radiograph taken at the time of completion of the diagnostic template note was carried out using MiPACS™. If no periapical radiograph was found with the date corresponding with the date of the template note the tooth was excluded from the study. The tooth was assessed for presence or absence of a periapical radiolucency. If present, it was measured using measurement tools included in the MiPACS™ software. A PARL was defined as being two times the width of the periodontal ligament space. Each radiograph was calibrated using specific known values to ensure accuracy of measurements.

In summary, during initial data collection exclusion criteria applied including were the following:

- Removal of subject if axiUm™ chart was inaccessible
- Removal of subject where inconsistencies were found in patient personal details, for example: the extracted data indicated subject was male, however when axiUm™ was accessed using their chart number, the records indicate the subject was female
- No diagnostic periapical radiograph was taken on the day the template note was completed

Radiographic interpretation resulted in further refinement of the study population. Subjects were excluded for the following reasons:

- The tooth in question was not included in the radiograph
- The tooth apex or the periapical radiolucency was not captured in the radiograph
- Radiograph was not clear and interpretation was not possible
- The radiographic image had been imported and therefore, could not be calibrated

As data collection continued a few subjects presented with periapical radiolucencies associated with other etiology such as Perio-Endo lesions, or bone loss associated with mesioangular impaction of the lower third molar. These subjects were also excluded from this sample population.

In the final data analysis further charts were excluded due to an observation of multiple entries for the same patient presenting with SAP affecting the same tooth at different times. Only the template note for the first presentation was included. If a periapical radiolucency spanned two or more apical areas of a multi-rooted tooth the subject was excluded. This was a rare occurrence in the data set and thus could not be adequately evaluated. The final population sample comprised 963 teeth with SAP in 927 patients. Thirty-six subjects had two teeth that were included in the data set. Since this was a rare occurrence in the data set, the analysis of the data was conducted with no adjustment of within subject effects.

A second year endodontic resident and 2 dental students carried out the radiographic evaluation. The students were initially trained and provided with guidelines for standardized radiographic

interpretation (see Appendix B). Calibration exercises and inter-rater reliability tests were conducted for all examiners prior to starting the radiographic data collection. It was decided that all 3 evaluators were calibrated to read radiographs of anterior teeth only. Two examiners read radiographs of all other teeth. Calibration exercises were carried out every 50 radiographs and inter-rater reliability tests were carried out at regular intervals throughout the data collection phase. Approximately 10% of the final population size was used for calibration and inter-rater reliability assessment. A fourth examiner, a board certified endodontist, evaluated any radiographs that resulted in disagreement or required another opinion.

The electronically downloaded data from axiUm™ and all radiographic findings were recorded and analyzed using SAS software (JMP version 11, SAS Institute Inc., Cary, NC). Subjects had a non-identifying number assigned to them. The number assigned was keyed to the subjects' dental record number that was kept separately so as to avoid HIPAA violations. The de-identified spreadsheet included pulpal diagnosis, presence and size of PARL, tooth number, age, gender, and results of endodontic testing. Results were first summarized using counts and percentages or means and standard deviations, as appropriate. Agreement between categorical variables was described using the Kappa coefficient corrected for chance agreement and correlations are summarized using the Spearman rank correlation. Analyses first focused on each clinically prognostic characteristic and its relationship to either the presence or absence of a PARL and to the size of the PARL using chi-square analyses. Size of lesions were grouped as no lesion, 0-2mm, 2-5mm, and >5mm. If significant, multiple testing between diagnoses for their odds ratios were calculated in a logistic regression model and adjusted with Bonferroni correction.

Results

The results of the study are presented in sections. The first section reports the demographics and presents descriptive statistics of the study data. The second section discusses the calibration between radiographic evaluators. In the subsequent section the association between individual characteristics and the size of the periapical radiolucency are explored. In the final section the results of combined analyses are addressed.

Demographic characteristics

The study population after exclusion criteria had been applied was comprised of 927 patients with 963 teeth diagnosed with SAP. Of this patient sample 58.5% were female and 41.5% were male. The average age was 46 years (SD = 16.9, range = 18 to 96 years).

Table 1. Study Demographics

Total number of patients	927	100 (%)
Female	542	58.5
Male	385	41.5

The distribution of teeth by tooth type showed molars to be the most frequently occurring tooth, followed by premolars, and then anterior teeth. Distribution by specific tooth type was determined. Mandibular left and right first permanent molars were the most frequently occurring paired teeth (#19 and # 30 at 18.5%). They were followed by teeth #4 and #13 at 13.4%. Teeth

#3 and #14 at 13.3%, #18 and 31 at 10.9%, and #5 and #12 at 10.3%. Table 2 shows the prevalence of tooth type in pairs for the entire sample.

Table 2. Distribution and Frequency of Teeth Included in Study

Tooth type and matched pairs	Occurrence (%)
Molars	49.7
Lower Molars	39.8
19 & 30	18.5
18 & 31	10.9
17 & 32	0.4
Upper Molars	19.9
3 & 14	13.3
2 & 15	6.5
1 & 16	0.1
Premolars	35.0
Lower Premolars	11.3
21 & 28	2.0
20 & 29	9.3
Upper premolars	23.7
5 & 12	10.3
4 & 13	13.4
Anteriors	15.3
Lower Anteriors	2.2
22 & 27	0.7
23 & 26	1.0
24 & 25	0.5
Upper Anteriors	13.1
6 & 11	2.8
7 & 10	4.5
8 & 9	5.8

Objective data recorded at the time of diagnosis is shown in Table 3. A diagnosis of SAP required positive percussion and/or palpation. From the data it can be seen that 94.3% of teeth were tender to percussion and 38.8% palpation positive. In this data N varies for each diagnostic test as it depends upon complete data from the diagnostic note.

Table 3. Objective Test Results

Diagnostic test	Response to diagnostic test			
	Positive (+)		Negative (-)	
	N	%	N	%
Percussion	899	94.3	54	5.7
Palpation	369	38.8	582	61.2
Cold	581	62.5	348	37.5
Mobility	18	1.9	907	98.1

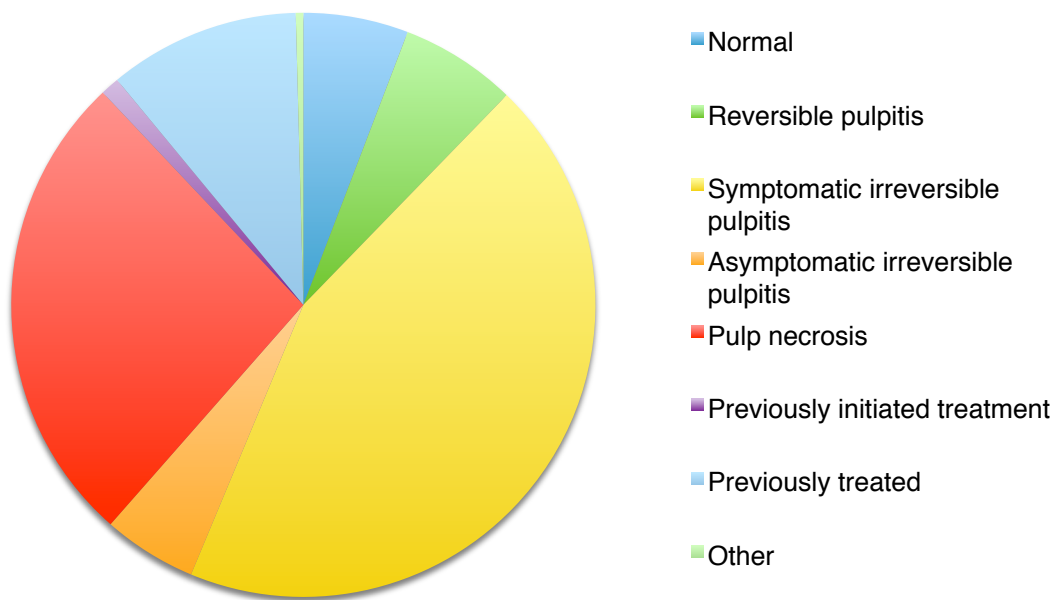
Other entries in the template included Visual Analogue Scale (VAS) score, electric pulp test (EPT) and periodontal findings. The majority of patients reported VAS score of 0. This occurred twice as frequently as any other VAS score. VAS scores from 1-10 were evenly distributed. This data was not included in the study.

Review of the pulpal diagnosis data revealed the most common diagnosis to be symptomatic irreversible pulpitis (44%), followed by pulp necrosis in 26.5% of teeth. By identifying the pulpal diagnosis as a vital or non-vital diagnosis it was found that 38.3% of teeth were non-vital, and 61.7% were vital. This is reinforced by the results of endodontic tests that showed almost 60% of teeth with symptomatic apical periodontitis tested positively to a cold test and gave a vital response. Table 4 and Figure 1 present the prevalence of each pulpal diagnosis found in SAP in this study population.

Table 4. Frequency of Pulpal Diagnosis by Number and Percentage of Teeth

Pulpal diagnosis	N	%
Normal	56	5.8
Reversible pulpitis	62	6.4
Symptomatic irreversible pulpitis	424	44.0
Asymptomatic irreversible pulpitis	50	5.2
Pulp necrosis	255	26.5
Previously initiated treatment	10	1.0
Previously treated	102	10.6
Other	4	0.4
Total	963	100.0

Figure 1. Chart Representation of the Prevalence of Pulpal Diagnosis in SAP



Radiographic evaluation of 963 teeth with SAP revealed 369 (38.3%) teeth had lesions and 594 (61.7%) did not, with the lamina dura intact around the tooth. The size of lesion exhibited a range from 0.39mm to 13.36mm.

Agreement Statistics

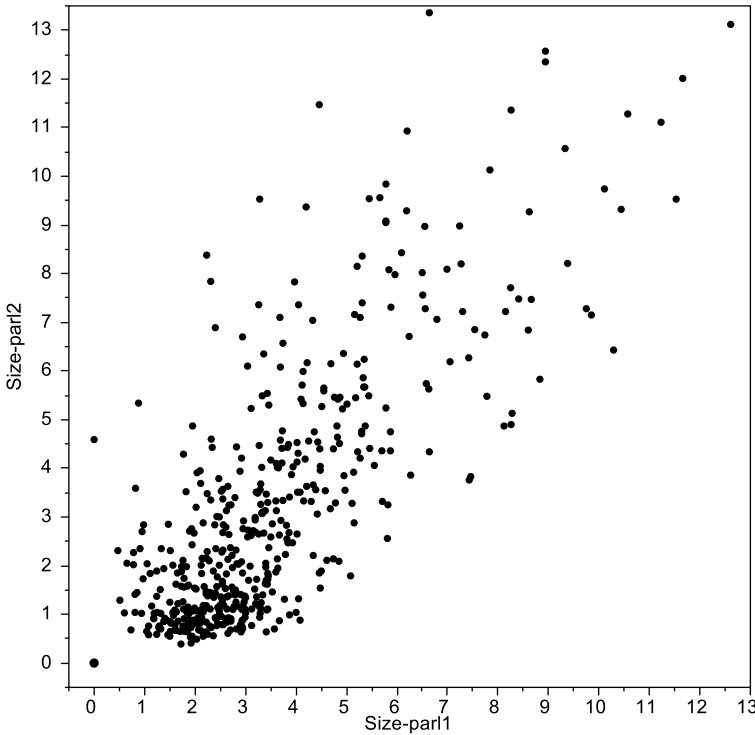
When reviewing radiographs for the presence or absence of a periapical radiolucency and its size when present, the degree of agreement between examiners as determined by the Kappa statistic for the presence or absence of a PARL was .69 with a confidence interval between .51 - .87. The Pearson correlation between the two measures by the examiners was $r = 0.72$. See Table 5.

Table 5. Weighted Kappa Statistical Analysis Ranges

Kappa value	Degree of agreement
≤ 0.2	Poor
0.21–0.4	Fair
0.41–0.6	Moderate
0.61–0.8	Good
0.81–1.0	Very good

For each lesion two measurements were recorded as close to perpendicular to one another as possible. The two measures were analyzed using Spearman's rank correlation. The two measures were highly correlated ($p < .0001^*$) and if the absence of a PARL, i.e. a lesion measuring 0.0mm by 0.0mm were included, the correlation would have been greater. Since the two values were so highly correlated, they were averaged in the calculation of the area to obtain a single value for the area of any one lesion. This single value allowed for more straightforward application of statistical tests.

Figure 2. Scatterplot matrix showing high correlation between 2 measures



Individual Characteristics and Association with Periapical Radiolucency and its Size

Periapical lesion by tooth type analysis revealed that although there was no significant difference among the tooth types a slightly higher proportion of anterior teeth had a PA lesion. See Table 6.

Table 6. PARL in relation to tooth type

Tooth type	PARL			
	Yes		No	
	N	%	N	%
Anteriors	62	42.2	85	57.8
Premolars	124	36.8	213	63.2
Molars	183	38.2	296	61.2

Further analysis to determine whether tooth type and anatomical location influenced presence or size of a periapical radiolucency showed no significant results (See Table 7).

Table 7. Tooth type and relative position by size

Lesion Size	Count	PARL (%)			
		No 0	Yes		
			0-2mm	2-5mm	>5mm
Tooth Type					
Mandibular					
Anterior	21	47.6	4.8	42.9	4.8
Premolar	109	56.9	11.0	25.7	6.4
Molar	287	60.3	14.6	13.2	11.9
Maxillary					
Anterior	126	59.5	13.5	16.7	10.3
Premolar	228	65.8	12.3	16.2	5.7
Molar	192	64.1	10.9	16.7	8.3

Contingency analysis of the periapical lesion by percussion found no relationship between percussion sensitivity and PARL size ($p > .10$). However, analysis of the periapical lesion by palpation shows that an increase in palpation response was associated with an increase in PARL size ($p < .01$). A reduced cold response was associated with an increase in PARL size ($p < .01$). See Table 8.

Table 8. Diagnosis and Endodontic Test Results Versus PARL Size

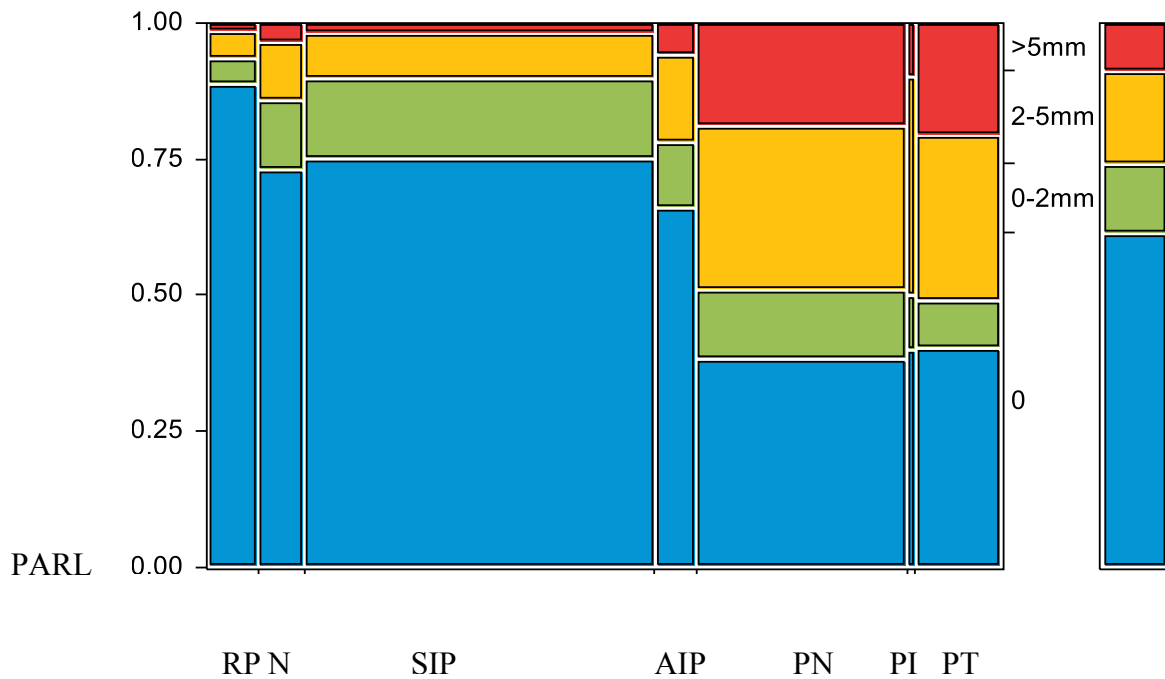
Lesion Size	Count	PARL (%)				P-value*
		No 0	Yes 0-2mm	2-5mm	>5mm	
Prevalence	963	61.7	38.3			
Pulpal Diagnosis						<.0001
Reversible Pulpitis	62	88.7	4.8	4.8	1.6	
Normal	56	73.2	12.5	10.7	3.6	
Symptomatic Irreversible Pulpitis	424	75.0	14.9	8.3	1.9	
Asymptomatic Irreversible Pulpitis	50	66.0	12.0	16.0	6.0	
Pulp Necrosis	255	38.4	12.6	30.2	18.8	
Previously Initiated Therapy	10	40.0	10.0	40.0	10.0	
Previously Treated	102	40.2	8.8	30.4	20.6	
Palpation						0.0078
None	582	65.8	12.7	15.1	6.4	
+	207	59.4	11.6	19.3	9.7	
++	116	52.6	12.9	20.7	13.8	
+++	46	45.7	15.2	19.6	19.6	
Percussion						0.1077
None	54	46.3	9.3	29.6	14.8	
+	326	59.5	13.2	18.1	9.2	
++	346	63.0	12.1	17.3	7.8	
+++	227	65.6	13.7	12.3	8.4	
Cold						<.0001
None	348	40.5	11.6	30.6	17.9	
+	138	64.5	13.8	15.9	5.8	
++	152	79.6	11.2	7.9	1.3	
+++	291	78.0	14.1	6.2	1.7	

* Pearson chi-square

When a periapical lesion is present the most frequent pulpal diagnosis is pulp necrosis followed by symptomatic irreversible pulpitis, and previously treated pulp. The lesions were then grouped according to size and the variable such as pulpal diagnosis and endodontic test results were analyzed ($p < 0.0001$). Pearson Chi square with Bonferroni correction was used to analyze pulpal diagnosis. Diagnoses including normal pulp, reversible pulpitis, and symptomatic irreversible pulpitis were different from pulp necrosis, previously initiated therapy, and previously treated pulp. Asymptomatic irreversible pulpitis was neither like the vital group nor was it like the non-

vital group. It functioned as if it was a different entity. These same groups show a variation in size. Periapical radiolucencies present when pulpal diagnosis includes normal pulp, reversible pulpitis, and symptomatic irreversible pulpitis tends to have more frequently occurring lesions that are <2mm at maximal diameter. Whereas, when considering non-vital diagnoses such as pulp necrosis, previously initiated therapy, and previously treated pulp the prevalence is toward larger lesions. See Table 8 and Figure 3.

Figure 3. Contingency Analysis of Presence/Absence of PARL and PARL size by Pulp diagnosis



(Legend: RN – Reversible Pulpitis, N – Normal Pulp, SIP – Symptomatic Irreversible Pulpitis, AIP – Asymptomatic Irreversible Pulpitis, PN – Pulp Necrosis, PI – Previously Initiated Therapy, PT – Previously Treated Pulp)

When pulpal diagnoses are grouped into vital or non-vital categories it was found that 24.5% of vital teeth had a PARL. See Table 9.

Table 9. Vital and non-vital pulp diagnoses and presence or absence of PARL

Tooth vitality	PARL			
	Yes		No	
	N	%	N	%
Vital	145	24.5	447	75.5
Non-vital	223	60.8	144	39.2

In summary, key results are presented below:

- 1418 patients were diagnosed with SAP and 963 teeth met the inclusion criteria
- Sample comprised: 49.7% molars, 35.0% premolars, 15.3% anterior teeth
- The most prevalent pulpal diagnosis with SAP was symptomatic irreversible pulpitis at 44%
- Prevalence of periapical radiolucency with SAP was 38.3% (369 teeth)
- The most frequent pulpal diagnoses in the presence of a PARL were pulp necrosis (42.3%), symptomatic irreversible pulpitis (28.7%), and previously treated (16.5%)
- Lesion size when present varied from 0.39 mm to 13.36 mm at maximum diameter
- Grouping pulpal diagnoses into vital vs. non-vital categories showed that 24.5% of vital teeth had a PARL whereas 61% of non-vital teeth had a PARL
- An increase in palpation response was associated with an increase in PARL size ($p < .01$)
- Reduced cold response was associated with an increase in PARL size ($p < .01$)
- There was no relationship between percussion sensitivity and PARL size ($p > .10$)
- The correlation between the examiners was good at 0.72

- The Kappa statistic for the presence or absence of a PARL was 0.69 with a confidence interval between 0.51 - 0.87

Discussion

The sample comprised a greater proportion of women and this is consistent with national statistics that show women in the United States are more likely than men to report a dental visit during the course of a year (31). Pulpal and periapical pain are two of the reasons why patients seek dental care. A survey by Lipton showed that 28% of the non-institutionalized civilian residents of the United States population reported experiencing orofacial pain in the preceding 6 months, with the most common report being odontalgia. A larger percentage of women than men were found to have experienced each type of orofacial pain (32).

The distribution of teeth most commonly presenting with SAP showed lower first molars to be the most prevalent, followed by upper premolars, and then upper first molars. When the eruption pattern, function, masticatory and occlusal forces supported by these teeth is considered, it is no surprise that first molars were so highly prevalent. No literature is available for comparison.

In this study the most frequent pulpal diagnosis seen with SAP was symptomatic irreversible pulpitis. Owatz et al investigated the incidence of mechanical allodynia among patients presenting with odontalgia. All patients included in this study had either normal periradicular radiographic anatomy or no more than a two-fold widening of the periodontal ligament space,

and a diagnosis of acute periradicular periodontitis determined by tenderness to percussion. Using current terminology the clinical periapical diagnosis is SAP. Owatz found patients presenting with SAP and symptomatic irreversible pulpitis to be the most prevalent at 57.2% (33). In the current study prevalence of SAP with symptomatic irreversible pulpitis was 44%. The difference in prevalence could be attributed to the source of patients for each study. Owatz used patients presenting to an emergency clinic for extraction so were in considerable pain. The combination of periradicular mechanical allodynia with inflamed vital pulp tissue gives rise to odontogenic pain. It is commonly known that pain is a major trigger for patients to seek dental attention, so is not surprising that this is the most prevalent diagnosis.

The radiographic sample assessed consisted primarily of images taken using phosphor plate technology and a minority of images used a Dexis™ sensor. Studies investigating the diagnostic accuracy of intraoral radiographic techniques using film and digital methods with that of storage phosphor plates or sensors showed that film and digital technique attained the same diagnostic accuracy, irrespective of digital technique (28, 30, 34).

During the radiograph interpretation training it was decided that image processing enhancements, such as colorizing and inverting would not be used as these functions have not been shown to improve the detection of periapical lesions (28). Only one enhancement was used when evaluating every radiograph, and this was an “edge enhance” feature. Kullendorff and Nilsson defined edge enhancement as “a spatial differentiation filter in which a subtraction is made between the image and the image that has been shifted obliquely a few pixels. In this way a kind of image gradient is obtained that shows the edges of the objects” (35). The use of this

radiographic enhancement was based upon the examiners preference. Kullendorff and Nilsson showed that image processing of high quality images had a limited effect on overall diagnostic accuracy (35). They found that basic processing functions such as alterations of contrast and brightness were preferred for the detection of periapical lesions. However, in order to try and standardize the interpretation procedure between examiners these functions were not used.

Radiograph interpretation training exercises were carried out prior to initiating the study, as well as after every 50 radiographs. Pearson correlation and Kappa statistical analysis was used to measure the level of agreement among multiple raters. The level of agreement was considered to be good (0.6-0.8), which is better than cited in most literature. In the classic study by Goldman utilizing film, agreement between 6 examiners was found to be less than 50% (36). A similar study by Tewary and Hartwell used digital radiography and found the overall agreement between examiners was fair (0.2-0.4). A lower level of agreement could be attributed to the number of examiners reading a smaller number of films, utilization of a relatively new digital system, and level of experience varied between 5-40 years among the examiners (37). Another variable in the Tewary study was that although all observers viewed the radiographs under the same ideal lighting conditions on the same computer, they were allowed to use any or all of the image enhancement tools available on the radiographic software program when viewing the images. Each examiner potentially could have changed the image considerably and this may have contributed to decreased agreement among examiners. It is also noted that in the present study agreement among examiners was greater when the absence of lesion was included in the analysis. This finding is similar to observations made by Patel where he found examiners agreed that 50% of the sample population did not have a lesion, but agreement in only 18% of the

sample when a lesion was present (38). Bohay sought to describe the sensitivity, specificity and reliability of periapical radiographic diagnosis pertaining to periapical inflammatory disease of posterior teeth. The sensitivity was 0.65 and the specificity was 0.78. He concluded that periapical radiographs were better able to identify teeth without periapical disease than to identify the teeth that have periapical disease (39).

In clinical practice radiographic lesions are typically measured in two dimensions, usually perpendicular to one another at the maximum extent of the visible lesion. An incidental finding from this study was the high degree of correlation between the two measurements with a small number of outliers (see Figure 2). The implication is that there is no need to record two measurements and only one measurement at the maximum extent of the lesion.

Interpretation of the periradicular structural changes on a radiograph is known to be challenging. The variation of apical morphology, varying radiodensity of surrounding bone, as well as anatomical superimposition presents a significant challenge. A periapical lesion has been defined as radiolucency associated with the radiographic apex of the root, which was at least twice the width of the periodontal ligament space (40). Analysis of the periodontal ligament space, the lamina dura, trabecular pattern and bone marrow spaces is essential for the radiographic diagnosis of periapical disease (41). In the classic study by Seltzer and Bender, artificially created lesions confined to the cancellous bone could not be detected with standard periapical radiographic imaging until the cortical plate was partially eroded (25). However, more recent studies have shown that early changes in cancellous bone can be detected before erosion of the cortical plate, although this depends upon location in the mouth and bone density (29, 42). Lee

and Messer showed that periapical lesions confined to cancellous bone were detected in 80% of cases, and the presence of a sclerotic border tended to enhance visualization (29). Cavalcanti et al found that the loss of periapical lamina dura alone was not sufficient for most dentists to detect a change radiographically. Loss of periapical lamina dura in conjunction with loss of trabecular bone must occur for radiographic lesion detection. In this study the prevalence of PARLs associated with teeth was 38.3%. The same sample was also assessed for lesion per individual roots giving a prevalence of 23.4%. Patel et al reported similar findings in a study in which all patients had been clinically diagnosed with signs of endodontic disease and periapical lesions were present in 55 (20%) and absent in 218 (80%) roots when assessed with periapical radiographs (38). Whilst Patel did not specifically state that those roots with a PARL had SAP, it was inferred.

In the presence of a periapical radiolucency the most prevalent pulpal diagnoses were pulp necrosis (42.3%) followed by symptomatic irreversible pulpitis (28.7%). According to the AAE Colleagues of Excellence 2001 publication *Pulpal/Periodontal Relationships* “if a radiolucency is in the periradicular region of a tooth with a vital pulp, it cannot be of pulpal origin and will be either a normal structure or another type of pathosis” (22). The findings of this study contradict this earlier statement made by the AAE. This study shows by means of radiographic analysis that a tooth with a vital pulp can present with a PARL. This finding has been documented before by studies utilizing different methodologies. Gesi et al conducted a randomized clinical trial to assess the outcome of pulpectomy carried out in two treatment sessions with calcium hydroxide as an intracanal dressing and compared this to a procedure comprising instrumentation and root-filling in one session. All subjects had a vital pulp condition and 16% displayed a preoperative

PARL. The variation in prevalence could be explained by the fact that in the Gesi study the tooth was accessed and bleeding from the pulp invariably confirmed the presence of vital tissue. However, the prevalence in this radiographic study is based upon endodontic test results according to chart details. The reliability of this information could not be confirmed. Studies observing vital teeth with PARL vary considerably in their prevalence from 7% to 36% (15, 24, 43, 44).

Ricucci presented a study that evaluated human periapical lesions for bacteria and epithelium. One of the specific aims of this study was to evaluate the condition of the connective tissue in the apical third of the canal and in the apical ramifications of teeth with apical periodontitis. Vital tissues showing varying degrees of inflammation was found in the apical part of the canals in 18 of the 50 roots (36%) (15). This phenomenon can be explained by the egress of bacteria, their virulence factors such as, cellular constituents (lipopolysaccharide, peptidoglycan, lipoteichoic acid, fimbriae, membrane proteins) and metabolic end products in to the periradicular tissues. These irritants act as antigens in the periradicular tissues and immediately encounter host defense mechanisms. The initial innate immune response is followed by the adaptive immune response, both of which are mobilized in an attempt to contain the spread of infection persisting in the root canal (45-47). Since these products may be transported from their original site in the canal to the periapical tissue through functioning vessels, the reason for the presence of healthy pulp tissue between the two areas of severe inflammation becomes clear. The higher prevalence of vital tissue in teeth with apical radiolucencies in the histopathological studies reported by Ricucci and Lin may be explained by the variation in methodology. In these studies the vitality is being assessed at a cellular level whereas in this study pulpal sensibility testing assessed vitality.

Despite the prevailing research regarding the presence of vital tissue in teeth with PARL, studies by Petersson, Weisleder, and Villa-Chavez have reported false-positive rates of 17%, 8%, and 12%, respectively for cold testing (48-50). In addition to false-positive results to cold testing, clinician error and incorrect entry into the template note could have affected the resultant data.

Two histological studies presented by Lin provide further details regarding the presence of vital tissue in teeth with PARLs. In both studies Lin describes the presence of a PARL associated with a tooth with necrosis of the coronal pulp. Structurally intact nerve fibers were observed in inflamed root pulp and electron micrographs confirmed the presence of myelinated and unmyelinated nerve tissue. They showed that vital pulp tissue with intact functioning nerve fibers can persist in a tooth a long time after an inflammatory periapical pathosis has developed due to severe inflammation and partial necrosis. In cases where a negative response to pulp testing was found, histopathological examination frequently indicated that there was a necrosis involving most of the coronal pulp (47, 51).

The presence of positive pulp sensibility testing in a multirouted tooth with a periapical radiolucency can be readily explained. Pulp tissue in one canal could have vital tissue capable of responding to sensibility testing, such as cold refrigerant spray, and have extensively necrotic or inflamed tissue in another canal. Vital pulp tissue might still be present more apically with necrotic tissue in the coronal aspect as described above (51). Another reason for apical pulp tissue remaining vital for a long time is the substantial blood supply coming from a large number of ramifications particularly concentrated in the apical area. The outmoded strangulation theory, based on the belief that there is one artery entering the foramen and two veins leaving and that these are compressed and strangulated, denying escape of fluids from the pulpal space, is flawed.

There are numerous vessels going in and out of numerous foramina (52). The strangulation theory of pulpal necrosis, a concept presented by Van Hassel, is based on the belief that space for additional blood and tissue fluid is provided by compression of venules, since pressure in the venules is lower than in the arterioles and capillaries. Compression of venules would then lead to localized ischemia and necrosis. Histological evidence to support this theory is lacking. If the strangulation theory were valid we would expect inflamed pulps to become ischemic and undergo infarction. An infarct is a localized area of ischemic necrosis produced either by occlusion of the arterial supply or its venous drainage. Pulpal infarcts are uncommon and are usually caused by trauma to the vessels entering the pulp rather than to inflammation (53).

Non-vital diagnoses (pulp necrosis, previously initiated therapy, and previously treated pulp) showed more variation in terms of size with the majority of lesions being greater than 2mm (see Table 9). In a clinical and histopathological study by Lin, pulp tissue associated with teeth displaying a PARL was biopsied. It was observed that in most cases when a large PARL was present the associated tooth did not respond to pulpal sensibility testing. Histologically extensive necrosis involving most of the root pulp was seen with massive colonies of bacteria spread throughout the tissue. According to Lin the size of the periapical radiolucency seems to be related to the extent and degree of bacterial invasion and tissue disintegration of the pulp in the root canal (51). In contrast to these findings, some teeth with small periapical radiolucencies responded to pulp testing, depending on the extent of pulp necrosis. Biopsy of the pulpal tissue from these teeth generally demonstrated necrosis involving only the coronal pulp. The zone of necrosis varied from involving a localized small area just penetrating the coronal pulp to the entire coronal pulp (51). These observations, confirmed by histology, are consistent with the

variation of PARL and size seen in this study. Teeth that presented with a vital pulp (normal pulp, reversible pulp and symptomatic irreversible pulpitis) and a PARL exhibited a greater number of lesions that were less than 2mm ($p < 0.0001$). This finding contrasts the finding of a commonly cited study by Kaffe and Grant (21). They reported that radiological signs, such as changes in the width and form of the periodontal ligament space and interruption of the continuity of lamina dura, were associated with nonvital pulps.

A trend was detected when analyzing response to palpation testing. This study is in agreement with an article by Newton reporting that isolated tenderness to palpation in the apical area of the tooth is suggestive of relatively advanced periapical inflammation and/or infection (54). However, this study further suggests that an increase in palpation response may likely result in discovering a PARL of greater size ($p < .01$). This was considered a weak association. A key factor influencing this data is subjectivity from both the clinician and the patient. The patients' response to this (and any of the tests) will be related to their level of perceived pain. This in turn will be influenced by their dental experiences, history of pain, and other modifying psychological, social, and situational factors. The clinician, in this case a dental student, may not yet have the experience to gauge the response. Analysis of percussion response did not result in such a trend. The percussion diagnostic test for apical periodontitis has a reported sensitivity of .70 and specificity of .51 (55). This indicates that positive findings are not specific for endodontic pathosis (54).

In conclusion, extraction of data by using the predoctoral endodontic diagnostic template generated a sample population of 1418 subjects for inclusion in the study. It was observed that

the majority of subjects had an entry with appropriately documented objective findings. This point is exemplified by the evaluation of the results of cold testing. According to the template note 61.7% of teeth had a vital diagnosis and when evaluating results of cold testing 62.5% responded. This high correlation does imply reliability in the data. The template note proved to be a reliable method of documentation of data and diagnosis, and could be used for research purposes in the future.

The presence of a periapical radiolucency associated with a tooth having symptomatic apical periodontitis can only inform the clinician that periapical inflammation is present. It cannot predict the vitality of the tooth (24). Although it is more likely for a tooth presenting with SAP to have an intact lamina dura, a PARL can present up to 40% of the time. Grouping pulpal diagnosis into vital vs. non-vital categories showed that 24.5% of vital teeth had a periapical radiolucency whereas 61% of non-vital teeth had a periapical radiolucency. While an increase in the degree in palpation response shows a trend toward presence of a PARL, neither palpation nor percussion can be used to predict the likely presence or absence of a PARL.

The findings of this study support the current diagnostic terminology approved by the AAE and ABE defining Symptomatic Apical Periodontitis.

References

1. American Association of Endodontics. Glossary of endodontic terms. Ed 8. American Association of Endodontists: Chicago; 2012.
2. Schweitzer JL. The endodontic diagnostic puzzle. *Gen Dent.* 2009 Nov-Dec; 57(6): 560,7; 568-9, 595, 679.
3. Seltzer S, Bender IB, Ziontz M. The dynamics of pulp inflammation: Correlations between diagnostic data and actual histologic findings in the pulp. *Oral Surg Oral Med Oral Pathol.* 1963 Aug;16:969-77.
4. Seltzer S, Bender IB, Nazimov H. Differential diagnosis of pulp conditions. *Oral Surg Oral Med Oral Pathol.* 1965 Mar;19:383-91.
5. Figdor D. Apical periodontitis: A very prevalent problem. *Oral Surg Oral Med Oral Pathol Oral Radiol Endod.* 2002 Dec;94(6):651-2.
6. American Association of Endodontics. Colleagues for excellence: Endodontic diagnosis. Fall 2013.
7. Eriksen H. Epidemiology of apical periodontitis. In: D Ørstavik, TR Pitt Ford, Editors. *Essential Endodontology. Prevention and Treatment of Apical Periodontitis.* London: Blackwell Science; 1998:179-91.
8. Siqueira JF, Jr. The Disease: Clinical Manifestations and Pathophysiology of Apical Periodontitis. In: *Treatment of Endodontic Infections.* ; 2011. p. 7

9. Kakehashi S, Stanley HR, Fitzgerald RJ. The effects of surgical exposures of dental pulps in germ-free and conventional laboratory rats. *Oral Surg Oral Med Oral Pathol.* 1965 Sep;20:340-9.
10. Moller AJ, Fabricius L, Dahlen G, Ohman AE, Heyden G. Influence on periapical tissues of indigenous oral bacteria and necrotic pulp tissue in monkeys. *Scand J Dent Res.* 1981 Dec;89(6):475-84.
11. Ricucci D, Siqueira JJ. Periradicular Pathology. In: *Endodontology: An Integrated Biological and Clinical View.* ; 2013. p. 107.
12. Langeland K. Tissue response to dental caries. *Endod Dent Traumatol.* 1987 Aug;3(4):149-71.
13. Ricucci D, Bergenholtz G. Histologic features of apical periodontitis in human biopsies. *Endodontic Topics.* 2004;8:68-87.
14. Ricucci D, Langeland K. Apical limit of root canal instrumentation and obturation, Part 2. A histological study. *Int Endod J.* 1998 Nov;31(6):394-409.
15. Ricucci D, Pascon EA, Ford TR, Langeland K. Epithelium and bacteria in periapical lesions. *Oral Surg Oral Med Oral Pathol Oral Radiol Endod.* 2006 Feb;101(2):239-49.
16. Kovacevic M, Tamarut T, Jonjic N, Braut A, Kovacevic M. The transition from pulpitis to periapical periodontitis in dogs' teeth. *Aust Endod J.* 2008 Apr;34(1):12-8.
17. Yamasaki M, Kumazawa M, Kohsaka T, Nakamura H, Kameyama Y. Pulpal and periapical tissue reactions after experimental pulpal exposure in rats. *J Endod.* 1994 Jan;20(1):13-7.
18. Stashenko P, Wang CY, Riley E, Wu Y, Ostroff G, Niederman R. Reduction of infection-stimulated periapical bone resorption by the biological response modifier PGG glucan. *J Dent Res.* 1995 Jan;74(1):323-30.
19. Patel S, Durack C, Abella F, Shemesh H, Roig M, Lemberg K. Cone beam computed tomography in endodontics - a review. *Int Endod J.* 2015 Jan;48(1):3-15.

20. Huumonen S, Orstavik D. Radiological aspects of apical periodontitis. *Endodontic Topics*. 2002;1:3-25.
21. Kaffe I, Gratt BM. Variations in the radiographic interpretation of the periapical dental region. *J Endod*. 1988 Jul;14(7):330-5.
22. American Association of Endodontics. *Colleagues for excellence: Systematic pulpal diagnosis*. 2001.
23. Langeland K. *Pulp histology and physiology In: Pathways of the Pulp*. Mosby; 1976.
24. Lin L, Shovlin F, Skribner J, Langeland K. Pulp biopsies from the teeth associated with periapical radiolucency. *J Endod*. 1984 Sep;10(9):436-48.
25. Bender IB, Seltzer S. Roentgenographic and direct observation of experimental lesions in bone: I. 1961. *J Endod*. 2003 Nov;29(11):702,6; discussion 701.
26. Bender IB. Factors influencing the radiographic appearance of bony lesions. *J Endod*. 1997 Jan;23(1):5-14.
27. Paurazas SB, Geist JR, Pink FE, Hoen MM, Steiman HR. Comparison of diagnostic accuracy of digital imaging by using CCD and CMOS-APS sensors with E-speed film in the detection of periapical bony lesions. *Oral Surg Oral Med Oral Pathol Oral Radiol Endod*. 2000 Mar;89(3):356-62.
28. Barbat J, Messer HH. Detectability of artificial periapical lesions using direct digital and conventional radiography. *J Endod*. 1998 Dec;24(12):837-42.
29. Lee SJ, Messer HH. Radiographic appearance of artificially prepared periapical lesions confined to cancellous bone. *IEJ*. 1986;19:64-72.
30. Petersson A, Axelsson S, Davidson T, Frisk F, Hakeberg M, Kvist T, et al. Radiological diagnosis of periapical bone tissue lesions in endodontics: A systematic review. *Int Endod J*. 2012 Sep;45(9):783-801.

31. Centers for disease control. health, united states, 2014. Table 84. Dental visits in the past year, by selected characteristics: United States, selected years 1997–2013.
32. Lipton JA, Ship JA, Larach-Robinson D. Estimated prevalence and distribution of reported orofacial pain in the United States. *J Am Dent Assoc.* 1993 Oct;124(10):115-21.
33. Owatz CB, Khan AA, Schindler WG, Schwartz SA, Keiser K, Hargreaves KM. The incidence of mechanical allodynia in patients with irreversible pulpitis. *J Endod.* 2007 May;33(5):552-6.
34. Holtzmann DJ, Johnson WT, Southard TE, Khademi JA, Chang PJ, Rivera EM. Storage-phosphor computed radiography versus film radiography in the detection of pathologic periradicular bone loss in cadavers. *Oral Surg Oral Med Oral Pathol Oral Radiol Endod.* 1998 Jul;86(1):90-7.
35. Kullendorff B, Nilsson M. Diagnostic accuracy of direct digital dental radiography for the detection of periapical bone lesions. II. effects on diagnostic accuracy after application of image processing. *Oral Surg Oral Med Oral Pathol Oral Radiol Endod.* 1996 Nov;82(5):585-9.
36. Goldman M, Pearson AH, Darzenta N. Endodontic success--who's reading the radiograph? *Oral Surg Oral Med Oral Pathol.* 1972 Mar;33(3):432-7.
37. Tewary S, Luzzo J, Hartwell G. Endodontic radiography: Who is reading the digital radiograph? *J Endod.* 2011 Jul;37(7):919-21.
38. Patel S, Wilson R, Dawood A, Mannocci F. The detection of periapical pathosis using periapical radiography and cone beam computed tomography - part 1: Pre-operative status. *Int Endod J.* 2012 Aug;45(8):702-10.
39. Bohay RN. The sensitivity, specificity, and reliability of radiographic periapical diagnosis of posterior teeth. *Oral Surg Oral Med Oral Pathol Oral Radiol Endod.* 2000 May;89(5):639-42.
40. Bornstein MM, Lauber R, Sendi P, von Arx T. Comparison of periapical radiography and limited cone-beam computed tomography in mandibular molars for analysis of anatomical landmarks before apical surgery. *J Endod.* 2011 Feb;37(2):151-7.

41. Halse A, Molven O, Fristad I. Diagnosing periapical lesions--disagreement and borderline cases. *Int Endod J.* 2002 Aug;35(8):703-9.
42. LeQuire AK, Cunningham CJ, Pelleu GB, Jr. Radiographic interpretation of experimentally produced osseous lesions of the human mandible. *J Endod.* 1977 Jul;3(7):274-6.
43. Kerekes K, Tronstad L. Long-term results of endodontic treatment performed with a standardized technique. *J Endod.* 1979 Mar;5(3):83-90.
44. Jordan RE, Suzuki M, Skinner DH. Indirect pulp-capping of carious teeth with periapical lesions. *J Am Dent Assoc.* 1978 Jul;97(1):37-43.
45. Stashenko P. Role of immune cytokines in the pathogenesis of periapical lesions. *Endod Dent Traumatol.* 1990 Jun;6(3):89-96.
46. Siqueira JF, Jr. *Treatment of endodontic infections.* 1st ed. Quintessence Publishing; 2011.
47. Lin L, Langeland K. Light and electron microscopic study of teeth with carious pulp exposures. *Oral Surg Oral Med Oral Pathol.* 1981 Mar;51(3):292-316.
48. Petersson K, Soderstrom C, Kiani-Anaraki M, Levy G. Evaluation of the ability of thermal and electrical tests to register pulp vitality. *Endod Dent Traumatol.* 1999 Jun;15(3):127-31.
49. Weisleder R, Yamauchi S, Caplan DJ, Trope M, Teixeira FB. The validity of pulp testing: A clinical study. *J Am Dent Assoc.* 2009 Aug;140(8):1013-7.
50. Villa-Chavez CE, Patino-Marin N, Loyola-Rodriguez JP, Zavala-Alonso NV, Martinez-Castanon GA, Medina-Solis CE. Predictive values of thermal and electrical dental pulp tests: A clinical study. *J Endod.* 2013 Aug;39(8):965-9.
51. Lin L, Shovlin F, Skribner J, Langeland K. Pulp biopsies from the teeth associated with periapical radiolucency. *J Endod.* 1984 Sep;10(9):436-48.
52. Ricucci D. Apical limit of root canal instrumentation and obturation, part 1. literature review. *Int Endod J.* 1998 Nov; 31(6): 384-93.

53. Trowbridge HO. Pulp biology: Progress during the past 25 years. *Aust Endod J.* 2003 Apr;29(1):5-12.
54. Newton CW, Hoen MM, Goodis HE, Johnson BR, McClanahan SB. Identify and determine the metrics, hierarchy, and predictive value of all the parameters and/or methods used during endodontic diagnosis. *J Endod.* 2009 Dec;35(12):1635-44.
55. Klausen B, Helbo M, Dabelsteen E. A differential diagnostic approach to the symptomatology of acute dental pain. *Oral Surg Oral Med Oral Pathol.* 1985 Mar;59(3):297-301.

Appendix A

Predoctoral endodontic diagnostic template note

Attending Faculty | * |

Provider | *

Chief Complaint | * |

Pain (VAS) | *

Dental History || *

Blood Pressure | * / * | Pulse | * / Bpm |

Clinical Exam: || *

|

Tooth Number ||| * | * | * | * | * | * | * ||

Percussion ||| * | * | * | * | * | * | * | * ||

Palpation ||| * | * | * | * | * | * | * | * ||

Cold ||| * | * | * | * | * | * | * | * ||

Mobility ||| * | * | * | * | * | * | * | * ||

EPT ||| * | * | * | * | * | * | * | * ||

Periodontal Findings *

Radiographs Ordered | * |

Radiograph Findings | * |

Diagnoses and Indicated etiology for tooth number *

Pulp Diagnosis | * |

Periapical Diagnosis | * |

Etiology | * |

Additional Narrative | * |

Next Appointment | * |

Appendix B

Data Gathering Guidelines

Order of Process:

- Open Axium
- Go to Rolodex
- Enter chart number (be certain to cross check age and gender with the same chart number details in the JMP doc)
- Click on pt. name (single click). It should now appear in the bar at the bottom
- Click once on Mipacs
- Find the radiograph matching the date in the JMP doc
- Radiographic interpretation – read below
- If there are no radiographs record this in the JMP document using the key for data inclusion

NOTE: If there are multiple radiographs use the following inclusion criteria to help you determine the best image to select

- The tooth in question is most centered on the film
- The apex and a few mm beyond the apex is included in the image
- PARL is completely included and borders of the lesion are visible on the image
- The most straight-on shot

Reading Radiographs:

- If the image was taken on a Dexis sensor, no calibration is required
- Phosphor plate radiographs require calibration:
 - In Mipacs, select radiographs from the appropriate date, then press 1:1
 - Go to Measurement calibration
 - For anterior/small radiographs measure the smallest dimension for calibration. Enter 24mm
 - For posterior/large radiographs measure the smaller dimension for calibration. It is 31mm
 - Press “edge enhance”
 - Measurements:

- Follow the lamina dura or PDL space around the roots. If the lamina dura is intact, there is no PARL.
- If you see a PARL, record the maximum extent of lesion. 2 readings are necessary, perpendicular to one another (as close as possible to perpendicular)
- Record findings in JMP doc
- Size 1 will be the “horizontal or width” reading (or as close as possible)
- Size 2 will be the “vertical or height “ of the lesion

KEY FOR JMP SPREADSHEET

N-NC	No chart
N-ICN	Incomplete chart number
N-I	Inconsistent (chart# and JMP# do not match e.g.: age &/or gender, radiographs of a different tooth), no diagnostic PA present -only treatments PAs.
N-NR	No DIAGNOSTIC PA radiograph for date of note
N-NEP	Non-existent patient
N-A	Apex or PARL not fully visible on radiograph
N-U	Radiograph is not clear, possible superimposition.
N-IMP	PA has been imported. Cannot be calibrated.
N-AD	Associated with other etiology, e.g.- endo-perio lesion. Lesion extends all the way to bony crest or distal tooth has a mesioangular impaction creating a RL adjacent to this tooth

Appendix C

Raw data files without any identifying characters are in a protected file within data storage for the Endodontic Department.