



2015

# Nosocomial keratitis caused by methicillin-resistant *Staphylococcus aureus*: case report and preventative measures

Puneet S. Braich

*Virginia Commonwealth University*, [puneet.braich@vcuhealth.org](mailto:puneet.braich@vcuhealth.org)

Shruti Aggarwal

*University of Virginia - Main Campus*

Sabrina Mukhtar

*Virginia Commonwealth University*

David RP Almeida

*VitreoRetinal Surgery*

Follow this and additional works at: [http://scholarscompass.vcu.edu/opth\\_pubs](http://scholarscompass.vcu.edu/opth_pubs)

 Part of the [Ophthalmology Commons](#)

Copyright © 2015 Puneet S. Braich et al. This is an Open Access article distributed under the terms of the Creative Commons Attribution-NonCommercial 4.0 International License, permitting all non-commercial use, distribution, and reproduction in any medium, provided the original work is properly cited.

Downloaded from

[http://scholarscompass.vcu.edu/opth\\_pubs/3](http://scholarscompass.vcu.edu/opth_pubs/3)

This Article is brought to you for free and open access by the Dept. of Ophthalmology at VCU Scholars Compass. It has been accepted for inclusion in Ophthalmology Publications by an authorized administrator of VCU Scholars Compass. For more information, please contact [libcompass@vcu.edu](mailto:libcompass@vcu.edu).

CASE REPORT

## Nosocomial keratitis caused by methicillin-resistant *Staphylococcus aureus*: case report and preventative measures

Puneet S. Braich, MD, MPH<sup>1\*</sup>, Shruti Aggarwal, MBBS<sup>2</sup>,  
Sabrina Mukhtar, BA<sup>3</sup> and David RP. Almeida, MD, PhD, MBA<sup>4</sup>

<sup>1</sup>Department of Ophthalmology, Virginia Commonwealth University, Richmond, VA, USA; <sup>2</sup>Department of Ophthalmology, University of Virginia, Charlottesville, VA, USA; <sup>3</sup>Virginia Commonwealth University School of Medicine, Richmond, VA, USA; <sup>4</sup>Department of Ophthalmology, VitreoRetinal Surgery, PA, Minneapolis, MN, USA

A 47-year-old African-American woman was admitted to the intensive care unit of our community hospital for respiratory failure secondary to severe decompensated heart failure, requiring intubation. In the ensuing days, she developed a methicillin-resistant *Staphylococcus aureus* (MRSA) infection of the cornea, despite no growth of MRSA in multiple blood, sputum, and urine cultures. This unexpected corneal infection complicated her hospital stay, and increased morbidity and disease-related cost. Risk factors, warning signs, and preventative measures for MRSA keratitis secondary to lagophthalmos (inability to completely close one's eyelids) are outlined in this case report. Implementing simple precautions such as taping eyelids shut or using artificial lubrication may reduce patient morbidity and disease-related costs. These recommendations are directed to non-ophthalmic clinicians who provide care to patients in settings where MRSA colonization is widespread.

Keywords: *exposure keratitis; MRSA; nosocomial conjunctivitis; nosocomial keratitis*

\*Correspondence to: Puneet S. Braich, Department of Ophthalmology, Virginia Commonwealth University, 401 N 11th St, Suite 439, Richmond, VA 23298, USA, Email: Puneet.Braich@aya.yale.edu

Received: 4 June 2015; Accepted: 17 August 2015; Published: 19 October 2015

**S***taphylococcus aureus* is the most common cause of hospital-acquired infection and a significant cause of patient morbidity and mortality (1). Over time, infection and colonization by both community-associated methicillin-resistant *S. aureus* (CA-MRSA) and hospital-associated MRSA (HA-MRSA) have increased (2). Differences between susceptibility profiles of CA-MRSA and HA-MRSA are now disappearing as CA-MRSA strains migrate into health care centers and institutional settings (3). A recent small case series found ocular MRSA infections with concomitant MRSA colonization in the nares (4). Unfortunately, published evidence in ocular MRSA infections and colonization remains sparse.

We aim to discuss a case of nosocomial MRSA keratitis in an intubated patient who did not grow MRSA in any blood, urine, or sputum cultures. Furthermore, we propose the mechanism of infection and suggest measures which may have prevented the infection in our patient.

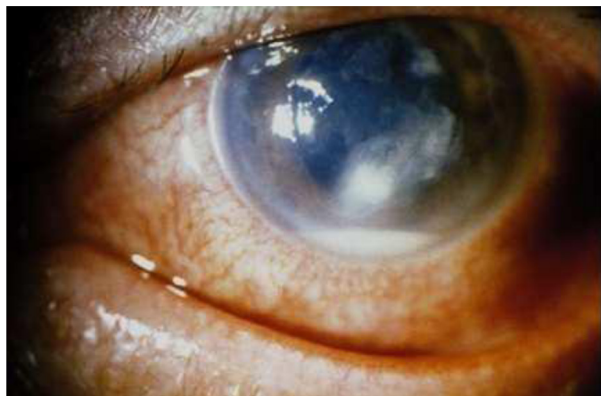
### Case report

A 47-year-old African-American woman with a history of minimal change disease and steroid-induced cardiomyopathy presented to the emergency department with an

acute episode of dyspnea. She progressed to respiratory failure secondary to severe decompensated heart failure. After intubation, she was admitted to the intensive care unit (ICU). On the fifth day in the ICU, she was found to have an edematous left eyelid, chemosis, and a purulent discharge.

On ophthalmic examination, visual acuity was 20/100 in the right eye and light perception in the left eye. The anterior segment exam in the left eye was remarkable for corneal clouding, and a 3-mm inferonasal ulcer and an inferior infiltrate (Fig. 1). A 2-mm hypopyon was measured, raising concern for endophthalmitis. Fluorescein staining confirmed a corneal ulcer. However, a view of the left fundus was not possible on the initial evaluation due to corneal opacification. B-scan ocular ultrasound was unrevealing.

Corneal scrapings, blood, and sputum were sent for microbial culture. The patient was empirically started on parenteral vancomycin, topical moxifloxacin eye drops, and erythromycin ointment. Multiple blood and sputum cultures were negative, so parenteral antibiotics were stopped. However, the ocular cultures grew MRSA, and based on sensitivity testing, the patient was treated with



*Fig. 1.* Slit lamp image of the left eye. Remarkable for corneal clouding, an inferior ulcer and hypopyon. Findings 3 days after aggressive lubrication and fortified topical antibiotics.

fortified gentamycin and vancomycin eye drops. By the third day of treatment, there was clearing of the infiltrate and a decrease in the size of the ulcer.

Visualization of the fundus of the left eye was now possible, the vitreous was quiet, and it was concluded that the bacterial infection was localized to the anterior segment as a keratitis.

Over the course of her 9-day ICU stay, the patient improved and was weaned off intubation. Once she was able to converse, we learned she had a history of congenital ptosis of the left upper eyelid with lagophthalmos and amblyopia. Her vision was poor in the left eye due to her amblyopia but otherwise, she rarely complained of ocular symptoms. Topical antibiotics were tapered and a small course of topical steroids was started. We contacted the patient's primary care physician who urged us to keep the patient admitted at the hospital to complete the ophthalmic therapy because she has been known to be non-compliant for dozens of prior medical therapies. Fearing the complications of further ocular infection (5), and consequences from medical non-compliance (6, 7) (e.g., greater morbidity, cost, and resources), we kept the patient admitted until the frequency of dosing could be cut down from every hour to every 4–5 hours (3 days). On a follow-up visit, visual acuity in the left eye recovered to her baseline of 20/200. Her left corneal ulcer healed well, with only a superficial scar remaining.

## Discussion

Bacterial keratitis is very uncommon in a healthy eye and usually develops when ocular defenses have been compromised. Keen attention needs to be paid to the following four broad risk factors:

1. Contact lens wear
2. Trauma such as accidental injury and surgical injury (refractive surgery or loose sutures)

3. Ocular surface diseases such as dry eye and exposure
4. Systemic immunosuppression

The mechanism of infection in our patient started from exposure keratopathy due to lagophthalmos. The patient may have acquired this infection at the hospital where MRSA is more common and has a commensal relationship with the conjunctiva and nares (8).

Exposure keratitis may be caused by:

1. Neuroparalytic conditions, especially facial nerve palsy
2. Reduced muscle tone, such as coma, Parkinson's, or stroke
3. Mechanical conditions, such as scarring and tight skin
4. Globe protrusion

Staining is typically seen in the inferior third of the cornea with subsequent epithelial breakdown. Secondary infection may supervene at any stage as in our patient. There have been several reports of MRSA keratitis occurring in hospitalized patients who were in comas (9), suffered a CVA (10), or had other neurological impairments allowing improper eyelid closure, resulting in exposure keratitis and infection with HA-MRSA.

Simple precautions, which are not yet the standard of care in all ICUs and operating rooms, may help prevent nosocomial ocular infections. Preventative treatment for exposure keratopathy depends on the reversibility of the exposure. Reversible causes may be treated with artificial tears (non-preservative) during waking hours and with an ointment at night. Alternatively, taping the lid closed at night is a viable option. Lid taping works well for patients undergoing non-ocular surgery and those who are in a coma or deeply sedated on intubation.

Permanent corneal exposure may be treated with tarsorrhaphy or insertion of gold weights in the upper eyelid in cases of facial nerve palsy. MRSA infections are becoming more frequent including ocular manifestations, prompting health care workers to vigilantly monitor their patients for signs of MRSA infections involving the eye (10). Hospitals and nursing homes will face rising rates of morbidity and cost if appropriate means of controlling ocular MRSA are not met. Patients with impaired lid closure may benefit from the preventive measures mentioned above.

These simple and cost-effective techniques, which are already implemented by many large institutions, could benefit patients if incorporated into the standard of care.

## Conflict of interest and funding

The authors declare that there is no conflict of interest regarding the publication of this paper. No financial support has been received for this submission.

**Informed Consent:** The patient gave their express consent via writing to use their images for the purpose of publication. Please find the attached document with this submission.

## References

- Melzer M, Eykyn SJ, Gransden WR, Chinn S. Is methicillin-resistant *Staphylococcus aureus* more virulent than methicillin-susceptible *S. aureus*? A comparative cohort study of British patients with nosocomial infection and bacteremia. *Clin Infect Dis* 2003; 37(11): 1453–60.
- Mody L, McNeil SA, Sun R, Bradley SE, Kauffman CA. Introduction of a waterless alcohol-based hand rub in a long-term-care facility. *Infect Control Hosp Epidemiol* 2003; 24(3): 165–71.
- Asbell PA, Sahm DF, Shaw M, Draghi DC, Brown NP. Increasing prevalence of methicillin resistance in serious ocular infections caused by *Staphylococcus aureus* in the United States: 2000 to 2005. *J Cataract Refract Surg* 2008; 34(5): 814–8.
- Kimura N, Sotozono C, Higashihara H, Inatomi T, Yokoi N, Kinoshita S. Relationship between ocular surface infection or colonization of methicillin-resistant *Staphylococcus aureus* and nasal carriage. *Nippon Ganka Gakkai Zasshi* 2007; 111(7): 504–8.
- Braich PS, Chang JS, Albini TA, Scheffler AC. Irido-lenticular abscess as the initial sign of *Candida albicans* endogenous endophthalmitis. *Ophthalmic Surg Lasers Imaging* 2011; 42: e107–9.
- Braich PS, Almeida DR, Hollands S, Coleman MT. Effects of pictograms in educating 3 distinct low-literacy populations on the use of postoperative cataract medication. *Can J Ophthalmol* 2011; 46(3): 276–81.
- Braich PS, Lal V, Hollands S, Almeida DR. Burden and depression in the caregivers of blind patients in India. *Ophthalmology* 2012; 119(2): 221–6.
- Freidlin J, Acharya N, Lietman TM, Cevallos V, Witcher JP, Margolis TP. Spectrum of eye disease caused by methicillin-resistant *Staphylococcus aureus*. *Am J Ophthalmol* 2007; 144(2): 313–5.
- Brennen C, Muder RR. Conjunctivitis associated with methicillin-resistant *Staphylococcus aureus* in a long-term care facility. *Am J Med* 1990; 88(5N): 14–7.
- Spindel SJ, Strausbaugh LJ, Jacobson C. Infections caused by *Staphylococcus aureus* in a veterans affairs nursing home care unit: A 5-year experience. *Infect Control Hosp Epidemiol* 1995; 16: 217–23.