



VCU

Virginia Commonwealth University
VCU Scholars Compass

Auctus: The Journal of Undergraduate Research and Creative Scholarship

2015

Osseointegration of Wrapped Dental Implants in Rabbits

Alex Whitehead

Virginia Commonwealth University

Follow this and additional works at: <https://scholarscompass.vcu.edu/auctus>



Part of the [Animal Sciences Commons](#), and the [Prosthodontics and Prosthodontology Commons](#)

© The Author(s)

Downloaded from

<https://scholarscompass.vcu.edu/auctus/23>

This STEM is brought to you for free and open access by VCU Scholars Compass. It has been accepted for inclusion in Auctus: The Journal of Undergraduate Research and Creative Scholarship by an authorized administrator of VCU Scholars Compass. For more information, please contact libcompass@vcu.edu.

Osseointegration of Wrapped Dental Implants in Rabbits

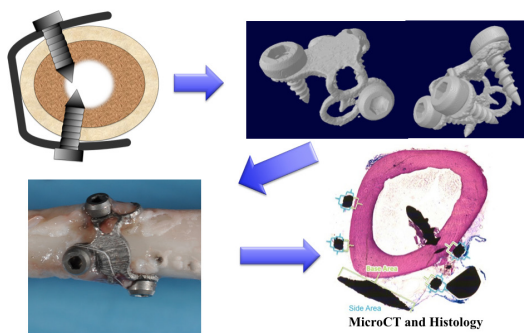
By Alex Whitehead

Introduction

Edentulous patients (those lacking teeth) require one of two approaches to augmentation: inserting a vertical bone graft, or subperiosteally anchoring a device on which an implant can be attached. Bone grafts have had unpredictable results and can undergo resorption over time, compromising implant stability and success. As of the subperiosteal approach, current materials have not proven to directly integrate with the bone, in a process termed osseointegration. Therefore, we used additive manufacturing to create a Ti6Al4V alloy surface with a specific roughness to determine if it would be osseoinductive in a challenging rabbit model over six weeks.

Methods

Additively manufactured titanium alloy wrap implants (Figures 1 and 2) were acid etched and grit blasted and surgically affixed to the left tibia of 30 New Zealand White rabbits under institutional approval at the Medical University of Lodz (Lodz, Poland). Animals were euthanized at two weeks (n=3), three weeks (n=16), or six weeks (n=11) after surgery. Fixed samples were scanned by microCT and bone-implant contact calculated. Samples were then embedded in resin, and ground samples prepared. 28 of the implant samples remained intact and viable after processing and were then stained



with Stevenel's Blue. Samples were photographed using Zen 2012 Blue Edition software with an AxioCam MRc5 camera and Axio Observer Z.1 microscope (Carl Zeiss Microscopy, Oberkochen, Germany). Bone-implant contact (BIC) was calculated by dividing the bone contact perimeter by the total perimeter of the implant. Base and side BICs were also calculated by measuring the bone-facing sides (base) of the implant and outward facing sides of the implant. Statistics were derived using a one-way ANOVA test with a Tukey's post-test for significance and $p < 0.05$ considered significant.

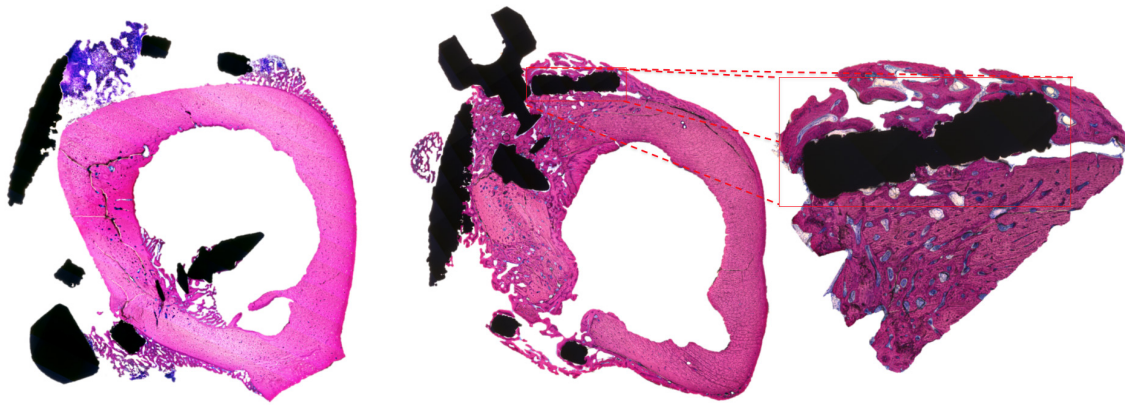


Figure 1. Histological section of an implant 3 weeks after surgery. Figure 2. Histological section of an implant 6 weeks after surgery with close-up view of osseointegrated area in 6 week sample.

Results

Osseointegration of the implants increased on all sides over time. Total BIC increased at each time point examined, and was significantly higher after 6 weeks than the earlier time points, both by microCT and histomorphometric measurements. Base and side BICs increased over time. At 1 week, cartilage can be seen growing toward the implant in areas where direct contact does not exist. After 3 weeks, the chondrocytes mature into a thin layer of bone, spreading from the implant holes. At 6 weeks, the bone establishes significant contact on the outward facing sides of the implant and has achieved good contact with the inward sides.

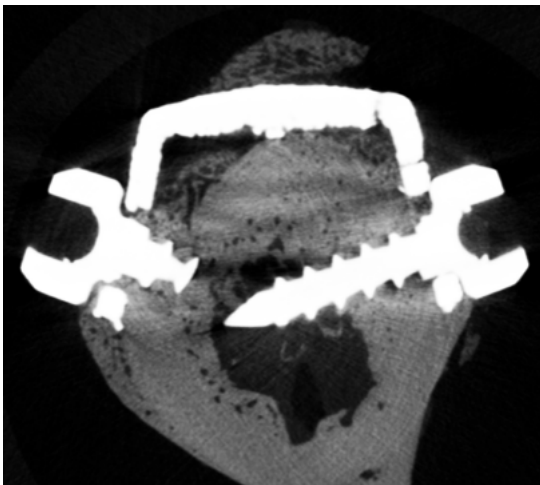


Figure 4. MicroCT scan of implant section harvested after 6 weeks.

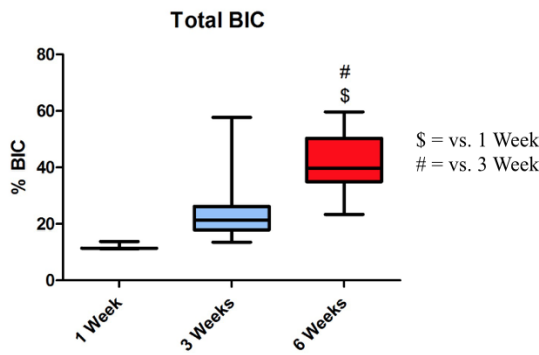


Figure 5. MicroCT morphometric BIC analysis. \$ $p < 0.05$ vs. 1 week; # $p < 0.05$ vs. 3 week.

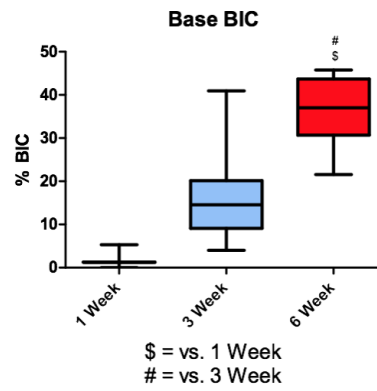


Figure 6. Base BIC measured over time in implants placed in New Zealand white rabbits. \$ $p < 0.05$ vs. 1 week; # $p < 0.05$ vs. 3 week.

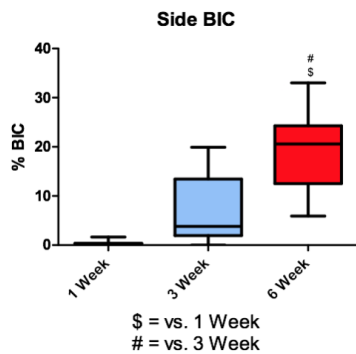


Figure 7. Side BIC measured over time in implants placed in New Zealand white rabbits. \$ $p < 0.05$ vs. 1 week; # $p < 0.05$ vs. 3 week.

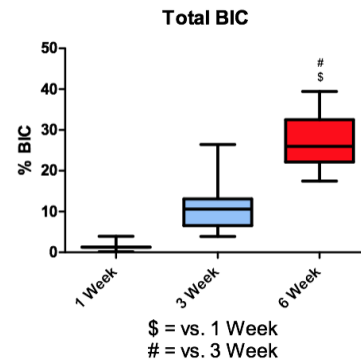


Figure 8. Total BIC measured over time in implants placed in New Zealand white rabbits. \$ $p < 0.05$ vs. 1 week; # $p < 0.05$ vs. 3 week.

Conclusion

Here we demonstrate that using a titanium alloy implant with a specific surface roughness allows for satisfactory osseointegration, as well as the creation of vertical dimension without a bone graft. The use of the titanium wrap allows for osseointegration as early as 6 weeks after placement. These results suggest that this approach may be a novel way to achieve consistent vertical augmentation during implant placement, decreasing healing time and allowing implants to be loaded sooner.

Acknowledgment

Implants were provided by AB Dental (Nir Galim, Israel) and funding was provided by the NIH (Grant AR052101), VCU School of Engineering, VCU Honors College, and VCU BMES.