

Solar Retinopathy Following the Eclipse of March 7, 1970*

WALTER J. GEERAETS, THOMAS W. NOONEY, JOSEPH R. SVOBODA AND FLORENCIO C. CHING

*Department of Ophthalmology,
Medical College of Virginia,
Richmond 23219.*

In spite of extensive warnings by the news media prior to the solar eclipse on March 7, 1970, retinal burn injuries were expected to occur either in children too young to comprehend the dangers involved or in persons ignoring or disbelieving these warnings.

Eclipse burns have been described since ancient times, dating back to the fourth century BC. We read in Plato's *Phaedo* of Rouse's translation "I must be careful not to be affected like people who observe and watch an eclipse of the sun. What happens to them is that some lose their sight, unless they look at his reflection in water or something of that sort." Probably the greatest number of retinal burns from eclipse watching have been reported in the 20th century. Several hundred cases of more or less severe ocular injuries were observed following the eclipse of April 17, 1912; as noted by Wendenburg (1914), Birch-Hirschfeld (1912), Böhm (1913), and others. Central scotomata of various degrees and severity were the usual findings; but, in addition, ring scotomata for colors were described for a series of cases by Jess (1913). The significance of metamorphopsia in patients with solar retinitis was discussed by Verhoeff, Bell, and Walker (1916). Work concerning intensities required for production of retinal lesions during sun watching had already been reported during the 19th and early 20th centuries [Czerny (1867); Deutschmann (1882); Herzog (1903); Verhoeff, Bell, and Walker (1916); and others]. More recent descriptions of solar retinitis have been reported by Rosen (1948), who listed a total of 23 cases.

About 40 per cent of the radiant solar energy reaching the earth is within the visible spectral range, and 55 per cent is in the nonvisible infrared region. Under normal conditions, the bright sunlight causes maximal constriction of the pupil; hence, the light intensity incident on the retina is greatly reduced. Moreover, painful photophobia experienced during direct observation of the sun elicits the blink-reflex (approximately 150 ms), thus providing further protection. The

* This work was supported in part by a Special Fellowship (9 F03 EY20986-03 VSN) from the National Eye Institute of the U. S. Public Health Service, National Institutes of Health.

total amount of light entering the eye during observation of an eclipse is proportional to the percentage of the solar surface not obscured by the moon. However, the energy density per unit area on the retina remains the same; ie, although the image diameter of the sun on the retina is smaller, related to the portion of the sun hidden by the moon, the light remains equally intense over the image area the sun casts on the retina. Since during eclipse watching the pupil may not be constricted to the same degree as in looking at the sun under normal circumstances, the situation becomes even worse. This factor plays a particular role if inadequate filters are used, which, because of their darkness, may decrease the amount of visible light entering the eye and, thus, permit the pupil to dilate. At the same time, however, it would allow more nonvisible infrared radiation to enter the eye, possibly resulting in retinal burn injury.

Case Reports

Case 1

A 14-year-old Caucasian girl was examined for the first time five days after the eclipse on March 7, 1970. She gave a history of having watched the eclipse with her right eye in the Richmond, Virginia area shortly before 1:00 PM, estimating the time of viewing as having been about 15 to 30 seconds. No protective goggles or other filters were used. The patient initially noted a bright glare which after a few seconds became bluish and allowed for good and clear visualization of the eclipse. She discontinued her direct observation to answer a telephone call, at which time she noted that "Everything looked orange," (erythroptosis) when viewed with the right eye. She then continued to watch the progress of the eclipse by using projection techniques. Following the eclipse the vision in her right eye was very hazy, and the next day she noted a dense black spot in the center of fixation. This spot increased somewhat in size over the next few days but had remained about the same for a period of 24 hours preceding consultation.

Ocular findings. On funduscopic examination, a small circular lesion was found, located in the center

of the right macula and covering the entire foveal region. The lesion appeared to be of a light orange color with some scarce pigmentation and a grayish center. The area immediately surrounding the lesion appeared somewhat "wet" and of darker coloration (Fig 1). No other pathology was noted.

Visual acuity. 20/200 OD improving to 20/70 by "scanning" single letters, and 20/20 OS. Normal pupil reaction. Pupillary diameter (daylight): 3.8 mm. Visual field plot using the Amsler Grid charts revealed a central scotoma 2 degrees in diameter with the aid of diagonal lines to maintain fixation (Fig 2). This size reduced to about 1 degree over the next six days. At this time her visual acuity for near at direct steady fixation was 20/200 distance equivalent, but equal to 20/20 in scanning individual digits.

Case 2

A Caucasian male, 30-years-old, was examined seven days after the eclipse on March 7, 1970. The patient stated that he had viewed the eclipse in Powhatan county near Richmond, Virginia intermittently with both eyes unprotected, about one minute at a time as the phenomenon developed. He continued observation to the completion of the eclipse. Estimated total time of viewing was three to five minutes. After total eclipse was reached he attempted to read but "could not make out the words exactly right." When looking at a person wearing a red garment from a distance of about 200 yards, he noticed fading of the red color to grey or even black. There was a sensation of slight film over his eyes.

Ocular findings. OD: Center of the macula showed a diffuse reflex near the nasal margin of the fovea with increased scattered pigmentation around the fovea, giving the small lesion a dark red appearance. All other ocular findings were normal. OS: A small circular lesion (about 1/10 disc diameter) covered the fovea, with some pigmentation, though less intense than in OD.

Visual acuity. 20/30 at distance, and 20/30⁻¹ at near, for both OD and OS which improved to 20/25 over several more days. Pupil reactions were normal and the pupillary diameter (daylight) measured 3 mm in diameter OU. Visual field plots (Amsler Grid charts) indicated presence of dense central scotomata (diameter 1/2 degree) with a bluish outer edge surrounded by a whitish halo extending to 1 degree (Fig 3). Color vision was normal. There was some indication of metamorphopsia.

Case 3

A Caucasian male, 23-years-old, was examined seven days after the recent eclipse of March 7, 1970. The patient stated that he looked steadily at the eclipse with eyes unprotected, for a period of three to four minutes when about "¼ of the sun was left," avért-

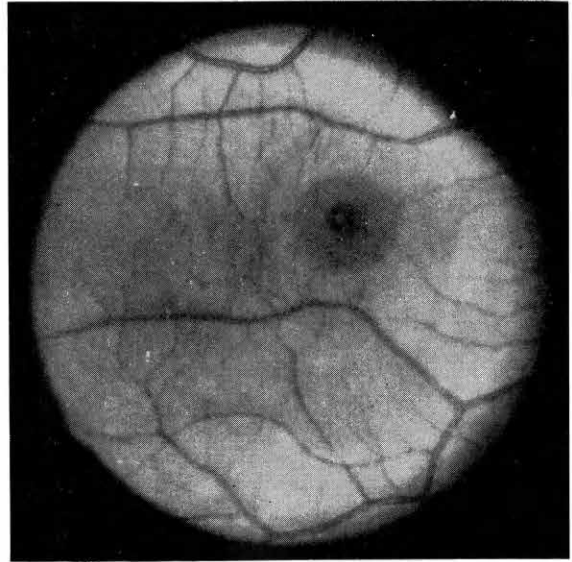


Fig 1—Fundus photograph of macular region of the right eye. Note the small circular lesion in the center of the macula. (Case 1)

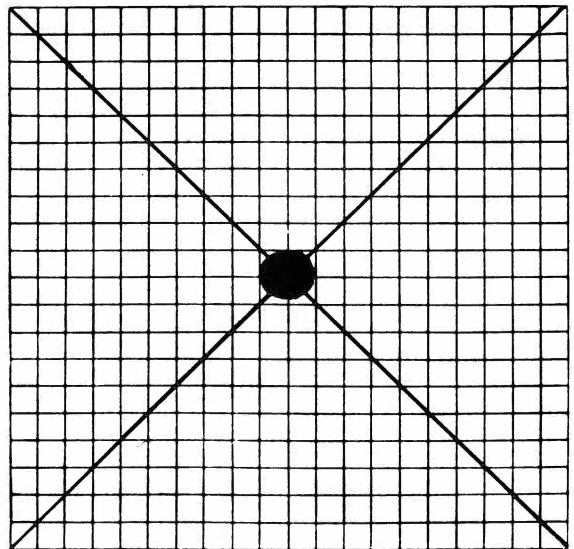


Fig 2—Central positive scotoma as plotted by the patient, measuring approximately 2 degrees on the Amsler Grid chart. (Case 1)

ing his eyes then for awhile. Total viewing time was estimated at five to ten minutes. Beginning about 15 minutes after culmination of the eclipse, until late the same evening, the patient saw everything "red" (erythroptia). When reading he could only see the last few letters of words. The following morning he noted a black spot, about "the size of an orange" when looking toward the sky.

Ocular findings. Ophthalmoscopic examination revealed bilateral parafoveal hyperpigmentation and poor foveal reflex OU. All other ocular findings were normal.

Visual acuity. 20/50 OD for distance and 20/50⁻¹ for near, improving to 20/30 over the next few days. OS was 20/30⁻¹ for distance and 20/30⁻¹ for near. Pupil reactions were normal in both eyes. Pupillary diameter (daylight) measured 2.7 mm at the time of examination. Visual field plots (Amsler Grid charts) indicated presence of a dense black central scotoma (diameter 0.8 degree OD and 0.6 degree OS) with a gray outer ring extending to about 2 degrees (Fig 4). The adjacent black lines of the grid appeared somewhat fuzzy and distorted (metamorphopsia). No defect in color vision was noted.

Discussion

With an assumed irradiance of 71.7 mW/cm² at sea level, the energy density entering the eye with a pupil diameter of 3 mm can be calculated to be 5.1 mW/cm². This value would be 14.1 mW/cm² for a pupil diameter of 5 mm, increasing to 36.2 mW/cm² for a diameter of 7 mm. Based on calculations that 1.3 mW entering the eye will cause a 1C temperature rise in the retina, the corresponding temperature elevations upon viewing the sun for the above given three pupil diameters would be approximately 3.9, 10.7, and 28C respectively (Clarke, Geeraets and Ham, 1969). Expressed in power density on the retina for a given image diameter of the sun on the human retina of 158 μ , these values correspond to 21.8, 59.9, and 156.8 W/cm²; taking into account the ocular spectral characteristics for specific absorption in and reflection from the various structures (Geeraets and Berry, 1968) (Fig 5).

Eccles and Flynn (1944) gave a value above 50 cal/cm²/min for the production of a retinal solar burn in rabbits at an exposure time of 30 seconds, however, they used a telescope to enlarge the sun's image on the retina about ten times. For the given retinal image size of the sun (158 μ in diameter) and an exposure time of 30 seconds, experimental data obtained in our own laboratories indicate that a power density of approximately 40 W/cm² is required for the production of retinal burn injury in the rabbit eye (Clarke, Ham, Geeraets, et al, 1969) (Fig 6). On the basis of these calculations and an estimated exposure time of

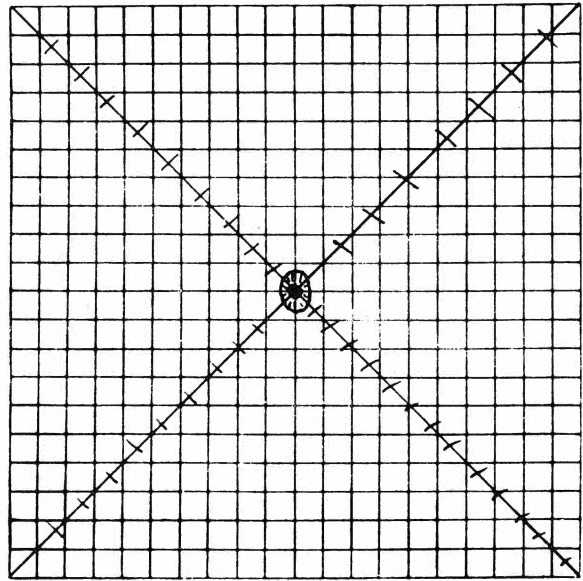


Fig 3—Dense central scotoma approximately 0.5 degree in diameter with bluish outer edge and a whitish halo of about 1 degree. Diagonal lines appeared somewhat blurred, OU. (Case 2)

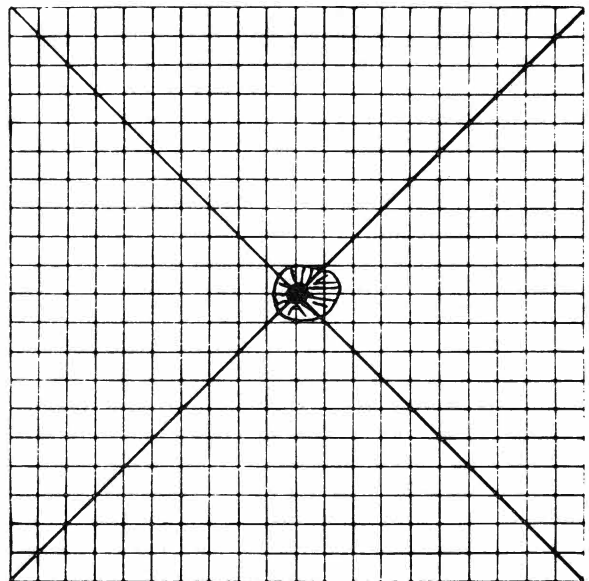


Fig 4—Dense central scotoma approximately 0.6-0.8 degree with greyish halo of about 2 degrees OU. (Case 3)

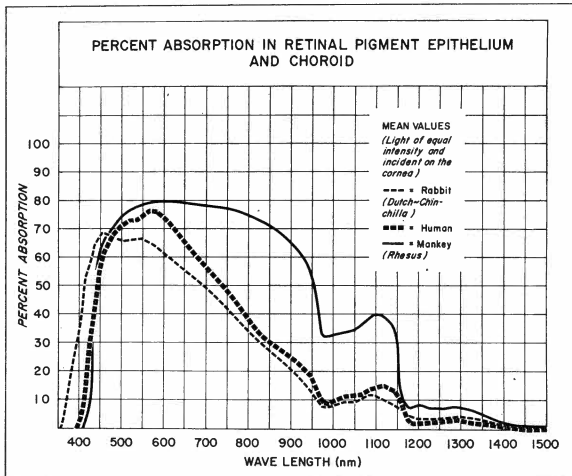


Fig 5—Per cent of spectral absorption in retina and choroid for light incident on the cornea.

30 sec during which the patient (Case 1) may have watched the eclipse with the unprotected eye, the pupil diameter should have been about 4 mm or larger to allow sufficient energy to be incident on the retina to result in a thermal lesion. The degree of ocular fundus pigmentation is, of course, another factor influencing the required energy for production of a retinal burn.

At the time the eclipse was observed by this patient (Case 1), approximately 60 per cent of the sun was still uncovered by the moon. However, as stated in the introduction, the energy density on the retina for the area on which the sun's image impinged remained the same as if the entire sun had been observed. Only the size of the image was smaller, ie, was proportional to the percentage of the unobscured portion of the sun.

The funduscopic examination and fundus photographs indicate that the lesion diameter is approximately 1.5 degrees or 400-450 μ . The larger lesion size in comparison to the calculated image size of the sun on the retina can be due, in part, to heat conduction from the site of exposure into the surrounding tissues, and to unsteady fixation. The central scotoma plotted by the patient (Case 1) at an observation distance of 28 cm on the Amsler Grid chart corresponds to a lesion size of approximately 540 μ in diameter. The difference between the first and second figure can be explained by reactive edema surrounding the lesion which was still present at the time of her first examination. This factor explains, as well, the decrease in visual acuity to 20/70 OD at that time. With subsequent disappearance of the edema and the remaining permanent foveal lesion, one may predict an improve-

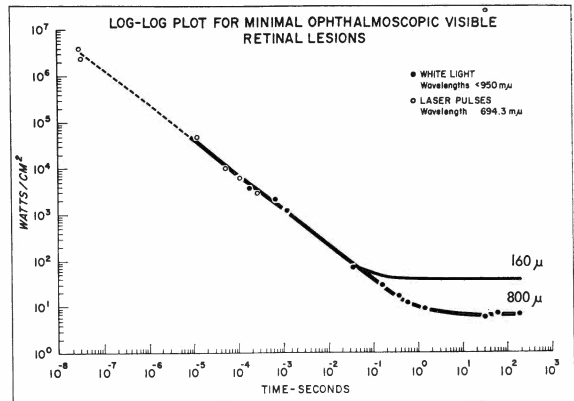


Fig 6—Power density required to produce minimal ophthalmoscopically observable lesions for retinal image diameters of 160 and 800 μ .

ment in visual acuity to 20/40 or better, provided a macular hole with concomitant central retinal detachment does not develop.

The relatively less severe macular lesions of the other two patients can be explained by the factor of pupillary diameter and possible variations in degree of pigmentation of the retina and choroid.

Summary

A case of unilateral retinal burn injury of the fovea and two cases of binocular injuries have been reported, in connection with the viewing of the eclipse of March 7, 1970. Some calculations of energy densities involved have also been presented.

References

- BÖHM H: Blendungsretinitis infolge der Beobachtung der Sonnenfinsternis am 17.4.1912. *Klin Mbl Augenhk*, April 1913
- BIRCH-HIRSCHFELD A: Zum Kapitel der Sonnenblendung des Auges. *Zeitschr f Augenhk* 28, 1912
- CLARKE AM, GEERAETS WJ, HAM WT: An equilibrium thermal model for retinal injury from optical sources. *Applied Optics* 8: 1051, 1969
- CLARKE AM, HAM WT, GEERAETS WJ, WILLIAMS RC, MUELLER HA: Laser effects on the eye. *Arch Environ Health* 18: 424, 1969

CZERNY D: Über Blendung der Netzhaut durch direktes Sonnenlicht. K Akad d Wissensch, Oct. 6, 1867

DEUTSCHMANN W: Über die Blendung der Netzhaut durch direktes Sonnenlicht. Arch f Ophthal 28: 241, 1882

ECCLES JC, FLYNN AJ: Experimental photo-retinitis. Med J Aust 1: 339, 1944

GEERAETS WJ, BERRY ER: Ocular spectral characteristics as related to hazards from lasers and other light sources. Am J Ophth 66: 15, 1968

HERZOG H: Diskussion zum Vortrag Birch-Hirschfeld. Bericht d ophth Ges Heidelberg, 1903, p 1964

JESS L: Die Ringskotome nach Sonnenblendung, Arch f Augenhk 68: 78, 1913

Plato's *Phaedo*: translation by Rouse WMD in *Great Dialogues of Plato*. New York, Mentor Book, The American Library of World Literature, 1956, p 503

ROSEN E: Solar retinitis. Brit J Ophth 32: 23, 1948

VERHOEFF FH, BELL L, WALKER CB: The pathological effects of radiant energy on the eye. Proc Am Acad Arts & Sciences 51: 627, 1916

WENDENBERG K: Schädigungen des Sehorgans durch Blendung bei Sonnenfinsternis Beobachtungen. Berlin, S. Karger, 1914