

Clinical Significance of Exit Block*

IRANY M. DE AZEVEDO, M.D.
YOSHIO WATANABE, M.D.
LEONARD S. DREIFUS, M.D.

*From the Departments of Medicine, Physiology, and Biophysics,
Hahnemann Medical College, Philadelphia, Pennsylvania*

The confinement of an ectopic discharge to its focus, and its consequent inability to invade the adjacent myocardium when falling outside of the refractory period of the heart, is a well established phenomenon called "exit block." This cardiac arrhythmia was originally described by Kaufmann and Rothberger (8) to explain the failure of a parasystolic focus to activate the heart. All pacemakers are subject to exit block (9, 13, 15, 14, 11, 16, 12, 3, 10, 7, 1), however, by convention, conduction disturbances involving the sinus node (S-A block) are usually excluded from this concept, and the term is reserved for ectopic pacemakers. Recent electrophysiological and clinical studies have shown that exit block may complicate reentrant arrhythmias and may be of either Wenckebach type I or II (2, 5). Several examples of exit block will be discussed in an attempt to show some different clinical aspects of this mechanism.

Sinoatrial Block. In figure 1, precordial leads, V1-3 demonstrate a sinus rhythm at a rate of approximately 65 per minute. The P-R interval measures 0.13 seconds, and the QRS complexes are of normal contour and duration. The first P-P interval in V3 measures 0.84 seconds, the second, 1.76 seconds, the third P-P, 0.96 seconds, the fourth, 0.86 seconds, and the fifth P-P interval, 1.84 seconds.

This is an instance of sinoatrial block. The second and fifth P-P intervals are longer than twice the shorter P-P intervals. Such variation of P-P intervals could be explained by Wenckebach conduction from the sinus node to the atria. Sinoatrial block is a true form of exit block, but the term is ordinarily

reserved for ectopic pacemakers, rather than the sinus node.

High Grade Atrioventricular Block. In virtually all instances, exit block occurs in the presence of higher degrees of A-V block. Failure of the impulse to propagate from the subsidiary ectopic focus to either the ventricles, atria, or both is characteristic of this form of exit block. Several examples are illustrated. In figure 2, there is high grade A-V block causing A-V dissociation. The atria are under the control of the sinus node at a rate of 71 per minute, and the ventricles are controlled by a subsidiary ectopic pacemaker, probably originating in the right bundle branch at a rate of approximately 40 per minute. In AVL the two first R-R intervals measure 1.46 seconds after the third QRS complex; a long pause of 2.74 seconds occurs, probably due to exit block from the Purkinje pacemaker, and only atrial activation is seen. In another instance of high-grade A-V block (fig. 3), sinus tachycardia is present at a rate of 105 per minute. There is complete A-V dissociation, and the ventricles are under the control of a sub-junctional pacemaker, probably located in the right bundle branch system, at a rate approximately of 25 per minute. In aVF and V1, the R-R intervals are almost the same with a duration of 2.40 seconds. However, the first R-R interval in V2 is 2.64 seconds and suggests concealed conduction to the level of the subsidiary pacemaker. The second R-R interval in V2 measures 5.72 seconds and is longer than twice the R-R intervals in aVF and V1, probably due to a combination of both exit block and concealed conduction as is shown by the diagram. In figure 4, three records are taken from a patient with an inferior myocardial infarction. A high degree of A-V block is present. The

* Presented by Dr. Dreifus at the Symposium on Cardiac Arrhythmias, June 8, 1972, at Virginia Beach, Virginia.

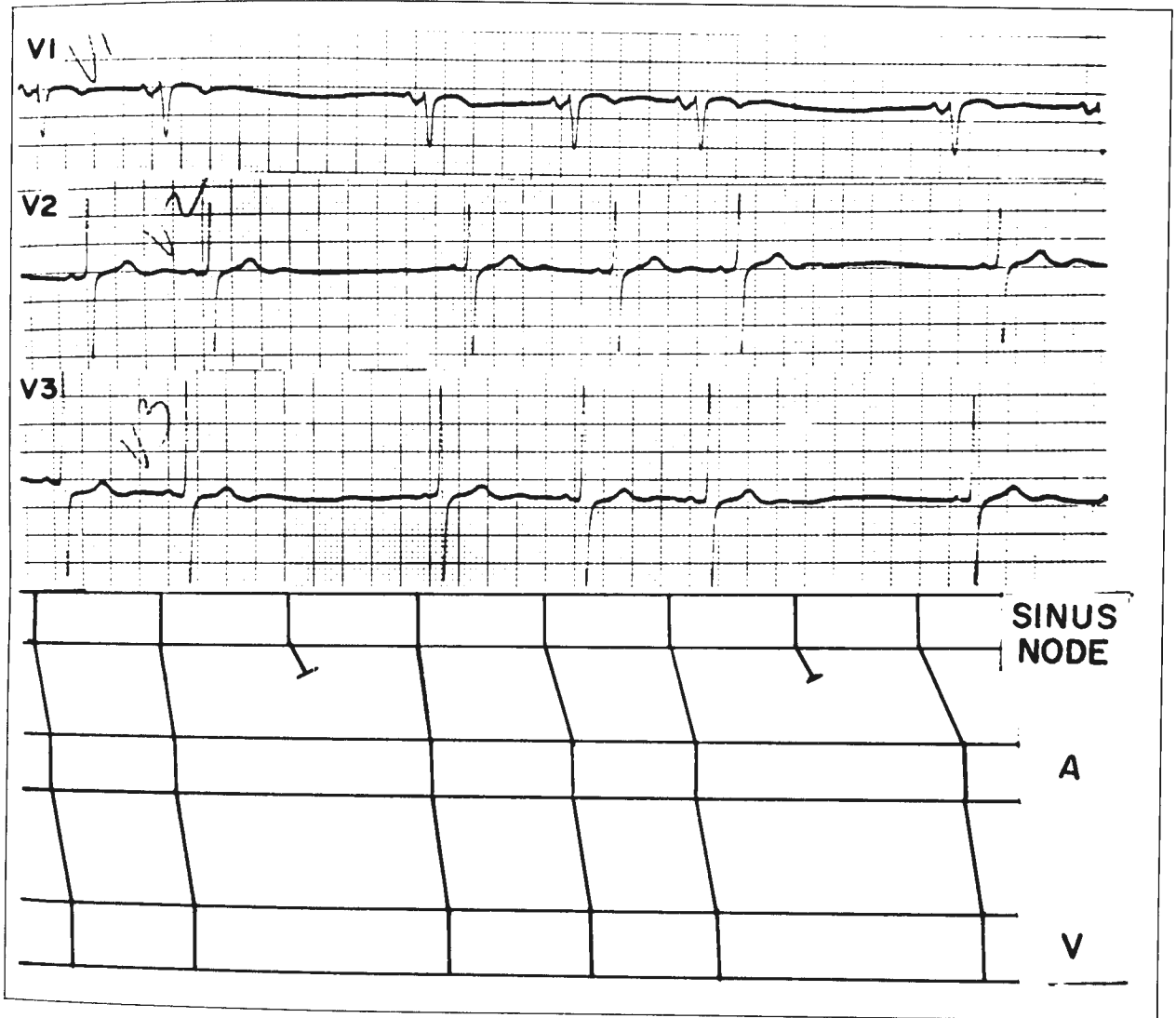


Fig. 1—Sinoatrial block. Three sinus beats are seen followed by a pause. The fourth P wave is not visible as 4:3 block occurs between the sinus node and atria as seen in diagram.

atria are under the control of the sinus node at a rate of 91 per minute, and the ventricles are under a control of a junctional pacemaker at a rate of 66 per minute. In B, longer pauses are observed, but the atrial rate is decreased to 83 per minute, and the ventricular rate is 63 per minute. In C, the atrial rate is 97 per minute, and the ventricular rate is 32 per minute. The R-R intervals measure 1.87 seconds, twice the R-R interval seen in B, probably due to exit block of the junctional pacemaker.

In many instances, high-grade A-V block may be associated with atrial fibrillation. Exit block from

the subsidiary pacemaker can be easily identified if the block occurs with a precise conduction ratio as seen in figure 5. In this example, there is atrial fibrillation, and the ventricles are under the control of a junctional pacemaker at a rate of 64 per minute. In V2, the R-R intervals become more prolonged and measure 1.83 seconds, almost twice that seen in I and II, and are probably due to exit block from the subsidiary junctional pacemaker. Another example of this problem is illustrated in figure 6. Junctional tachycardia is present at a rate of approximately 125 per minute. The atrial activity is

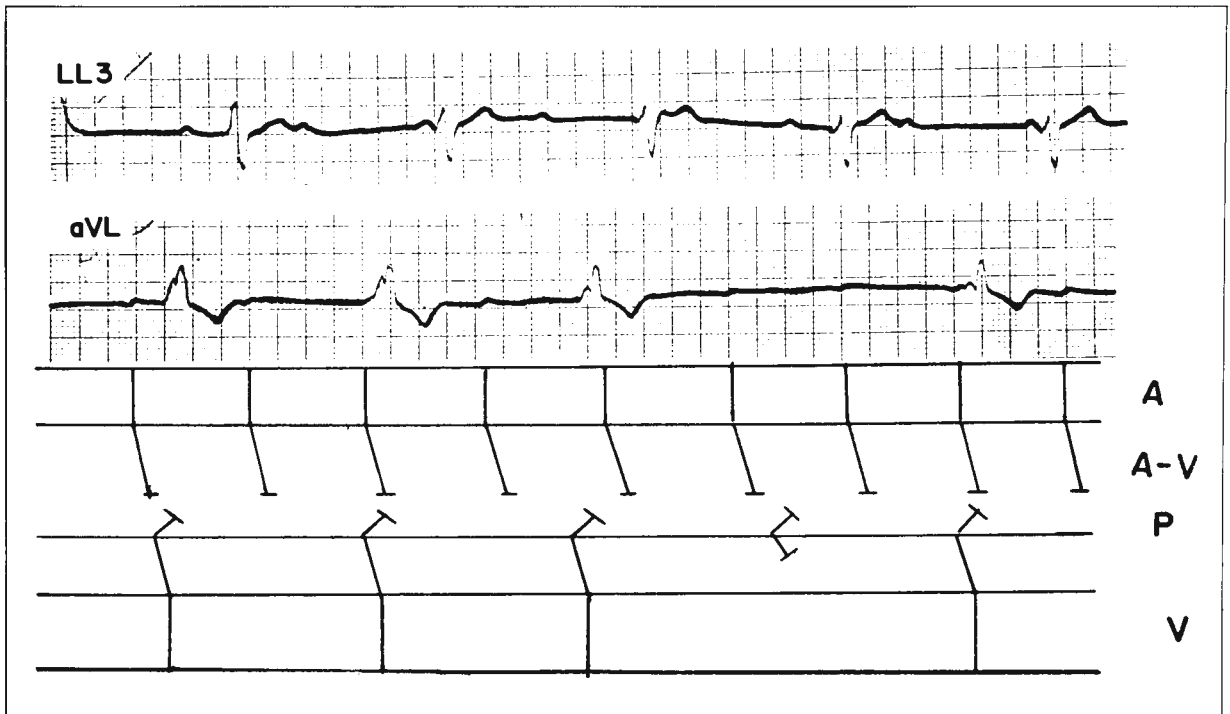


Fig. 2—High-grade A-V block is present. In strip AVL a long pause is seen, indicating exit block from a subsidiary Purkinje pacemaker, probably located in the right bundle branch system.

hardly seen, and atrial fibrillation is present. After the third, ninth, and twelfth QRS complexes, long pauses of 0.86 seconds, sometimes twice the R-R interval of the basic rhythm, are present. These pauses are engendered by exit block from the subsidiary junctional pacemaker. In sharp contrast to these last two examples, an irregular ventricular response in the presence of atrial fibrillation can cause some diagnostic confusion unless Wenckebach conduction from the subsidiary pacemaker is considered. In figure 7, atrial fibrillation is present. The ventricles are under the control of a junctional pacemaker at a rate of approximately 136 per minute. The R-R intervals as seen by the diagram vary slightly. After the seventh QRS complex, right carotid sinus pressure was applied, and the R-R intervals became prolonged from 0.44–0.46 to 0.88 seconds, twice the R-R intervals seen previously. This is due to exit block from a subsidiary junctional pacemaker. At the end of record B, 2:1, 3:2, and 4:3 ratios are seen. This variation of R-R intervals in B is caused by Wenckebach conduction from the subsidiary junctional pacemaker.

Ventricular Parasystole. In figure 8, two differ-

ent types of QRS complexes are seen in the upper record, the first one upright and the other one predominantly downward. There are two independent rhythms, sinus rhythm and ventricular parasystole, as shown in the diagram. The parasystolic pacemaker has a cycle length of 580 per msec, and the variation of R-R intervals during the parasystole is due to Wenckebach phenomenon in the transmission of the impulse from the ectopic parasystolic pacemaker to the ventricles. When exit block of the parasystolic pacemaker occurs with a ratio of 4:3, sinus impulses are transmitted to the ventricles. The coupling intervals show slight variation beats in 2, 6, 10, 14, 18.

Among the clinical examples, figure 1 was presented to demonstrate a similar mechanism between sinoatrial block and exit block. Hence, only the failure of an ectopic pacemaker to activate adjacent myocardium is considered exit block. However, other authors admit that exit block can occur in all excitable tissues of the heart with pacemaker or latent pacemaker properties (2, 6). Thus, if the latter assumption is accepted, it would be very hard to differentiate sinoatrial block from exit block of

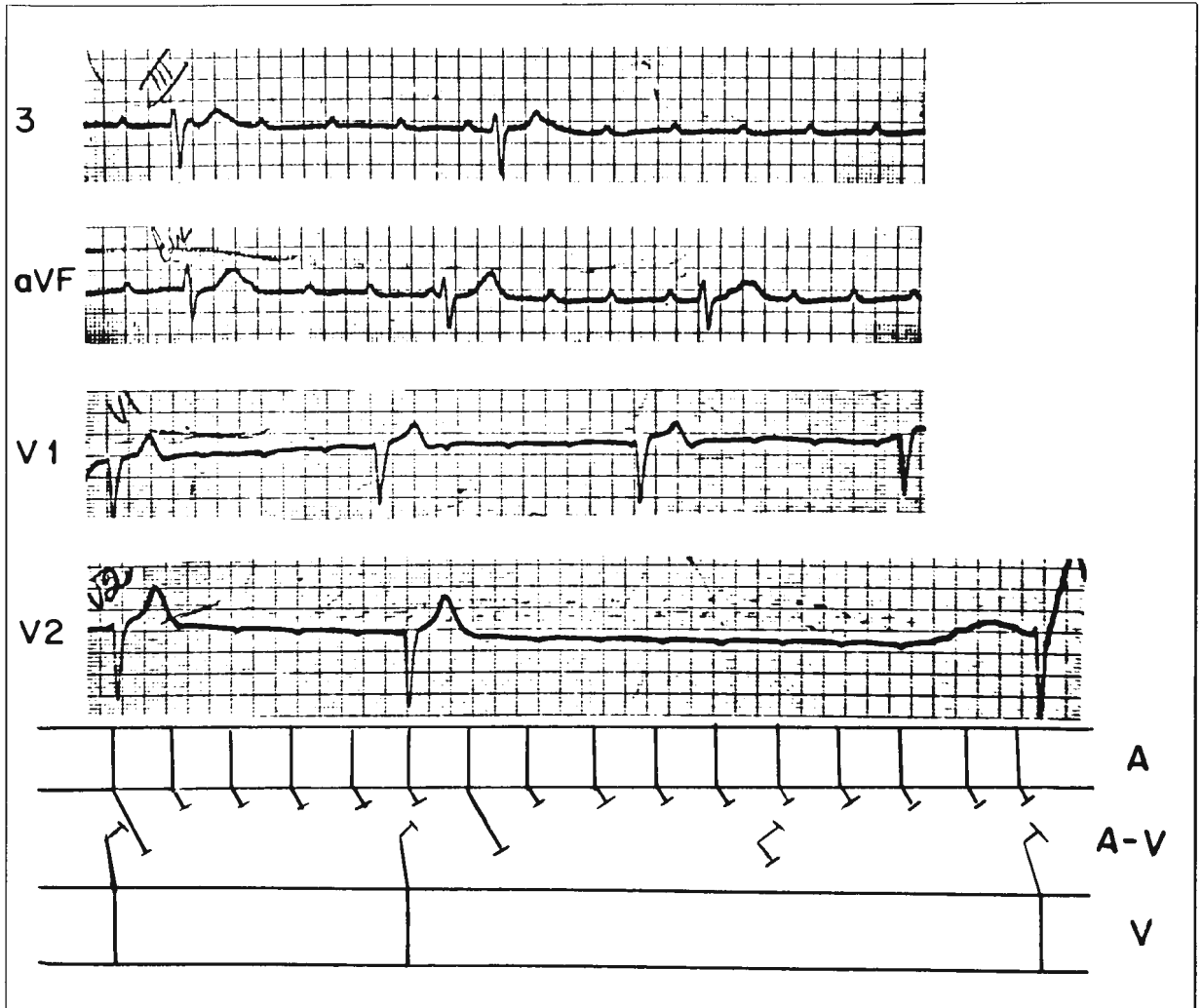


Fig. 3—High-grade A-V block is present and in lead V2, a long diastolic interval is seen which is greater than twice the subsidiary junctional pacemaker rate. Two possibilities may be considered: (1) exit block from the subsidiary pacemaker and (2) concealed penetration into the subsidiary pacemaker by one of the sinus beats, delaying the rhythmicity of the subsidiary pacemaker.

sinus impulse origin. It is true that fibers possessing high degrees of automaticity such as those in the sinoatrial node generally show a lower level of resting membrane potential, a smaller action potential amplitude, and a markedly slower rate of depolarization than other cardiac fibers. These factors engender a slower conduction velocity and may even cause decremental conduction and precipitate exit block (4, 6). In fact, loss of resting membrane potential due to phase 4 depolarization in fibers surrounding the actual pacemaker may produce slow conduction, fractionation of the wave front, decrement, and finally, exit block.

Exit block at a level of the junctional pace-

maker, the Purkinje tissue, and the ventricular parasystolic pacemaker focus were shown above. However, exit block is most commonly observed in junctional rhythms with accelerated impulse formation due to digitalis excess (13, 17).

In figure 3, a combination of concealed conduction and exit block is shown in the ladder diagram. The differentiation between these two rhythm disturbances by electrocardiographic techniques is made by the identification of concealed conduction. Note that the R-R interval is shorter than two basic R-R intervals in the presence of exit block. Since Wenckebach conduction from the junctional pace-

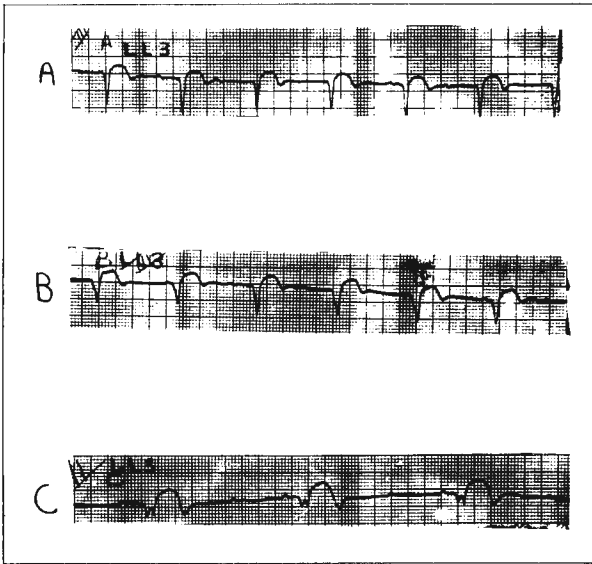


Fig. 4—In A, an inferior wall infarction is present with high-grade A-V block; In B, the subsidiary pacemaker rate is slowed to 60/min; In C, the subsidiary pacemaker rate is now 30, hence, 2:1 exit block from this pacemaker is considered.

maker is not present, the R-R interval is a precise multiple of the basic R-R interval.

In junctional rhythm with exit block, the cause of block is attributed mainly to a small action potential amplitude with a slow rate of depolarization, a mechanism favoring decremental conduction (17). The last tracing shown illustrates exit block from a ventricular parasystolic focus as indicated by the diagram. Wenckebach structure is postulated to account for the progressive shortening of the R-R interval. The increased automaticity in a group of specialized fibers may create an ectopic pacemaker, but at the same time, because the propagation of the impulses through this region becomes more difficult, both entrance and exit block may coexist. However, in this particular case, in which the parasystolic focus is rapid, unidirectional block engendered by rapid discharge of the pacemaker might play a greater role in causing exit block rather than in protecting the parasystolic focus.

It is impossible on the basis of surface electro-

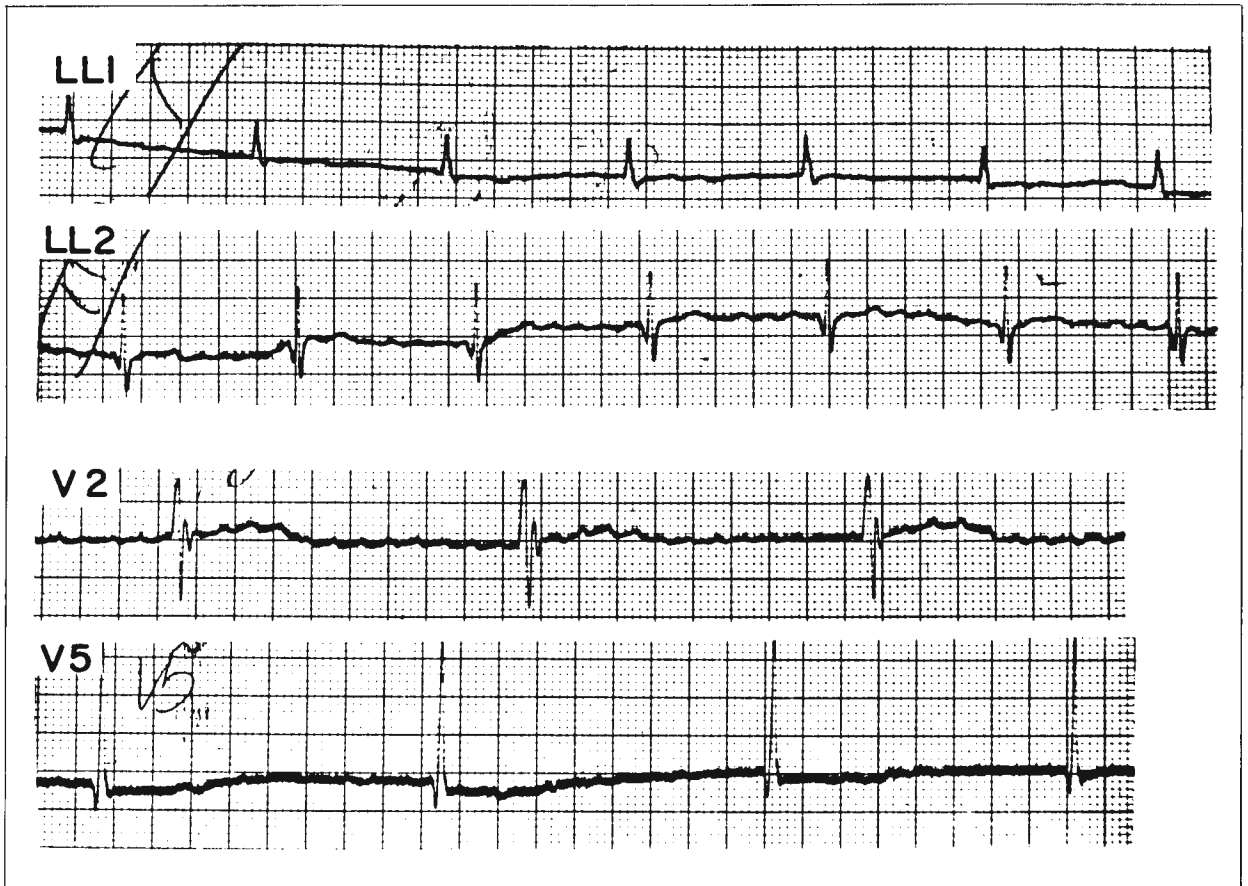


Fig. 5—In the upper two strips, atrial fibrillation is present, although the ventricular rate is quite regular at 60/min. In the lower two strips, the rate is 30/min, hence, exit block from the subsidiary pacemaker is present in the face of atrial fibrillation.

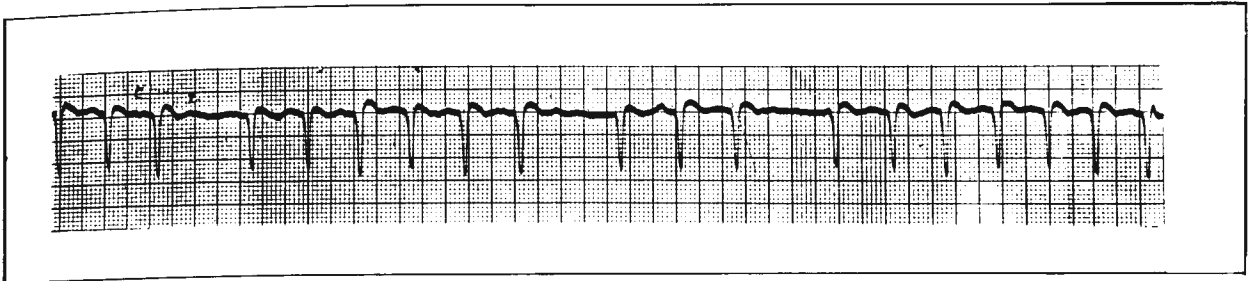


Fig. 6—Atrial fibrillation is present with group beating. The longer diastolic pauses are equal to two of the basic junctional beats. In this instance, atrial fibrillation is present with complete A-V dissociation due to A-V block, with escape of junctional pacemaker and exit block from the junctional pacemaker.

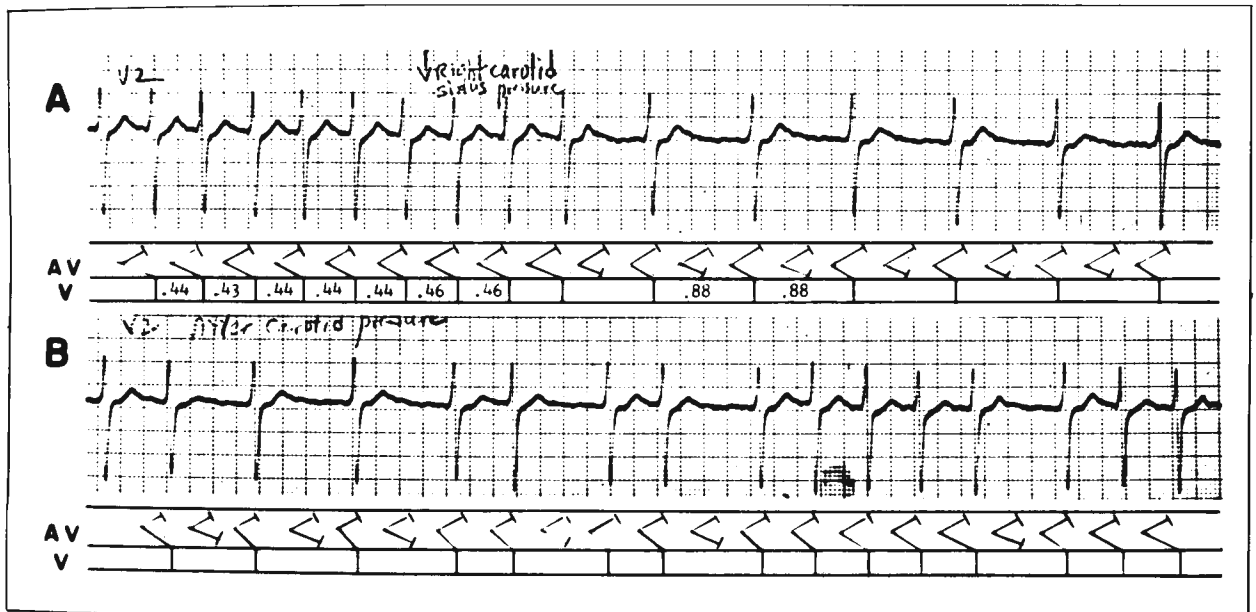


Fig. 7—A. At the left-hand portion of the strip, a rapid regular rhythm is present at 140/min. Following right carotid sinus pressure, the rate in the right portion of the strip is slowed to 75/min, and 2:1 exit block from the subsidiary junctional pacemaker is present. B. Here the rhythm is irregular although group beating is seen, particularly bigeminy. Wenckebach conduction from the subsidiary pacemaker is present.

cardiograms to be certain if the exit block is due to alteration in phase 4 of the pacemaker action potential or to failure of conduction once the impulse leaves the pacemaker cell (5). However, electrophysiological studies and *in vivo* experiments have shown that exit block is a result of conduction depression surrounding the site of impulse formation and can be a feature of both an automatic and reentrant rhythm (2, 4, 17).

Summary. Clinical features of exit block were shown and its probable electrophysiological mechanisms discussed. Based on recent electrophysiological studies, it is emphasized that exit block is a result of depressed conduction surrounding the ectopic pacemaker.

REFERENCES

1. ANDERSON, G. J., GREENSPAN, K., BANDURA, J. P., AND FISCH, C. High-fidelity recording of cardiac depolarization. *J. Appl. Physiol.* 29:401, 1970.
2. DREIFUS, L. S., WATANABE, Y., HAIAT, R., AND KIMBIRIS, D. Atrioventricular block. *Amer. J. Cardiol.* 28:371, 1971.
3. DRESSLER, W., JONAS, S., AND JAVIER, R. Paroxysmal atrial tachycardia with exit block. *Circulation* 34:752, 1966.
4. FISCH, C., GREENSPAN, K., AND ANDERSON, G. J. Exit block. *Amer. J. Cardiol.* 28:402, 1971.

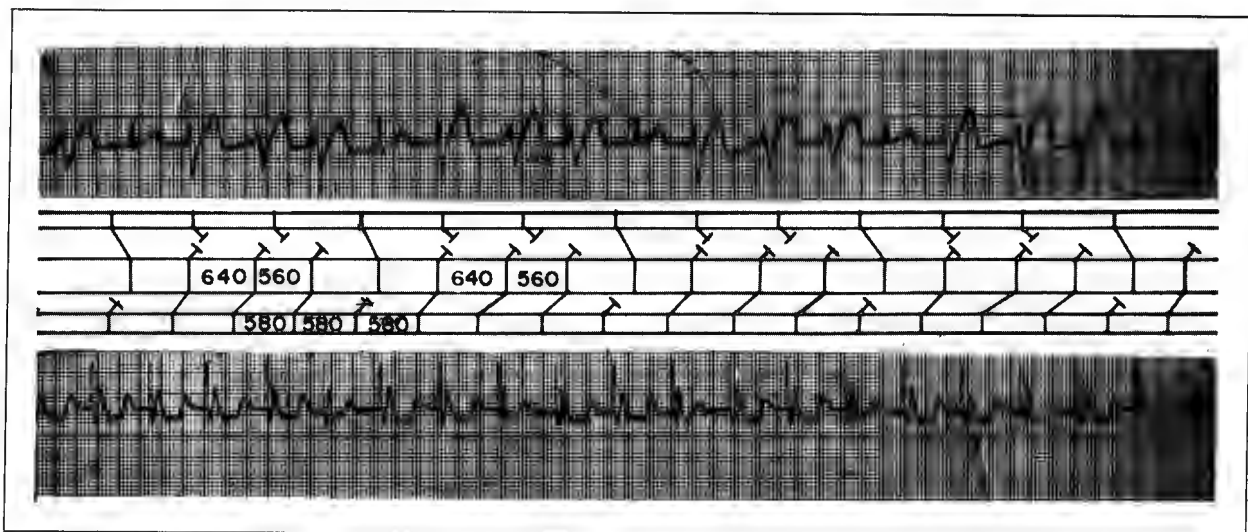


Fig. 8—Basically a sinus rhythm is present. Note narrow QRS complexes which are preceded by P waves (see diagram). However, a rapid ventricular rhythm is seen showing periods of Wenckebach periodicity as the R-R interval of the ectopic beats becomes shorter before the pauses and the reemergence of the sinus rhythm. Hence, exit block from an accelerated, ventricular parasystolic tachycardia is present with exit block showing Wenckebach periodicity.

5. GREENSPAN, K., ANDERSON, G. J., AND FISCH, C. Electrophysiologic correlate of exit block. *Amer. J. Cardiol.* 28:197, 1971.
6. HOFFMAN, B. F. AND CRANFIELD, P. F. *Electrophysiology of the Heart*. New York, McGraw-Hill Book Company, 1960.
7. JAVIER, R. P., NARULA, O. S., AND SAMET, P. Atrial tachysystole (flutter?) with apparent exit block. *Circulation* 40:179, 1969.
8. KAUFMANN, R. AND ROTHBERGER, C. J. Beitrag zur Entstehungsweise extrasystolischer Allorhythmien: Vierte Mitteilung. Über Parasystolie eine besondere Art extrasystolischer Rhythmusstörungen. *Z. Ges. Exp.* 11:40, 1920.
9. LANGENDORF, R. AND PICK, A. Mechanisms of intermittent ventricular bigeminy. Parasystole, and parasystole of reentry with conduction disturbance. *Circulation* 21:431, 1955.
10. MATSUDA, K., KAMYAMA, A., AND HOSHI, T. Configuration of the transmembrane potential of the Purkinje-ventricular fiber junction and its analysis. In: *Electrophysiology and Ultrastructure of the Heart*. (eds.) T. Sano, J. Mizuhira, and K. Matsuda, New York, Grune & Stratton, 1967.
11. PHIBBS, B. Paroxysmal atrial tachycardia with block around the ectopic pacemaker. *Circulation* 28:949, 1963.
12. PICK, A. Electrocardiographic features of exit block. In: *Mechanism and Therapy of Cardiac Arrhythmias*. (eds.) L. S. Dreifus and W. Likoff. New York, Grune & Stratton, 1966.
13. PICK, A. AND DOMINGUEZ, P. Nonparoxysmal A-V nodal tachycardia. *Circulation* 16:1022, 1957.
14. SCHAMROTH, L., RAND, B. C., AND MARROT, H. J. L. Concealed ventricular extrasystoles. *Circulation* 27:1043, 1963.
15. SCHERF, D. AND BORNEMANN, C. Parasystole with a rapid ventricular center. *Amer. Heart J.* 62:320, 1961.
16. SCHERF, D. AND COHEN, J. *The Atrioventricular Node and Selected Cardiac Arrhythmias*. New York, Grune & Stratton, 1964.
17. WATANABE, Y. AND DREIFUS, L. S. New concepts in the genesis of cardiac arrhythmias. *Amer. Heart J.* 76:114, 1968.