

2004

# Overbite Correction and Smile Esthetics

Shannon Michelle Lewis  
*Virginia Commonwealth University*

Follow this and additional works at: <https://scholarscompass.vcu.edu/etd>

Part of the [Orthodontics and Orthodontology Commons](#)

© The Author

---

Downloaded from

<https://scholarscompass.vcu.edu/etd/809>

This Thesis is brought to you for free and open access by the Graduate School at VCU Scholars Compass. It has been accepted for inclusion in Theses and Dissertations by an authorized administrator of VCU Scholars Compass. For more information, please contact [libcompass@vcu.edu](mailto:libcompass@vcu.edu).

School of Dentistry  
Virginia Commonwealth University

This is to certify that the thesis prepared by Shannon M. Lewis entitled **OVERBITE CORRECTION AND SMILE ESTHETICS** has been approved by her committee as satisfactory completion of the thesis or dissertation requirement for the degree of Master of Science.

---

Dr. Steven J. Lindauer, Thesis Director / Program Director Department of Orthodontics

---

Dr. Bhavna Shroff, Committee Member, School of Dentistry

---

Dr. Omar Abubaker, Committee Member, School of Dentistry

---

Dr. Steven J. Lindauer, Chairman Department of Orthodontics, School of Dentistry

---

Dr. Ronald Hunt, Dean- School of Dentistry

---

Dr. F. Douglas Boudinot, Dean of the School of Graduate Studies

June 7, 2004

© Shannon M. Lewis, 2004

All Rights Reserved

OVERBITE CORRECTION AND SMILE ESTHETICS

A thesis submitted in partial fulfillment of the requirements for the degree of Master of Science  
at Virginia Commonwealth University.

by

SHANNON M. LEWIS  
B.S., Texas A&M University, 1999  
D.D.S., University of Oklahoma, 1999

Director: Steven J. Lindauer D.M.D., M.D.Sc.  
Chairman of the Department of Orthodontics and Program Director

## Acknowledgement

Many thanks to Dr. Steven J. Lindauer for providing a place where free thought without fear is dominant at all times. I appreciate the understanding that the faculty and staff showed during a difficult time. I am thankful to have studied in the best learning environment possible. My gratitude is extended to my co-residents for all their help recruiting patients for this study.

Thanks to my husband, Dave, for his support and many years of patience and endurance. All of the years looking at the long-term will pay off, I promise! All of my efforts were doubled in love by my parents and sister, and they are to be credited with years of generosity and encouragement.

## Table of Contents

	Page
Acknowledgements.....	ii
List of Tables .....	iv
List of Figures .....	v
Abstract.....	vi
Chapter	
1 Introduction.....	1
2 Materials and Methods.....	6
Overview .....	6
Subjects and Measurements .....	7
3 Results.....	11
Intra-Examiner Reliability of Clinical Lip to Tooth Measurements .....	11
Clinical and Cephalometric Measurements.....	11
Smile Arc.....	15
4 Discussion.....	22
5 Conclusions.....	25
References.....	26
Vita.....	28

List of Tables

	Page
Table I: Description of Cephalometric Measurements .....	10
Table II: Pretreatment and Post-Overbite Correction Averages. ....	13
Table III: Changes During Overbite Correction .....	14

## List of Figures

	Page
Figure 1: Cephalometric Measurements .....	9
Figure 2: Intrusion Arch Group .....	16
Figure 3: Bite Plate Group .....	19



## Abstract

### OVERBITE CORRECTION AND SMILE ESTHETICS

Shannon M. Lewis, D.D.S.

A thesis submitted in partial fulfillment of the requirements for the degree of Master of Science at Virginia Commonwealth University.

Virginia Commonwealth University, 2004

Major Director: Steven J. Lindauer DMD, M.D. Sc.  
Department of Orthodontics, Chairman and Program Director

Achievement of optimum smile esthetics during orthodontic treatment has recently been the focus of several published articles in the orthodontic literature. Authors speculate that overbite correction, specifically maxillary incisor intrusion, will lead to flattening of the smile arc and consequently reduce smile attractiveness. The purpose of this prospective clinical study was to investigate differences in outcomes from two common treatment modalities used to reduce deep overbite: maxillary incisor intrusion using an intrusion arch and posterior tooth eruption using an anterior bite plate. Pre-treatment and post-overbite correction records were gathered from 20 patients who presented with deep overbite malocclusions to the Virginia Commonwealth University orthodontic clinic. Both the intrusion arch and bite plate treatment modalities effectively reduced overbite significantly over a relatively short period of treatment. Intrusion arch patients displayed significant reductions in maxillary incisor display (lip to

tooth) accompanying documented incisor intrusion. Half of the patients in both groups experienced flattening of the smile arc in agreement with previous studies showing similar changes in orthodontic patients in general. There was no greater tendency for flattening to occur in either group. Changes in the smile arc are likely due to other factors involved in orthodontic tooth alignment and are not necessarily attributable to the overbite correction method employed during treatment.

## CHAPTER 1 Introduction

Recent publications have focused attention on evaluation of the smile as a primary esthetic factor in orthodontic diagnosis.<sup>1-8</sup> This is a significant shift in thinking from decades of evaluating only static soft-tissue relationships for formulating orthodontic treatment goals. Certainly the assessment of dynamic parameters for planning and outcome measures represents a step forward for the specialty. Most work in this field has been focused on defining the characteristics of an attractive smile, enabling practitioners to set goals for individualized treatment. Some, however, have also suggested that certain mechanical processes common to orthodontic practice may be either favorable or detrimental to reaching these goals.

Though Calvin Case advocated facial esthetic evaluation as an important factor in orthodontic diagnosis in the early twentieth century,<sup>9</sup> the non-extraction stance of Edward H. Angle and the advent of cephalometrics led the specialty through an era of focusing on hard tissue goals for orthodontic treatment.<sup>10</sup> The re-emergence of soft tissue esthetic evaluation as a factor in orthodontic treatment planning emphasized relaxed lip posture as an essential element of proper diagnosis. Burstone<sup>11</sup> advocated examining first the relaxed lip and then the closed lip posture primarily for determining proper positioning of the incisors. More dynamic measures, taken during activities such as smiling, were considered difficult to reproduce and therefore unreliable. Though subjective evaluation of the smile was always a part of the orthodontic diagnostic examination, measurements

of relaxed lip to tooth relationships were quantified for the purpose of planning vertical goals of orthodontics and orthognathic surgery.<sup>12</sup>

Peck, Peck, and Kataja's article in 1992 entitled "The gingival smile line,"<sup>1</sup> introduced the concept that smile esthetics could actually be studied scientifically and discussed in the orthodontic literature. Ackerman et al<sup>2</sup> offered the "smile mesh" as a tool for measuring smile esthetics and popularized the term "smile arc" previously described by Hulsey<sup>13</sup> and Frush and Fisher<sup>14</sup> as the "smile line" to describe the relationship between the upper anterior teeth and the contour of the lower lip. Smile arcs were classified as "consonant" if the incisal edges of the maxillary teeth followed the contour of the lower lip, "flat" if they were straight, and "reverse" if they were aligned in an arc opposite to the lower lip line.<sup>2</sup>

Hulsey<sup>13</sup> found that smiles that were judged most attractive had a more harmonious relationship between the upper incisor line and the lower lip contour, displayed symmetry, had an upward curving upper lip, and neither an excessively long nor short upper lip. Width of the buccal corridor displayed was not related to smile attractiveness. Interestingly, orthodontically treated smiles were judged to be less attractive than untreated smiles of subjects with normal occlusion. Hulsey, however, pointed out that he did not compare smiles of the same patients before and after orthodontic treatment.

Mackley<sup>3</sup> compared changes in the smile achieved during orthodontic treatment using four defined criteria: overall attractiveness, maxillary incisor torque, dental protrusion, and profile evaluation. Average scores improved in all four categories as a result of orthodontic treatment. Patients whose smiles improved the most, as evaluated by both parents and orthodontists, on average displayed an increase in maxillary incisor torque and decrease in maxillary incisor show below the upper lip (lip to tooth distance). He concluded that proper vertical positioning of the anterior teeth was necessary to maximize the orthodontist's potential for improving the smile.

Ackerman et al<sup>2</sup> studied changes in the smile arc over time in a group of treated and untreated individuals. They found that only 13% of untreated children had a change in the smile arc over a two and a half year period while 40% of the treated patients showed a change. Of the four untreated individuals with changes, only one had a smile arc that went from consonant to flat while three improved from a reverse contour to either flat or consonant. In the treated group, of the 12 that showed changes, eight had smile arcs that worsened during treatment while only four improved.

In order to better control and improve the smile arc during treatment, several authors have suggested that careful bracket positioning is important.<sup>4,5</sup> A vertical difference of anywhere from 0.5 to 1.5 mm in bracket placement between the maxillary central and lateral incisors has been advocated.<sup>4,5</sup> Careful leveling without intrusion of the maxillary incisors was illustrated by Sarver and Ackerman<sup>4</sup> as being important in one

case to preserve a favorable smile arc. Intrusion of mandibular, rather than maxillary, incisors to control overbite was suggested by Sarver<sup>6</sup> and Zachrisson<sup>5</sup> for preserving smile esthetics. Vertical steepening of the occlusal plane either by growth modification or surgically, has also been advocated by Sarver and Ackerman<sup>4</sup> and Sarver<sup>6</sup> to alter geometrically the relationship of the maxillary anterior curvature relative to the lower lip for improvement of the smile arc.

Authors have speculated on the various mechanical interventions achieved by orthodontists that may cause a patient's smile arc to worsen during treatment. It has been suggested that broadening the maxillary arch may flatten the appearance of the smile arc.<sup>4,7</sup> Sarver<sup>6</sup> stated that "maxillary intrusion arches or maxillary archwires with accentuated curve could result in a flattening of the smile arc." Ackerman and Ackerman<sup>7</sup> said they found that "the segmented-arch technique using cantilever springs offers better control of leveling" and that "leveling with a continuous archwire will intrude the maxillary central and lateral incisors and thus flatten the smile arc." Zachrisson<sup>5</sup> also cautioned against overintrusion of maxillary incisors in patients with low lip lines because it decreased the lip to tooth relationship. He did advocate such intrusion, however, for patients with high lip lines. Despite these recommendations, however, there have been no published studies of the effects of specific orthodontic mechanical interventions on the esthetics of the smile. The purpose of the present study was to examine and compare the effects of two commonly utilized treatment

interventions for correcting excessive overbite, maxillary incisor intrusion and posterior tooth eruption, on two factors involved in smile esthetics: the lip to tooth relationship and the smile arc. The design was a prospective clinical trial in which patients underwent one of the two procedures for correction of deep overbite. Various measures of tooth movement and esthetic changes were made and compared between the two groups.

## CHAPTER 2 Materials and Methods

### Overview

Institutional Review Board (IRB) approval was granted to conduct a study comparing the effects of two treatment interventions to correct deep overbite: maxillary incisor intrusion utilizing an intrusion arch and posterior tooth eruption using an anterior bite plate. Patients presenting to the Virginia Commonwealth University Orthodontic Clinic were asked to participate in the study if they had at least 50% overbite at the start of treatment and were over 10 years of age. Only patients with no active retraction were eligible. Patients with Mandibular Plane to Sella-Nasion angles of greater than 40° were excluded from the study. The treatment method for each patient, intrusion arch or bite plate, was determined by the orthodontic resident and attending to be the best treatment for that particular patient. However, the procedure used was largely dependent on the day of the week the patient chose to be treated because different attending orthodontists tended to implement their own preferred overbite correction method consistently.



## Subjects and Measurements

A total of 40 patients agreed to participate in the study, 25 in the intrusion arch and 15 in the bite plate group. Of those, 20 had data collected at the pre-treatment and post-overbite correction stages for analysis: 10 intrusion arch and 10 bite plate patients. Extraoral photographs (frontal, smile, profile) and intraoral photographs (maxillary occlusal, mandibular occlusal, right and left buccal, and frontal) were taken before overbite correction. After overbite correction, an extraoral frontal and smile photograph were taken. Cephalometric radiographs were taken before and after overbite correction. The cephalometric measurements used in this study are described in Figure 1 and Table I. In addition, a clinically-determined lip to tooth measurement to the nearest 0.5 mm was taken by the same examiner. Patients were asked to swallow and say “N” to ensure relaxed lip position<sup>5</sup> and the measurement was taken twice. The center of the right central incisor was used for consistency. The smile arc assessment (consonant, flat, or reverse) as recommended by Sarver and Ackerman,<sup>8</sup> was made by the same author at both timepoints.

For the intrusion arch patients, the technique employed was either that advocated by Burstone<sup>15</sup> or Isaacson<sup>16</sup> and was used in the maxillary arch only. Bite plate patients received either a removable or fixed maxillary acrylic bite plate that contacted the lower

incisors to prevent posterior occlusal contact. In both groups, aligning archwires in addition to the overbite correction appliance were placed in most patients during the overbite correction phase of treatment.

Pre- and post-overbite correction cephalometric films were superimposed on the anterior cranial base to determine skeletal and dental changes occurring in each patient during treatment. For each patient, a maxillary and mandibular incisor center of resistance was defined as one half of the root length in the alveolar process, on the pre-treatment cephalometric film and carried forward to the post-overbite correction incisor. A template was used to standardize this process. The pre-treatment functional occlusal plane was transferred to the post-overbite correction radiograph to serve as a stable reference plane for describing tooth movements. Anything below the pre-treatment functional occlusal plane was assigned a negative value.

Reproducibility of the clinical lip to tooth measurement was tested by evaluating this parameter in an untreated group of 20 volunteers at timepoints at least one month apart. Cephalometric and clinical lip to tooth changes were evaluated within groups using paired t-tests and between groups using multiple t-tests. Smile arc changes were evaluated using Chi Square analysis. Because of the number of tests employed, the p-value for significance was set at  $p < 0.01$ .

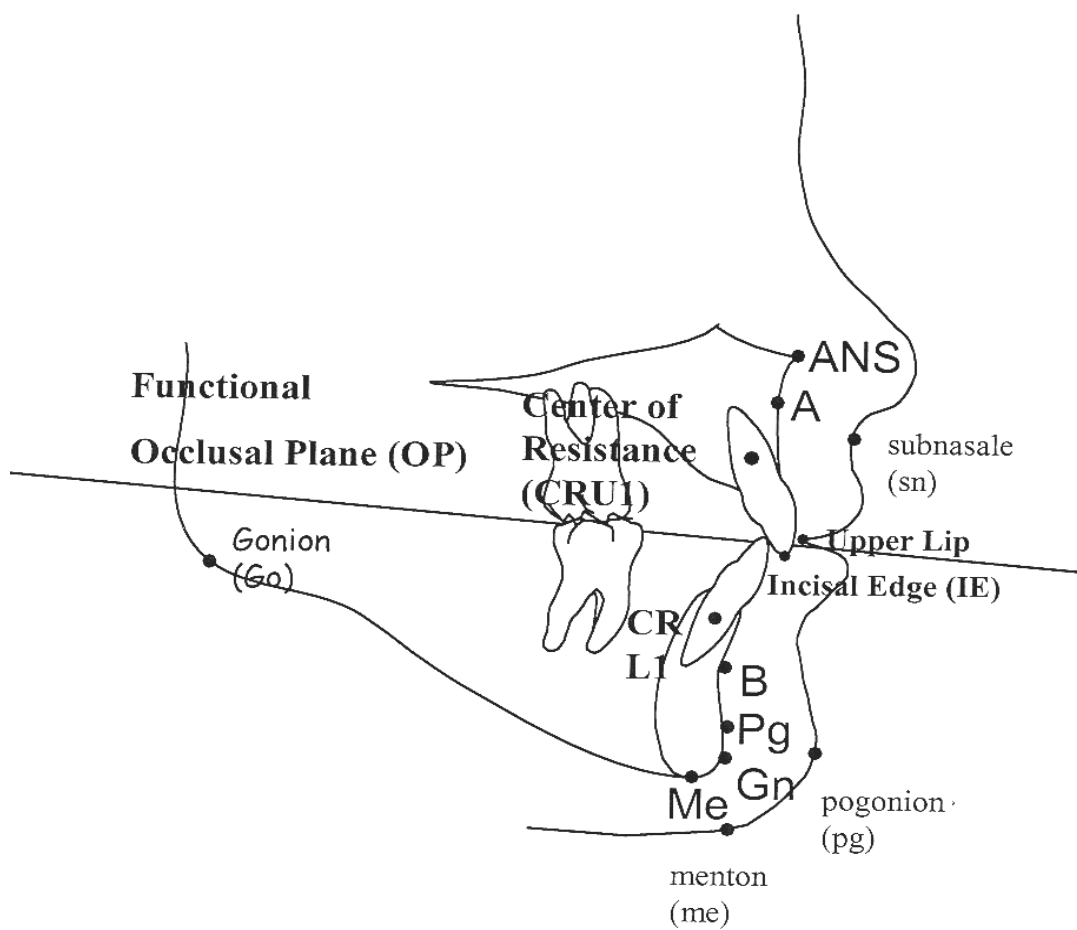


Figure 1. Cephalometric Measurements

Table I. Description of Cephalometric Measurements.

<b>Measure</b>	<b>Definition</b>
OB	Overbite measured perpendicular to the functional occlusal plane.
Lip-Tooth	Vertical distance from the upper incisor incisal edge to Stomion perpendicular to the functional occlusal plane.
OP-U1IE	Vertical distance from the upper incisor incisal edge to the functional occlusal plane.
OP-CRU1	Vertical distance from the upper incisor constructed center of resistance to the functional occlusal plane.
OP-CRL1	Vertical distance from the lower incisor constructed center of resistance to the functional occlusal plane.
SN-U1	Angulation of the upper incisor relative to Sella-Nasion.
MP-L1	Angulation of the lower incisor relative to the Mandibular Plane.
SN-MP	Mandibular Plane angle.

## CHAPTER 3 Results

### Intra-Examiner Reliability for Clinical Lip to Tooth Measurements

Reproducibility of the lip to tooth measurements made clinically on untreated volunteers suggested that these values are reliable to within 0.5-1.0 mm. Lip to tooth measures in the group averaged  $2.9 \pm 1.3$  mm and ranged from 1.0 to 5.0 mm. The second measurement deviated from the first by 1.0 mm in one individual, by 0.5 mm in eight, and was the same in 9 individuals. In one subject, a 2.0 mm difference was recorded. A paired t-test showed no significant differences between the first and second measurements ( $p > 0.20$ ) and correlation between the first and second lip to tooth measurements was high ( $r = 0.90$ ).

### Clinical and Cephalometric Measurements

The overbite correction procedure duration averaged  $4.6 \pm 1.5$  months for the intrusion arch group and  $3.7 \pm 1.2$  months for the bite plate group ( $p > 0.10$ ). Pre-treatment and post-overbite correction averages for the two groups are shown in Table II. There were no significant pre-treatment differences between the groups in any of the clinical or cephalometric characteristics measured.

Significant changes in measurements from the pre-treatment to post-overbite correction timepoints within each group are indicated by (\*) in Table II. Both the intrusion arch and bite plate groups showed significant decreases in overbite with treatment ( $p < 0.0001$  and  $p < 0.001$ , respectively). The lip to tooth distance decreased significantly in the intrusion arch and bite plate groups both as measured clinically ( $p < 0.001$  and  $p < 0.01$ , respectively) and cephalometrically ( $p < 0.0001$  and  $p < 0.01$ , respectively). Both the incisal edge ( $p < 0.001$ ) and center of resistance ( $p < 0.01$ ) of the maxillary central incisor moved apically in the intrusion arch but not in the bite plate group. In the bite plate group, the lower incisor flared ( $p < 0.001$ ) and its center of resistance moved apically ( $p < 0.001$ ). There was a small, but statistically significant increase in the mandibular plane angle in the bite plate group ( $p < 0.01$ ).

Average changes recorded during treatment for each of the two groups are shown and compared in Table III. While both the intrusion arch and bite plate patients had an average decrease in clinically measured lip to tooth distance during treatment, that decrease was significantly greater in the intrusion arch group ( $p < 0.01$ ). Also in both groups, the upper incisal edge and center of resistance moved apically, but the incisal edge changes were significantly more pronounced in the intrusion arch group ( $p < 0.01$ ). The bite plate group had significantly more apical movement of the lower incisor ( $p < 0.01$ ).

Table II. Pretreatment and Post-Overbite Correction Averages.

Measure	Pre-treatment mean ( $\pm$ SD)			Post-overbite correction mean ( $\pm$ SD)		
	Intrusion Arch	Bite Plate	P-value	Intrusion Arch	Bite Plate	P-value
Clinical Lip-Tooth (mm)	5.4 (2.0)	5.5 (1.3)	ns	3.0 (1.4) **	4.6 (1.5) *	ns
OB (mm)	5.0 (1.1)	5.5 (1.6)	ns	2.5 (0.8) ***	2.2 (0.6) **	ns
Ceph Lip-Tooth (mm)	5.0 (2.3)	5.6 (1.1)	ns	2.9 (1.7) ***	4.4 (1.4) *	ns
OP-U1IE (mm)	2.1 (1.7)	2.1 (1.6)	ns	0.5 (1.6) **	1.7 (1.2)	ns
OP-CRU1 (mm)	-13.7 (1.4)	-13.9 (1.6)	ns	-14.5 (1.5) *	-13.6 (1.5)	ns
OP-CRL1 (mm)	13.1 (1.3)	12.4 (1.6)	ns	13.9 (1.8)	14.7 (2.0) **	ns
SN-U1( $^{\circ}$ )	99.6 (9.6)	98.7 (11.3)	ns	105.4 (4.8)	105.3 (6.1)	ns
MP-L1( $^{\circ}$ )	90.8 (5.5)	99.7 (8.6)	ns	94.8 (8.0)	102.0 (7.1) **	ns
SN-MP( $^{\circ}$ )	32.3 (6.5)	28.9 (5.2)	ns	32.8 (5.9)	30.9 (5.2) *	ns

Significant change recorded during treatment (\*P<0.01, \*\*P<0.001, \*\*\*P<0.0001)

Table III. Changes During Overbite Correction.

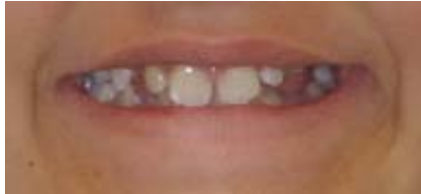Measure	Treatment Change mean ( $\pm$ SD)		
	Intrusion Arch	Bite Plate	P-value
Clinical Lip-Tooth (mm)	-2.4 (1.5)	-0.9 (0.8)	0.01
OB (mm)	-2.5 (1.2)	-3.3 (1.7)	ns
Ceph Lip-Tooth (mm)	-2.2 (0.9)	-1.2 (0.8)	ns
OP-U1IE (mm)	1.7 (0.9)	0.4 (1.0)	0.01
OP-CRU1 (mm)	0.8 (0.8)	0.3 (1.3)	ns
OP-CRL1 (mm)	0.9 (0.9)	2.4 (1.5)	0.01
SN-U1 ( $^{\circ}$ )	5.8 (8.5)	6.6 (7.4)	ns
MP-L1 ( $^{\circ}$ )	4.2 (4.1)	5.2 (3.3)	ns
SN-MP ( $^{\circ}$ )	0.5 (1.1)	2.0 (1.4)	ns



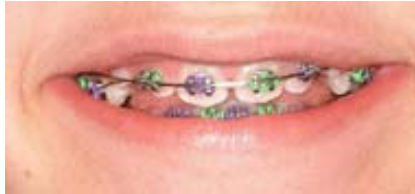### Smile Arc Assessment

Most of the patients in both groups, 9/10 in the intrusion arch and 9/10 in the bite plate group, were judged to have a consonant smile arc before treatment. Also in both groups, 6/10 in the intrusion arch and 5/10 in the bite plate group, the smile arc became flatter with treatment in about half of the patients. In only one patient, in the intrusion arch group, did the smile arc become more consonant during overbite correction. There was no statistically significant difference between the groups related to changes in the smile arc with treatment ( $p>0.20$ ).

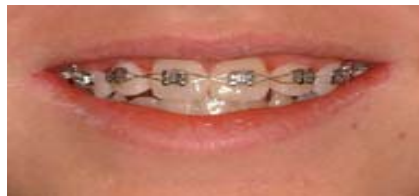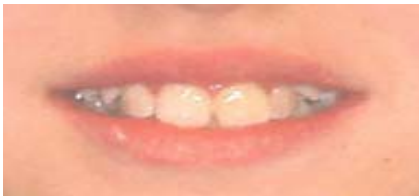Before



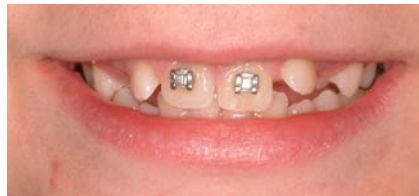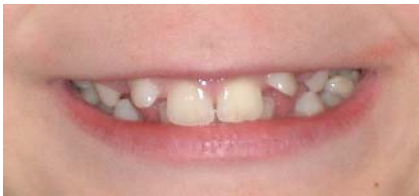After



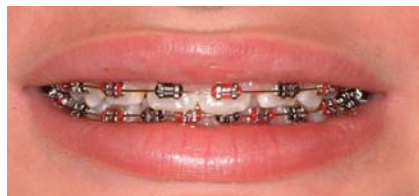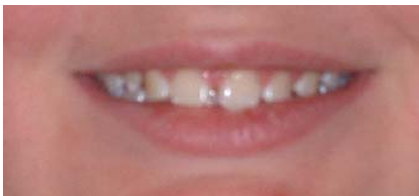C.D.



C.J.L.

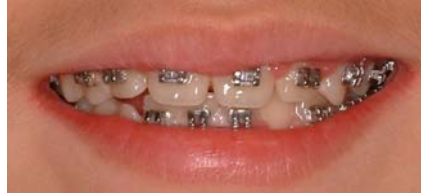
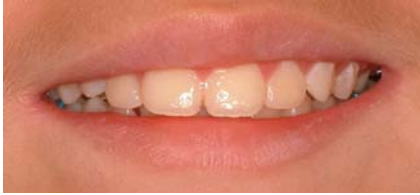
M.A.

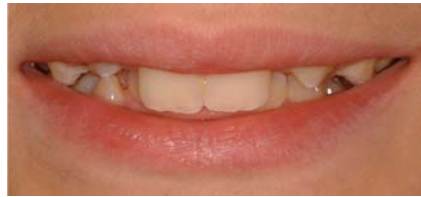
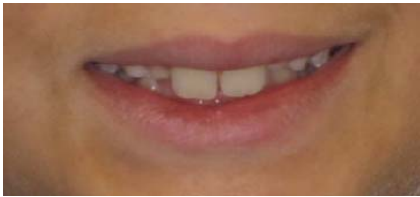
J.B.

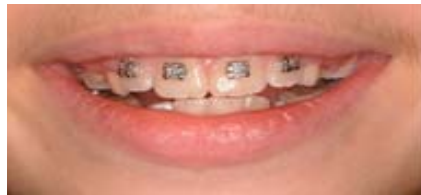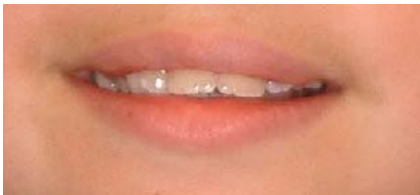Figure 2: Intrusion Arch Group (continued)



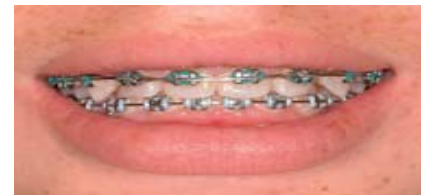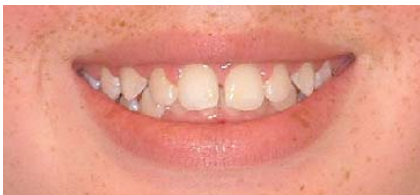B.G.



N.A.K.

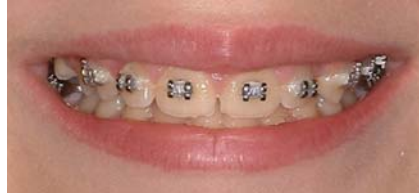
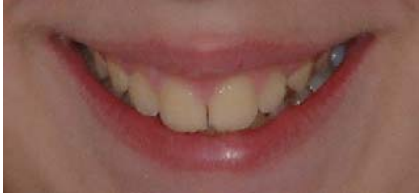
J.M.

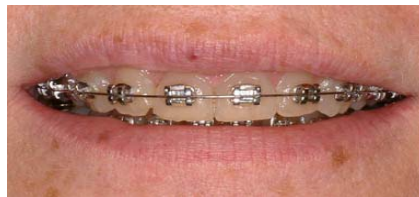
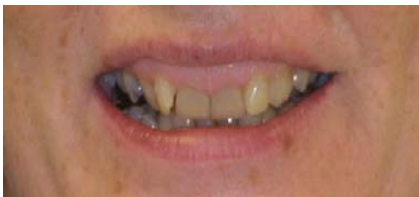
P.O.

Figure 2: Intrusion Arch Group (continued)



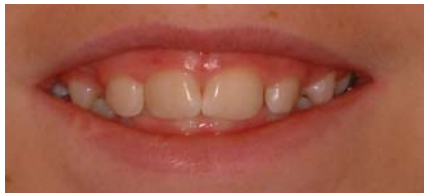S.S.



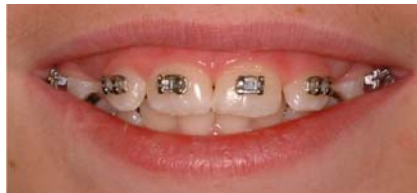D.V.

Figure 2: Intrusion Arch Group

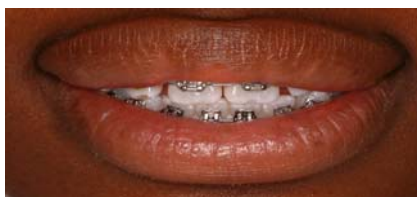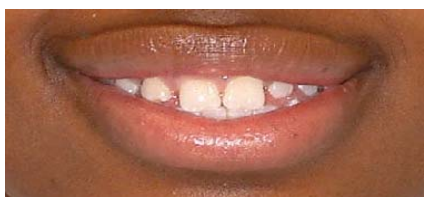Before



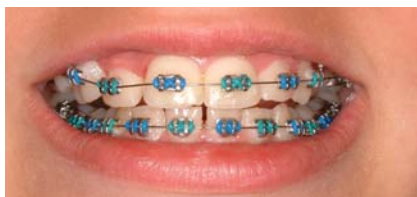
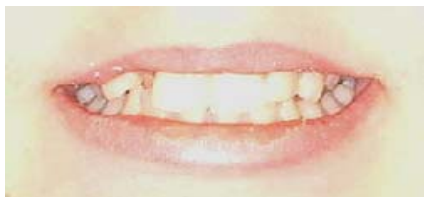After



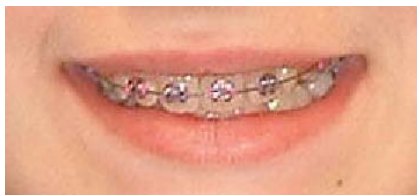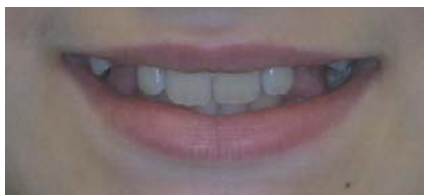D.C.



I.C.

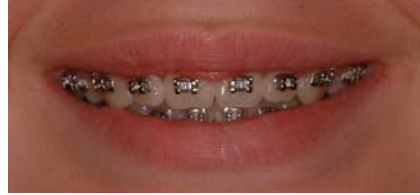
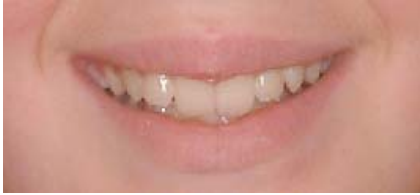
C.W.

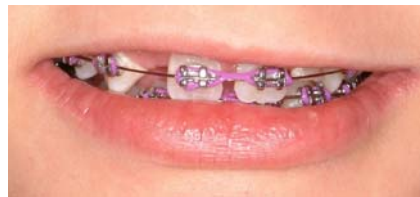
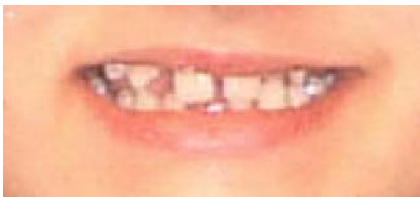
T.J.

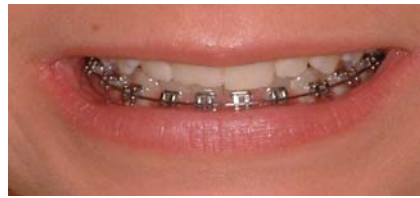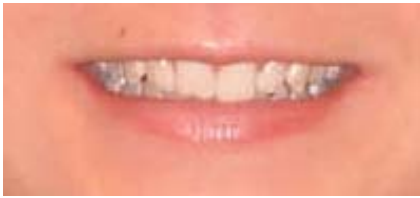Figure 3: Bite Plate Group (continued)



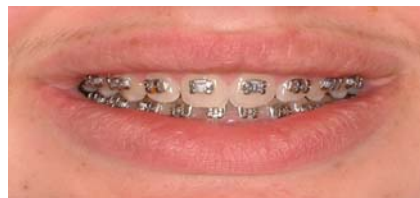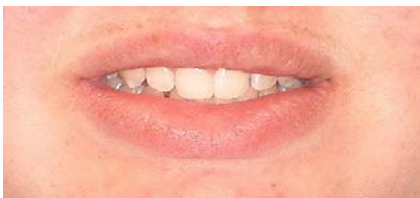L.J.



M.A.

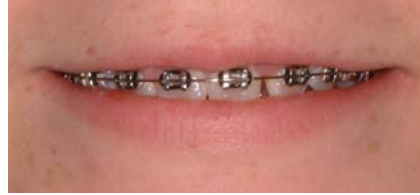
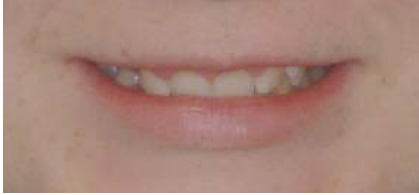
C.W.

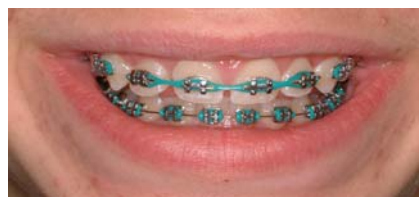
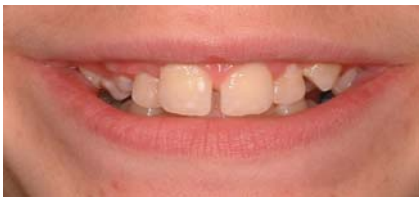
M.M.

Figure 3: Bite Plate Group (continued)



P.S.



B.G.

Figure 3: Bite Plate Group

## CHAPTER 4 Discussion

The results of this study demonstrate that two different mechanisms commonly used to correct deep overbite in orthodontic patients do indeed accomplish this correction in different ways. Both intrusion arches and bite plates were shown to be successful in correcting deep overbite. Maxillary incisors in the intrusion arch group were significantly intruded during treatment and there was a corresponding decrease in the lip to tooth measurement as assessed both clinically and cephalometrically. Though overbite was also effectively reduced in the bite plate group, the data suggest that overbite correction was achieved in these patients by a combination of lower incisor intrusion, some flaring, and a small opening rotation of the mandibular plane secondary to posterior tooth eruption.

A previous study showed that the smiles of orthodontically treated individuals may be somewhat less esthetic than untreated individuals with ideal occlusion.<sup>13</sup> Ackerman et al<sup>2</sup> demonstrated that the smile arc is often flattened during orthodontic treatment and suggested that this may lead to a less esthetic smile overall. Many authors have said that maxillary incisor intrusion can lead to flattening of the smile arc and have recommended other methods of overbite correction to avoid this deleterious outcome.<sup>5-7</sup>



The purpose of the current study was to evaluate the effects of two different methods of overbite correction and compare changes in anterior tooth display and the smile arc. The current study did not subjectively evaluate overall smile esthetics but found that the smile arc did flatten in about half of the patients during treatment regardless of the method of overbite correction employed. It would be misleading to attribute this flattening to the specific process of maxillary incisor intrusion since most patients in the bite plate group also experienced flattening of the smile arc during deep overbite correction even though the vertical position of the maxillary incisors was not significantly altered. It is likely that flattening of the smile arc is a result of bracket placement and orthodontic alignment unrelated to the overbite correction procedure.

According to Mackley,<sup>3</sup> one of the most important factors associated with improvement of the smile was a decrease in maxillary incisor show during orthodontic treatment. This is in contrast to Zachrisson's<sup>5</sup> recommendation to avoid excessively decreasing the lip to tooth distance. Of course, the final determination of vertical anterior tooth positioning goals must be made on an individual basis. If decreasing the lip to tooth distance is an objective of treatment, the results of the current study show that intrusion mechanics is a more effective means of accomplishing a favorable outcome.

As the patients involved in the current study continue to be followed over time, it will be interesting to see how cephalometric measures and clinical parameters, especially lip to tooth and smile arc, change as treatment progresses. For intrusion arch patients

particularly, it is possible that lip to tooth distances will increase as incisors that were intruded apical to the functional occlusal plane erupt back to the level of occlusion with the use of flat archwires during subsequent treatment. Any flattening effect of intrusion mechanics on the smile arc may likewise decrease over time as continuous wires are used to refine alignment of the dentition.

## CHAPTER 5 Conclusions

Both intrusion mechanics and use of an anterior bite plate proved to be effective means of reducing overbite in a sample of patients presenting with deep overbite before treatment. The mechanism of correction was significantly different between the two treatment procedures with the intrusion arch group demonstrating significant maxillary incisor intrusion accompanied by a significantly greater decrease in maxillary anterior tooth display (lip to tooth). Bite plate patients exhibited more lower incisor intrusion, significant flaring of the lower incisors, and a small, but significant increase in the mandibular plane angle. About half of the patients in both the intrusion arch and bite plate groups experienced flattening of the smile arc during the overbite correction phase of treatment. The data from this and previous studies suggest that flattening of the smile arc is a common occurrence during orthodontic treatment and not necessarily related to maxillary incisor intrusion.

### Literature Cited

1. Peck S, Peck L, Kataja M. The gingival smile line. *Angle Orthod* 1992;62:91-100.
2. Ackerman JL, Ackerman MB, Brensinger CM, Landis JR. A morphometric analysis of the posed smile. *Clin Orth Res* 1998;1:2-11.
3. Mackley RJ. An evaluation of smiles before and after orthodontic treatment. *Angle Orthod* 1993;63:183-190.
4. Sarver DM, Ackerman MB. Dynamic smile visualization and quantification: Part 2. Smile analysis and treatment strategies. *Am J Orthod Dentofacial Orthop* 2003;124:116-127.
5. Zachrisson BU. Esthetic factors involved in anterior tooth display and the smile: Vertical dimension. *J Clin Orthod* 1998;32:432-445.
6. Sarver DM. The importance of incisor positioning in the esthetic smile: The smile arc. *Am J Orthod Dentofacial Orthop* 2001;120:98-111.
7. Ackerman MB, Ackerman JL. Smile analysis and design in the digital era. *J Clin Orthod* 2002;36:221-236.
8. Sarver DM, Ackerman MB. Dynamic smile visualization and quantification: Part 1. Evolution of the concept and dynamic records for smile capture. *Am J Orthod Dentofacial Orthop* 2003;124:4-12.

9. Case CS. The question of extraction in orthodontia. *Am J Orthod* 1964;50:660-691.
10. Ackerman MB. The myth of Janus: Orthodontic progress faces orthodontic history. *Am J Orthod Dentofacial Orthop* 2003;123:594-596.
11. Burstone CJ. Lip posture and its significance in treatment planning. *Am J Orthod* 1967;53:262-284.
12. Legan HL, Burstone CJ. Soft tissue cephalometric analysis for orthognathic surgery. *J Oral Surg* 1980;38:744-751.
13. Hulsey CM. An esthetic evaluation of lip-teeth relationships present in the smile. *Am J Orthod* 1970;57:132-144.
14. Frush JP, Fisher RD. The dynesthetic interpretation of the dentogenic concept. *J Prosthet Dent* 1958;8:558-581.
15. Burstone CJ. Deep overbite correction by intrusion. *Am J Orthod* 1977;72:1-22.
16. Isaacson RJ, Lindauer SJ, Rubenstein LK. Moments with the edgewise appliance: Incisor torque control. *Am J Orthod Dentofacial Orthop* 1993;103:428-438.

VITA

Dr. Shannon M. Lewis was born in Corpus Christi, Texas on May 7, 1974. She attended Texas A&M University from 1992-1995, when she then matriculated into dental school. She earned her Doctor of Dental Surgery degree in June 1999 from the University of Oklahoma. She received a Bachelor of Science degree in Biomedical Science from Texas A&M University in August 1999. She subsequently completed a one year General Practice Residency at Northwestern Memorial Hospital and continued there as an attending for one year. She then entered private practice until she started her graduate orthodontic education at Virginia Commonwealth University. She plans to enter private practice in Richmond, Virginia.