



Virginia Commonwealth University  
**VCU Scholars Compass**

---

Theses and Dissertations

Graduate School

---

2014

## Using CBCT as a diagnostic tool for evaluation of infrabony defects in vivo

Anya Rost  
*Virginia Commonwealth University*

Follow this and additional works at: <https://scholarscompass.vcu.edu/etd>



Part of the [Dentistry Commons](#)

© The Author

---

Downloaded from

<https://scholarscompass.vcu.edu/etd/3333>

This Thesis is brought to you for free and open access by the Graduate School at VCU Scholars Compass. It has been accepted for inclusion in Theses and Dissertations by an authorized administrator of VCU Scholars Compass. For more information, please contact [libcompass@vcu.edu](mailto:libcompass@vcu.edu).

Using CBCT as a diagnostic tool for evaluation of infrabony defects *in vivo*

A thesis submitted in partial fulfillment of the requirements for the degree of Master of Science  
in Dentistry at Virginia Commonwealth University.

by

Anya Rost

BS MCPHS, Boston 2006, DMD University of Connecticut 2011

Director: Thomas C. Waldrop, Professor, Director Graduate Periodontics, Department of  
Periodontics

Virginia Commonwealth University  
Richmond, Virginia  
April 14, 2014

## Acknowledgment

The primary author would like to thank her husband for all the support he provided. She would also like to thank her co-author Dr. Jessica Allen and her Research Committee of Dr. Waldrop, Dr. Gunsolley, Dr. Rathore and Dr. Sabatini for providing both insight and oversight with this project.

## Table of Contents

List of Tables.....	iv
List of Figures.....	v
Abstract.....	vi
Chapter	
1. Introduction.....	1
2. Materials and Methods.....	6
3. Results.....	10
4. Discussion.....	13
5. References.....	18

## List of Tables

Table 1: .....	22
Table 2: .....	22
Table 3: .....	23

## List of Figures

Figure 1: Schematic of the measurement locations.....	24
Figure 2: Example of a CBCT - Axial view showing architecture of the defect.....	25
Figure 3: Example of a CBCT - Measurement of the deepest point of the defect.....	25
Figure 4: Example of a CBCT - Measuring distal line angle of the defect.....	26
Figure 5: Example of a CBCT - Measuring buccal line angle of the defect.....	26
Figure 6: Example of a CBCT - Lingual line angle of a defect.....	27

## Abstract

### USING CBCT AS A DIAGNOSTIC TOOL FOR EVALUATION OF INFRABONY DEFECT *IN VIVO*

By Anya Rost, DMD

A thesis submitted in partial fulfillment of the requirements for the degree of Master of Science in Dentistry at Virginia Commonwealth University.

Virginia Commonwealth University 2014

Major Director: Thomas C. Waldrop, Professor, Director Graduate Periodontics, Department of Periodontics

**BACKGROUND:** Clinicians rely on radiographs and clinical exam to assess infrabony defects. However, two-dimensional radiographs have many limitations. Three-dimensional imaging has shown promise and has provided more precise measurements of defects created in skulls. The aim of this study is to compare the diagnostic efficacy of cone beam computed tomography to clinical measurements in patients presenting with infrabony defects.

**METHODS:** The study population included 20 patients with 25 infrabony defects. Clinical measurements of pocket depth (PD), gingival margin (GM), bone sounding (BS) were obtained and PD and BS were compared to CBCT measurements.

**RESULTS:** The average difference between the means of measurements obtained by BS and by CBCT was 1.08mm with BS always being the greater value. BS measurement was statistically significantly different with  $p < 0.05$  from CAL and CBCT values.

CONCLUSION: The CBCT provided measurements that are on average 1.08mm smaller than bone sounding measurements.



## INTRODUCTION

Early diagnosis of periodontal pockets and underlying infrabony defects is important in treating and preventing periodontal disease. In diagnosing infrabony pockets, clinicians have to rely on clinical measurements and two-dimensional radiographs. Clinical measurements usually involve measuring pocket depths and clinical attachment loss. Both of these measurements rely on the use of a periodontal probe. Probing measurements can often be inaccurate due to a variety of operator, armamentarium and patient dependent factors. These factors include probe angulation, force, diameter of the tine, amount of inflammation, anxiety and discomfort during clinical evaluation. Van der Zee has found that probe tine diameter and calibration may have an effect on the measurements.<sup>1</sup> Theil found that probe readings were not a precise measurement of attachment loss, especially in areas of increasing destruction and on multi-rooted teeth<sup>2</sup>. Van der Valden described that with a probing force of 0.75N and a probe with a 0.63mm tip, the tip penetrated into the most coronal intact fibers of the connective tissue.<sup>3</sup> Fowler found that probe tip penetrated 0.45mm into CT in the untreated sites and stopped 0.73 mm coronally to the apical extent of junctional epithelium in the treated sites<sup>4</sup>. In a clinical setting, it is hard to standardize all the variables to arrive at the most correct values for probing and attachment levels, and clinicians are forced to rely on these values to make important treatment decisions.

The most accurate way of measuring bony defects is by direct evaluation during surgery, where the clinician can see both the CEJ and the bone. However, direct evaluation can be an

inaccurate method of determining a treatment methodology. The technique of transgingival probing, or bone sounding, has been identified as an accurate way to establish the location of the alveolar margin and extent of osseous destruction pre-surgically.<sup>5,6</sup> By using this technique, an operator can eliminate some of the inaccuracies, such as effect of the depth of probe penetration and tine and tip diameter on the measurements acquired. Zybutz found that bone sounding is an accurate measure to assess interproximal bone level compared to direct measurement during surgery, with a mean difference being 0.1mm<sup>7</sup>. The drawback of bone sounding is that it has to be done under local anesthesia and cannot be used during routine examinations.

Radiographic evaluation has always been used as an adjunct to clinical exam to diagnose dental and periodontal problems. Most commonly used radiographs are periapical films, bitewings, and panoramic radiographs. These radiographs allow the clinician to assess many variables, such as caries, bone level, crown to root ratio, root proximity, as well as presence and location of infrabony defects. Two-dimensional radiographs were found to routinely underestimate bone loss up to 32% for panoramic, 11-23% for bitewings, and 9-20% for periapicals.<sup>8</sup> Eickholz compared linear measurements of interproximal bone loss on radiographs to surgical measurements and found that bone loss was underestimated on radiographs by an average of 1.43mm.<sup>9</sup> Pepelassi compared using periapical and panoramic radiographs to measure osseous destruction compared to transgingival probing. The author found that periapical radiographs were more accurate in detecting osseous destruction than panoramic radiographs. The extent of inaccuracy of radiographic measurements depended on jaw location, tooth group, and extent of bone destruction. The degree of destruction was underestimated in slight periodontitis, overestimated in severe periodontitis and was relatively accurate in moderate periodontitis.<sup>10</sup>

Another drawback of the standard radiographs is that it is difficult, and frequently impossible, to evaluate the geography of infrabony defects with certainty. In addition, dehiscences and fenestrations are undetectable on two-dimensional radiographs.<sup>11</sup> The most prevalent of the defects is a crater. Craters comprise 35.2% of all maxillary and 62% of all mandibular infrabony defects, but it is impossible to distinguish them radiographically.<sup>12</sup> Vertical defects can present in various configurations. Goldman described one-wall, two-wall, three-wall, and combination defects.<sup>13</sup> While the presence of vertical defects can easily be identified on radiographs, it is impossible to distinguish between two-wall, three-wall and combination defects. However, many of the treatment decisions rely on knowing the architecture of the infrabony defect before treatment is attempted.

Three-dimensional imaging in dentistry has become popular and is commonly utilized for treatment planning of dental implants. This imaging technique can allow the clinician to evaluate the condition of the patient's osseous structures in three dimensions without interferences of overlying structures. Three-dimensional imaging gives the clinician an ability to visualize and measure bone level without structures being superimposed on each other, and has the potential to significantly enhance periodontal diagnosis compared to regular radiographs. It was found to be superior to the periapical radiographs in evaluating artificially created periodontal defects in both large and small periodontal bone lesions, and therefore may have increased use in detecting early periodontal lesions.<sup>14</sup> Another study found that only 60% of infrabony defects could be identified on two-dimensional radiographs and the vertical depth was underestimated by 2.2mm, while in computed tomography scans 100% of the defects were identified and vertical depth was underestimated by 0.2mm.<sup>15</sup>

Previously, medical grade conventional computed tomography (CT) scans were the only ones available; however, cone beam computed tomography (CBCT) scans have become more prevalent. Unlike the medical grade CT machines, the CBCT has a conical radiation source and a digital detector. CBCT offers many advantages over a multislice CT scan, such as reduced patient radiation dose (29-477 $\mu$ Sv for CBCT versus 2000 $\mu$ Sv for CT), decreased exposure time, and decreased cost, and the linear measurements are as accurate on the CBCT as they are on the CT scan.<sup>16</sup> Ludlow found that on the Kodak 9500 unit the effective dose for a large field of view ranged from 93-260  $\mu$ Sv, and a medium field of view ranged from 76-166  $\mu$ Sv.<sup>17</sup> To limit radiation exposure even further, a small field of view (FOV) scan can be taken of the area of interest. The Kodak 9300 Cone Beam CT scanner's small field of view provides doses that range 9.8 to 38.3  $\mu$ Sv, which are considerably lower than those produced by medium and large FOV CBCT units.<sup>18</sup> The range in dosage is due to different intraoral locations requiring a different dose for obtaining the measurement, with anterior maxilla requiring the smallest dose and posterior mandible requiring the highest dose.<sup>19</sup> These doses are within the range used in two-dimensional dental radiography.<sup>17</sup> Small field of view CBCT imaging allows relatively low radiation exposure, but the protocols for CBCT must be optimized to follow the ALARA (As Low as Reasonably Achievable) principle.<sup>20</sup>

Due to limited radiation exposure, ability to take a small focused field, and ability to avoid having distortion independent of the location of the tooth, CBCT has great potential for evaluation of depth and architecture of infrabony defects. This can aid the clinician in diagnosis and treatment planning.<sup>21</sup> Most of the articles published on this topic were done in vitro on skull models with artificial defects.<sup>14, 15, 22-24</sup> Misch evaluated artificially created infrabony defects on two skulls, and found that all infrabony defects were identified with CBCT and with the probe.

Compared to caliper measurements (which are assumed to be the true value), CBCT error was 0.41mm and probe measurement error was 0.34mm. The author found that measurement from CBCT is as accurate as using periodontal probe and superior to PAs in diagnosing buccal and lingual defects.<sup>22</sup> Vanderberghe's skull study found that infrabony craters were detected with 100% certainty and classified with 91% certainty using CBCT while only 71% of cases were identified when looking at two-dimensional radiographs.<sup>24</sup> Mol compared measurements taken on dry skulls with a caliper to measurements made on an FMX and CBCT. It was found that the difference between the direct measurements and the CBCT was 0.23mm and for FMX the difference was 1.23mm, with both underestimating the bone level. It was concluded that CBCT measurements were more accurate than the FMX measurements.<sup>23</sup> While the studies done in skulls may provide an accurate direct measurement of the bone and remove the concern about radiation exposure to the patient, their results cannot always be generalized to live patients.

In difficult treatment planning cases, CBCTs have tremendous potential for making the initial exam more informative and the process of diagnosis and treatment planning more precise. The aim of this study is to evaluate how accurate CBCT is as a tool for evaluation of depth of infrabony defects *in vivo* by comparing measurements taken on CBCT to clinical measurements in a patient who has not yet undergone initial therapy. The specific goal of this study is to compare clinical measurements, and measurements taken on a small field of view CBCT, in order to establish how CBCT agrees with clinical measurements of infrabony defects.

## MATERIALS AND METHODS

### I. Patient Selection

Twenty patients (11 female and 9 male) were selected from the patient population of the Virginia Commonwealth University Graduate Periodontics Department. The study was approved by Virginia Commonwealth University Institutional Review Board. The patients were given a detailed description of the study and signed an informed consent to participate. To be eligible to participate in the study, patients had to have: at least one infrabony defect with interproximal probing  $\geq 6\text{mm}$ , attachment loss  $\geq 4\text{mm}$ , and suspicion of one or more infrabony defects based on the radiographs that were available. The exclusion criteria were: history of excessive radiation exposure, inability to have a CBCT scan, uncontrolled systemic disease, pregnancy, children under eighteen years of age, and presence of large full coverage restorations and restorations located close to the cemento-enamel junction.

### II. Examiner Calibration

For the clinical measurements, two examiners were calibrated by taking measurements on one patient. If there were discrepancies in the measurements that were  $\geq 2\text{mm}$ , the technique was discussed and adjusted and measurements were repeated. The examiners used the same technique for obtaining bone sounding measurements, probing depth, and gingival margin location of all of the study patients. For the CBCT measurements, the examiners discussed the

measurement technique (discussed under the section of Radiographic Interpretation) and measured infrabony defects on a patient. If the measurements were  $\geq 2\text{mm}$  apart, the measurements were repeated and the technique was modified. The same technique was utilized for measuring all of the defects on a CBCT.

## II. Clinical Examination

Either at the initial examination appointment or at the scaling and root planning appointment, measurements were obtained on the teeth of interest by two calibrated examiners using the same UNC periodontal probe. The measurements were: periodontal probing (gingival margin to the base of the pocket), and gingival margin (gingival margin to CEJ). After the patient was anesthetized, bone sounding measurements (gingival margin to bone) were obtained using the same UNC probe. All measurements were obtained by keeping the probe parallel to the long axis of the tooth and “walking it” to determine the deepest measurement. Then the bone sounding from GM to the most apical stop, PD, and GM location would be recorded in that spot. The measurements were obtained in five sites per tooth: direct buccal, buccal line angle, interproximal, lingual line angle, direct lingual for the two teeth between which the infrabony defect was located. The deepest probing in each location was recorded (Figure 1). The two examiners were blinded to each other’s values. If there was an adjacent tooth present, the same sites on the adjacent tooth were measured.

## III. Radiographic Examination

At the same appointment, the patient received a small focused field of view (5x5) CBCT of the quadrant of interest with Kodak 9000 machine (70kV, 10mA and 10.68 seconds). The

CBCTs were not reviewed on the same day to avoid bias. All CBCTs were saved under pre-assigned patient number and reviewed at a later date by the same two calibrated examiners using Carestream Software and the measuring tool provided within the software. The examiners did not have access to clinical measurements while evaluating the CBCTs. Both examiners used the same computer during evaluation. In order to obtain the most accurate measurements possible, the teeth adjacent to the defect of interest were evaluated in an oblique view by lining up the cross section of the plains in the center of the tooth and aligning the sagittal and coronal views with the long axis of the tooth. Location of the CEJ could be identified in the coronal and sagittal plains. Scrolling back and forth in sagittal and coronal planes, the most apical extent of the bone could be identified. Measurements from most apical extent of the bone to CEJ were obtained in the locations that correspond to clinical measurements (direct buccal, buccal line angle, interproximal, lingual line angle, and direct lingual) for both teeth adjacent to the defect. (Figure 1) After the measurements were made and recorded by the first examiner, they were erased as to not influence the second examiner. The anatomy of the defect, such as width and number of walls was visualized in the axial view by starting below the level of the defect and scrolling in a coronal direction.

### III. Statistical Analysis

Spearman's correlation was used to evaluate the relationship between the CBCT values for the five different sites per tooth. Five separate analysis of variance models were used to determine the effect of a number of factors on the five different locations of measurements. The models used the subject as a random effect and used fixed effects for type of measurement (BS, CBCT, CAL). Tukey's test for multiple testing ( $p < 0.05$ ) was used to determine if there were



statistically significant differences between the three types of measurements. In addition, repeatability among examiners was assessed for probing, bone sounding, and pocket depth.

## RESULTS

Twenty five infrabony defects were evaluated in twenty patients. The study population was comprised of eleven females and nine males. Eight of the defects were next to an edentulous space and seventeen of the defects were located between two adjacent teeth. CBCT measurements and clinical values were evaluated. Gingival margin (GM) was recorded as a distance from gingival margin to the CEJ. It was recorded as a negative number if there was recession and as a positive number if the gingiva was above CEJ. Bone sounding (BS) measurement was found by taking the clinical depth obtained from measuring the distance between the free gingival margin to the bone and subtracting the GM. Probing depth (PD) was measured from the free gingival margin position to the most coronal aspect of the attachment apparatus. Clinical attachment level was calculated by subtracting gingival margin from the probing depth measurement. While the main analysis was done between BS and CBCT measurements, PD and CAL were included in the analysis as well.

For the purposes of descriptive statistics and hypothesis testing, direct buccal and direct lingual measurements were averaged to obtain one value for each measurement type and location. Likewise, buccal and lingual line angle measurements were also averaged. Table 1 summarizes mean values obtained from all of the measurements. N represents the total number of measurements. Each was measured on the lingual and the buccal, thus the number of sites (subjects) was half of the above. In all hypothesis testing the subject was the unit of analysis.

The mean defect depth established on CBCT was  $6.93 \pm 2.34$  mm and by BS it was  $8.40 \pm 2.32$ mm. The average difference between the means of measurements obtained by BS and by CBCT was 1.08mm with BS always being the greater value. The mean difference between the BS and CBCT measurements for the buccal and lingual surfaces of the teeth was the smallest: 0.83mm and 0.16mm for the tooth with the defect and the adjacent tooth, respectively. The mean difference between the BS and CBCT measurements for the buccal and lingual line angles was 1.48mm and 0.99mm for the tooth with the defect and the adjacent tooth, respectively. The mean difference for the interproximal measurement was 1.47 for the infrabony defect and 1.54 for the proximal surface of the tooth adjacent to the defect. Incidentally, the value of PD was closer to the CBCT value obtained than was the BS value.

#### Correlation between examiners:

Table 2 summarizes the correlation between examiners. The results show that the two examiners' measurements were within 1mm of each other 92-97% of the time for BS, 80-94% of the time for GM, and 76-94% of time for PD measurements. Bone sounding values has the best agreement of the clinical measurements.

Table 3 summarizes the reproducibility of CBCT measurements between examiners. CBCT values were well-reproducible between the two examiners. There was a Spearman's correlation coefficient of 0.98 for the measurement of the infrabony defect. The lowest reproducibility was for the direct (buccal and lingual) measurement of the tooth adjacent to the tooth with the defect. For those sites the Spearman's correlation was 0.84. For all the other locations, the correlation was: 0.91 for line angles of the adjacent tooth, 0.94 for the direct

surface and line angles of the tooth with the defect. For all the measurement locations except buccal and lingual of the adjacent tooth, the Least Squares Mean calculation showed the BS measurements to be statistically significantly different from CAL or CBCT. For the direct measurement of the adjacent tooth, CBCT and BS were statistically different from the PD measurement with a  $p < 0.05$ .

## DISCUSSION

Diagnosis, prognosis and treatment planning rely on evaluation of bone loss and defect morphology. Clinical examination and two-dimensional radiographs are routinely used for the evaluation. CBCT has many benefits compared to two-dimensional radiographs as it allows three dimensional visualization of bone and tooth morphology, eliminates foreshortening, enlargement or superimposition of structures, and provides visualization of structures on the buccal and lingual aspects of the teeth.

The aim of this study was to assess CBCT as a tool for evaluating depth of infrabony defects by comparing measurements taken on CBCT to clinical measurements. In our study we decided to take the measurements in the patients who have not yet undergone initial therapy, since this is the point at which clinicians are usually planning treatment. The challenge with taking the measurements in patients with inflamed periodontium stems from a multitude of factors that can render the measurements inaccurate, such as patient's discomfort upon probing, presence of subgingival calculus, inflamed periodontium, or inaccuracies in probing angulation.<sup>1, 3, 4</sup> It was hypothesized that CBCT measurements will provide a better assessment of the depth of infrabony defects. In this study we used bone sounding as the gold standard, as previous studies have shown that bone sounding measurements are very close to those obtained intrasurgically.<sup>5-7</sup> The specific goal of this study was to compare clinical measurements and measurements taken on a small field of view CBCT in order to establish how accurate CBCT is

as a tool for evaluation of depth of infrabony defects. Multiple *in vitro* studies have been conducted comparing the infrabony defects in skulls to periapical or panoramic, and CBCT images, all showing CBCT to be the closest to the true depth of the defect.<sup>14, 22, 23, 25</sup> In the skull model studies, the benchmark measurement used is either a direct measurement with a periodontal probe or a caliper. In this study we used bone sounding as the gold standard due to inability to visualize the defect, as most of the patients did not proceed to surgical phase of treatment.

In comparing our results to those done on skull models, there are some discrepancies. The *in vitro* studies showed measurements taken on CBCTs to be very close to their gold standard. Misch et al. found that CBCTs overestimated the depth of the defect by an average on 0.41mm.<sup>22</sup> Mol et al. compared measurements taken with a digital caliper and CBCTs and saw an underestimation of 0.23mm on average.<sup>23</sup> The results of our study were not consistent with those done on skull models. The CBCT measurements were statistically significantly smaller (average of 1.08mm) than BS measurements, and were very similar to PD measurements. The means of PD and CAL measurements were similar to each other due to having some teeth with recession and some with gingival margin above CEJ, which resulted in GM having a small value.

Naito et al. evaluated 186 sites in 9 patients using CT, bone sounding, and intrasurgical measurements. They found the difference between CT and true bone level to be  $0.41 \pm 2.53$  and the difference between bone sounding and true bone level to be  $0.22 \pm 1.49$ .<sup>26</sup> It is important to note that this study was done with a CT, not CBCT, and bone sounding and all the clinical measurements were obtained after initial therapy when inflammation was controlled.

After analyzing results of this study, we cannot rule out that using bone sounding as a benchmark in a patient with inflamed periodontium may not lead to accurate basis for

comparison, as this measurement itself may be flawed. One possible source of inaccuracy is that the BS measurement was not a true measurement, but instead was a calculation. The first measurement was made from the margin of the gingiva to the bone, the second measurement was made from the margin of the gingiva to the CEJ, and then the second measurement was subtracted from the first. Therefore, this final BS value could have measurement error that stems from two sources. We know that measuring gingival margin from CEJ is inaccurate as it is frequently hard to locate the CEJ, especially in the interproximal areas and those with subgingival calculus deposits and inflamed gingiva. We believe that the gold standard used in skull model studies is more accurate due to ability to directly visualize the defect. In our study, we could not visualize the defect or take impressions of the defect and make measurements using a caliper. In this study all measurements were done with a UNC probe using only tactile sense to locate the CEJ when it was subgingival. In addition, frequently visualization was impaired due to bleeding on probing of the inflamed gingival tissues.

As discussed in the introduction, there are many sources of error involved in the clinical periodontal measurements. Another possible reason for the differences in measurements between BS and CBCT could stem from the angulation of the probe when obtaining the BS value. When making intraoral measurements, especially interproximally, one frequently needs to angle the probe. Depending on the angulation, the measurement obtained could be exaggerated. In contrast, when a measurement is done on a CBCT, a straight line is drawn from the CEJ to the deepest point in the bone, and since the defect is frequently directly below the contact, the line drawn from measurement cannot be reproduced clinically.

When bone sounding is performed the probe is pushed until it stops at the most apical extent. We are not ruling out the possibility that the tip of the probe could end up being more

apical to the area from which the CBCT measurement is obtained. The tip of a UNC probe is 0.4mm and could theoretically penetrate into a marrow space or into an enlarged PDL space.

Another reason for the discrepancy between BS and CBCT measurements could stem from clinical measurements always being rounded up when rounding was necessary, i.e. if the line that marks 5mm was even slightly submerged, the measurement recorded was 6mm. In contrast, the CBCT measurements were recorded to one decimal place.

Although measurements obtained on the CBCT did not exactly replicate BS values, the value of CBCT in visualizing the architecture of the defect cannot be understated. The architecture of the defect could be clearly visualized on a CBCT and easily described in regards to the number of walls present and the width of the defect. In contrast, when asked to assess it with clinical measurements only, the examiners did not have the same degree of certainty.

Due to some of the shortcomings of this study that were described above, there is more to be learned about using CBCTs for evaluation of infrabony defects. This was a pilot study with a small number of defects, and there would be a benefit in repeating this study with several modifications, including the use of stents to assure that the same exact location is being measured clinically and on CBCT, enrolling only patients that proceed to the surgical phase so that a measurement could be taken by directly visualizing CEJ and bone level to obtain a better gold standard, including measurements obtained from periapicals and bitewings, and quantifying and recording the architecture of the defect during clinical exam and later comparing it to what is visualized on CBCT.

If the results of the in vitro studies are assumed to be correct and we know that CBCT measurements are within 0.5mm of the true depth of the defect, then it is possible that the BS is overestimating the depth of the defect in a patient with uncontrolled inflammation. If this is true,



then CBCT and not bone sounding should be the basis for comparison, and it may be beneficial to use CBCT as a diagnostic tool for an initial evaluation.

In this study, it was found that when evaluating the infrabony defect and adjacent sites, the measurements obtained on a CBCT were on average 1.08mm lower than BS and were the closest to PD measurement. CBCT appears to have great potential for use in periodontal evaluation and for determining the architecture and depth of infrabony defects. When recommending CBCT for this purpose, clinicians need to remember United States Food and Drug Administration's recommendation for reducing unnecessary radiation exposure from medical and dental imaging, which includes avoiding duplicate exams and adjusting exposure settings to provide the lowest radiation dose for obtaining an image of acceptable quality.<sup>27</sup> At this time, there is inconclusive evidence to recommend routine use of CBCT solely for the purpose of evaluating the depth of infrabony defects. However, if there are other needs for obtaining a CBCT, such as implant treatment planning, CBCT can be used as an adjunct to clinical exam to evaluate the architecture and depth of infrabony defects.

## List of References

## List of References

1. Van der Zee E, Davies EH, Newman HN. Marking width, calibration from tip and tine diameter of periodontal probes. *J Clin Periodontol* 1991;18(7):516-520.
2. Theil EM, Heaney TG. The validity of periodontal probing as a method of measuring loss of attachment. *J Clin Periodontol* 1991;18(9):648-653.
3. van der Velden U, de Vries JH. The influence of probing force on the reproducibility of pocket depth measurements. *J Clin Periodontol* 1980;7(5):414-420.
4. Fowler C, Garrett S, Crigger M, Egelberg J. Histologic probe position in treated and untreated human periodontal tissues. *J Clin Periodontol* 1982;9(5):373-385.
5. Renvert S. Healing after treatment of periodontal intraosseous defects. III. Effect of osseous grafting and citric acid conditioning. *J Clin Periodontol*
6. Greenberg J. Transgingival probing as a potential estimator of alveolar bone level. *The Journal of periodontology*.
7. Zybutz M, Rapoport D, Laurell L, Persson GR. Comparisons of clinical and radiographic measurements of inter-proximal vertical defects before and 1 year after surgical treatments. *J Clin Periodontol* 2000;27(3):179-186.
8. Akesson L, Hakansson J, Rohlin M. Comparison of panoramic and intraoral radiography and pocket probing for the measurement of the marginal bone level. *J Clin Periodontol* 1992;19(5):326-332.
9. Eickholz P, Hausmann E. Accuracy of radiographic assessment of interproximal bone loss in intrabony defects using linear measurements. *Eur J Oral Sci* 2000;108(1):70-73.
10. Pepelassi EA, Diamanti-Kipioti A. Selection of the most accurate method of conventional radiography for the assessment of periodontal osseous destruction. *J Clin Periodontol* 1997;24(8):557-567.
11. Rees TD, Biggs NL, Collings CK. Radiographic interpretation of periodontal osseous lesions. *Oral Surg Oral Med Oral Pathol* 1971;32(1):141-153.

12. Manson JD, Nicholson K. The distribution of bone defects in chronic periodontitis. *J Periodontol* 1974;45(2):88-92.
13. Goldman HM CD. The infrabony pocket: classification and treatment. *J Periodontol* 1958;29(272)
14. Noujeim M, Prihoda T, Langlais R, Nummikoski P. Evaluation of high-resolution cone beam computed tomography in the detection of simulated interradicular bone lesions. *Dento-maxillo-facial radiology* 2009;38(3):156-162.
15. Fuhrmann RA, Bcker A, Diedrich PR. Assessment of alveolar bone loss with high resolution computed tomography. *J Periodont Res* 1995;30(4):258-263.
16. Loubele M, Van Assche N, Carpentier K, et al. Comparative localized linear accuracy of small-field cone-beam CT and multislice CT for alveolar bone measurements. *Oral Surg Oral Med Oral Pathol Oral Radiol Endod* 2008;105(4):512-518.
17. Ludlow JB. A manufacturer's role in reducing the dose of cone beam computed tomography examinations: effect of beam filtration. *Dentomaxillofac Radiol* 2011;40(2):115-122.
18. Lagravere MO, Carey J, Toogood RW, Major PW. Three-dimensional accuracy of measurements made with software on cone-beam computed tomography images. *Am J Orthod Dentofacial Orthop* 2008;134(1):112-116.
19. Ludlow J. Dosimetry of 9000 3D Small FOV CBCT and Panoramic Unit, <br />Univ of N Carolina School of Dentistry, Chapel Hill, NC, 2008. *AAOMR Annual session* 2009;
20. Ludlow JB, Davies-Ludlow LE, White SC. Patient risk related to common dental radiographic examinations: the impact of 2007 International Commission on Radiological Protection recommendations regarding dose calculation. *J Am Dent Assoc* 2008;139(9):1237-1243.
21. Mohan R, Singh A, Gundappa M. Three-dimensional imaging in periodontal diagnosis - Utilization of cone beam computed tomography. *Journal of Indian Society of Periodontology* 2011;15(1):11-17.
22. Misch K, Yi E, Sarment D. Accuracy of cone beam computed tomography for periodontal defect measurements. *J Periodontol* 2006;77(7):1261-1266.
23. Mol A, Balasundaram A. In vitro cone beam computed tomography imaging of periodontal bone. *Dento-maxillo-facial radiology* 2008;37(6):319-324.
24. Vandenberghe B, Jacobs R, Yang J. Diagnostic validity (or acuity) of 2D CCD versus 3D CBCT-images for assessing periodontal breakdown. *Oral surgery, oral medicine, oral pathology, oral radiology and endodontics* 2007;104(3):395-401.

25. Vandenberghe B, Jacobs R, Yang J. Detection of periodontal bone loss using digital intraoral and cone beam computed tomography images: an in vitro assessment of bony and/or infrabony defects. *Dento-maxillo-facial radiology* 2008;37(5):252-260.
26. Naito T, Hosokawa R, Yokota M. Three-dimensional alveolar bone morphology analysis using computed tomography. *J Periodontol* 1998;69(5):584-589.
27. **Dental Cone-beam Computed Tomography** Available at: : <http://www.fda.gov/Radiation-EmittingProducts/RadiationEmittingProductsandProcedures/MedicalImaging/MedicalX-Rays/ucm315011.htm>. 2014.

## Appendix A

**Table 1:** Summary Statistics: N represents number of measurements. Each was measured on the lingual and the buccal, thus the number of sites (subjects) was half of the above. In all hypothesis testing the subject was the unit of analysis.

	B or L of tooth with defect mean			Line Angle of tooth with defect mean		Proximal (defect) mean		Proximal adjacent tooth mean			B or L of adjacent tooth mean		Line angle of the adjacent tooth mean	
Type	N	Mean	Std Dev	Mean	Std Dev	Mean	Std Dev	N	Mean	Std Dev	Mean	Std Dev	Mean	Std Dev
BS	50.00	<b>4.80</b>	2.25	<b>6.59</b>	2.57	<b>8.40</b>	2.32	34	<b>5.44</b>	1.93	<b>4.06</b>	1.73	<b>4.50</b>	1.96
CBCT	50.00	<b>3.97</b>	2.28	<b>5.11</b>	2.12	<b>6.93</b>	2.34	34	<b>3.90</b>	1.89	<b>3.49</b>	1.44	<b>3.51</b>	1.50
GM	50.00	<b>0.23</b>	1.35	<b>0.29</b>	1.61	<b>0.66</b>	1.81	34	<b>0.94</b>	1.63	<b>0.28</b>	1.38	<b>0.65</b>	1.33
PD	50.00	<b>3.66</b>	1.55	<b>5.16</b>	2.46	<b>7.50</b>	2.33	34	<b>5.04</b>	2.07	<b>3.07</b>	0.85	<b>3.59</b>	1.36
CAL	50.00	<b>3.43</b>	1.98	<b>4.87</b>	2.50	<b>6.84</b>	2.05	34	<b>4.10</b>	2.08	<b>2.94</b>	1.66	<b>2.79</b>	1.48

**Table 2:** Percent of time measurements between examiners were within 1mm of each other (T1 – tooth with the infrabony defect, T2 – adjacent tooth)

	Direct T1	Line Angle T1	Proximal (defect)	Proximal T2	Line Angle T2	Direct T2
BS	96%	90%	94%	97%	94%	92%
GM	80%	84%	88%	94%	82%	91%
PD	94%	90%	76%	86%	91%	91%

**Table 3:** Nonparametric: Spearman's  $\rho$  for CBCT measurements (T1=tooth with the infrabony defect, T2= adjacent tooth)

<b>Variable</b>	<b>Spearman <math>\rho</math></b>	<b>Prob&gt; <math>\rho</math> </b>
Direct T1	0.94	<.0001*
Line Angle T1	0.94	<.0001*
Proximal T1 (defect location)	0.98	<.0001*
Line Angle T2	0.91	<.0001*
Direct T2	0.84	<.0001*

## Appendix B

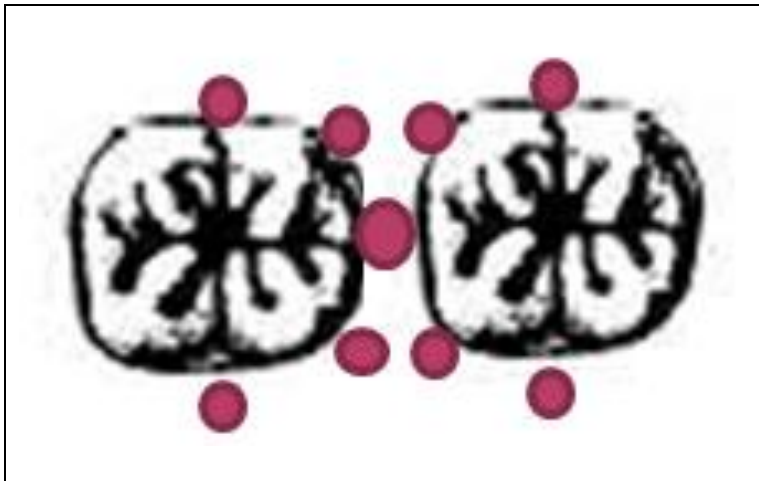


Figure 1: Schematic of the measurement locations



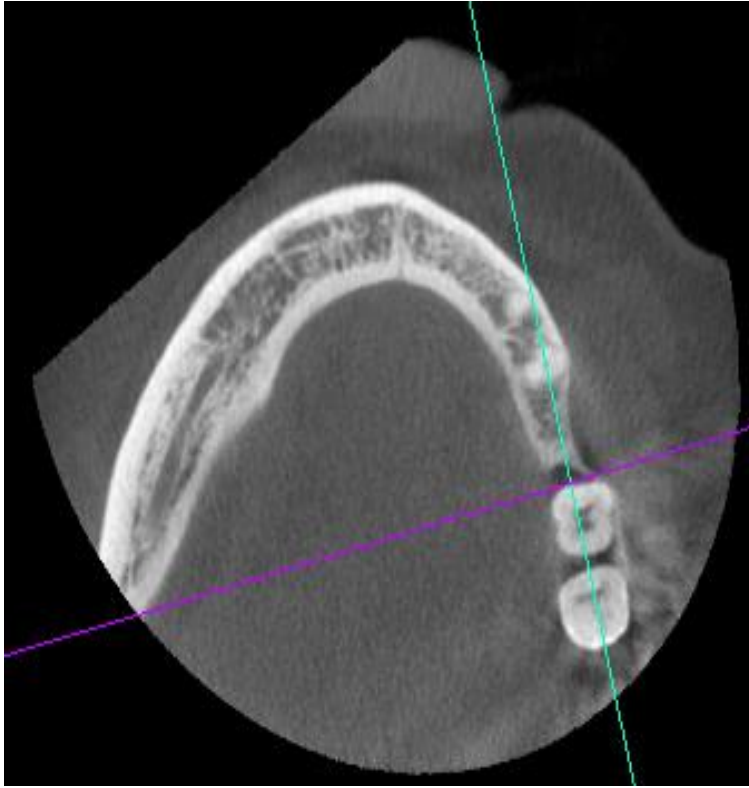


Figure 2: Example of a CBCT - Axial view showing architecture of the defect

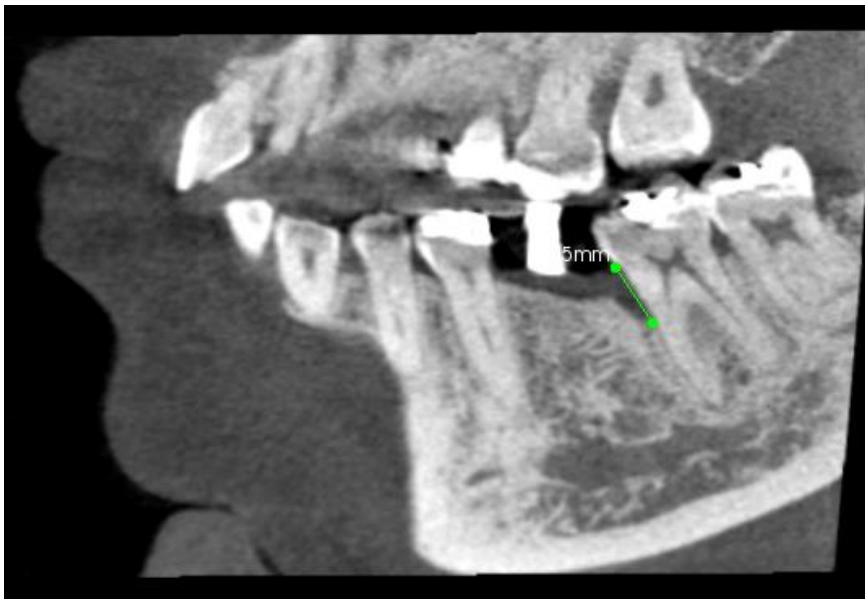


Figure 3: Example of a CBCT - Measurement of the deepest point of the defect

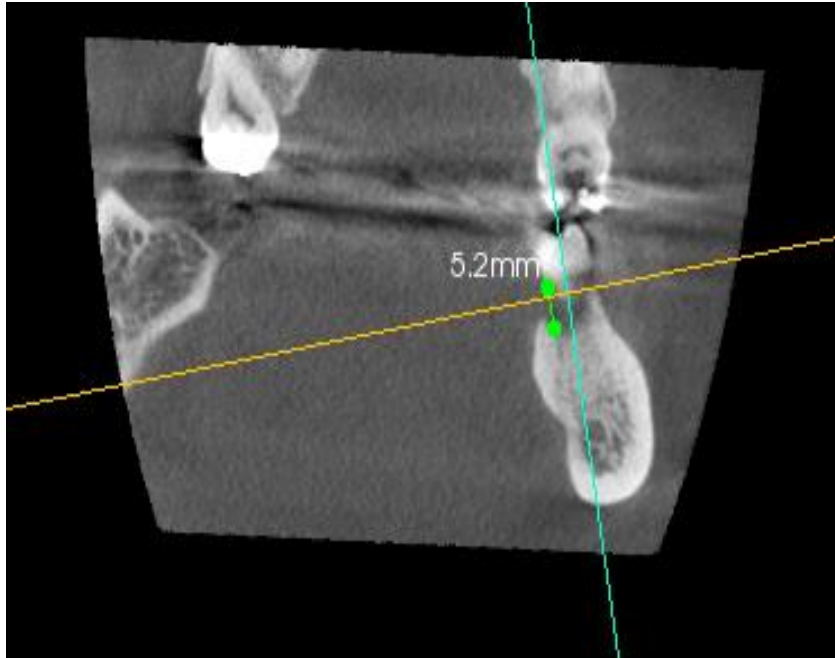


Figure 4: Example of a CBCT - Measuring distal line angle of the defect

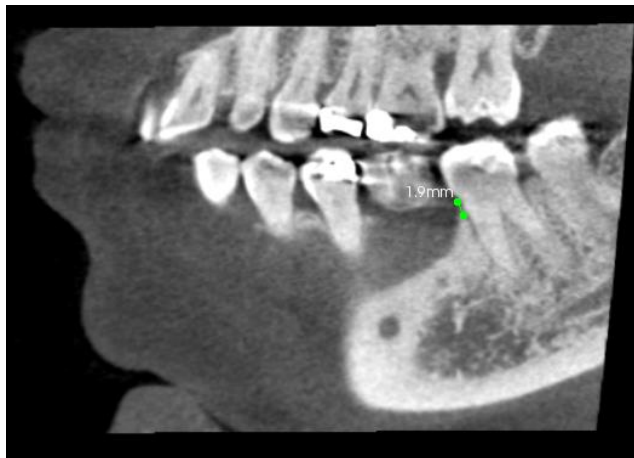

Figure 5: Example of a CBCT - Measuring buccal line angle of the defect

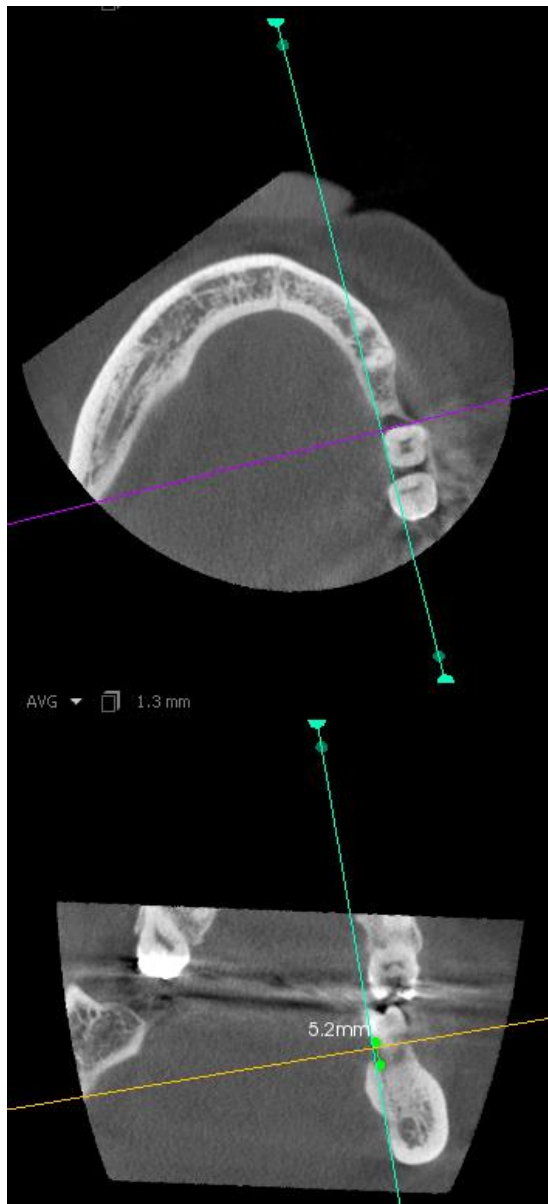


Figure 6: Example of a CBCT - Lingual line angle of a defect